

Fryns syndrome: a variable MCA syndrome with diaphragmatic defects, coarse face, and distal limb hypoplasia

J P FRYNS

From the Centre for Human Genetics, University of Leuven, Belgium.

The name Fryns syndrome was given by Lubinsky *et al*¹ to "a new variable multiple congenital anomaly syndrome" reported by us in 1979.² We first detected this syndrome in two female sibs who presented with cloudy corneae, diaphragmatic defects, and distal limb deformities.² The parents were unrelated and normal and chromosome investigation showed normal karyotypes in the parents and in one child investigated. In both children the condition was lethal before birth and pregnancy ended around 30 weeks. We therefore assumed that this

was a new lethal syndrome, and the assumption was confirmed when we found another instance, again in a stillborn child.³ Since then, other authors^{1 4-6} have made similar findings.

Clinical findings

A combination of the following findings should lead to the clinical diagnosis of this MCA syndrome.

- (1) Hydramnios in the second trimester of pregnancy with normal fetal growth.
- (2) Distinct craniofacial features (figs 1 and 2) with coarse face, broad, flat nasal bridge, large nose with

Received for publication 9 January 1987.
Accepted for publication 20 January 1987.

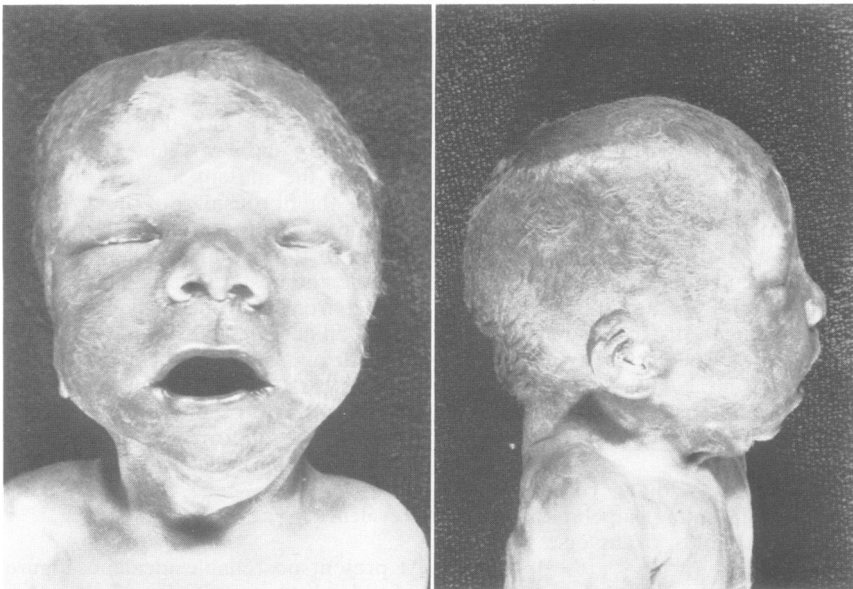

FIG 1 The characteristic craniofacial appearance with coarse face, broad, flat nasal bridge, and micrognathia.

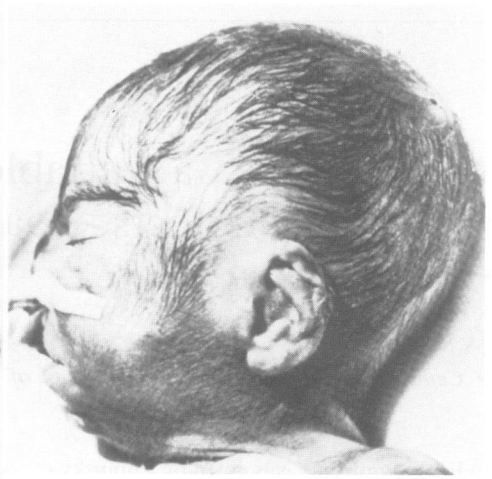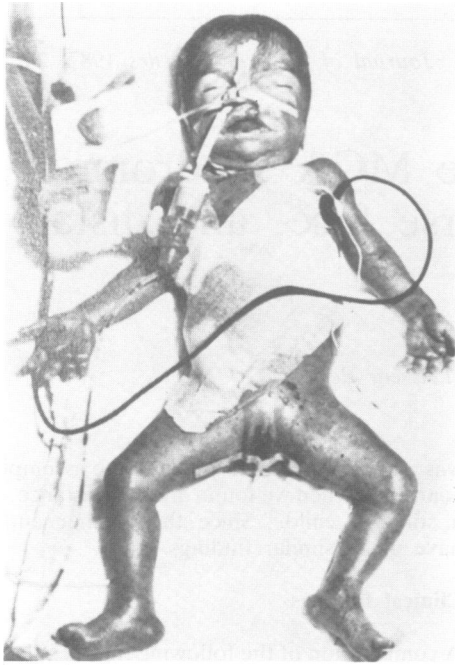


FIG 2 The craniofacial anomalies in Fryns syndrome. The excessive lanugo, most pronounced in the frontal and temporal regions, is another characteristic finding.

anteverted nostrils, short upper lip, macrostomia, cleft lip/palate, microretrognathia, and poorly shaped auricles with attached earlobes.

(3) Narrow thorax and hypoplastic, widely spaced nipples.

(4) Distal limb hypoplasia with brachytelephalangy, hypoplastic or absent nails, and rudimentary development of terminal (and middle) phalanges most pronounced on rays IV and V (fig 3).

(5) Internal malformations mainly include: diaphragmatic defects (aplasia of posterolateral parts) with primary or secondary lung hypoplasia (see pathogenesis) (fig 4); gastrointestinal anomalies including malrotation and non-fixation and duodenal or multiple atresias; genitourinary malformations with bicornuate uterus in the female.

(6) Associated anomalies. The variability in clinical expression in this syndrome is unknown at present because only eight patients have been reported so far. The following anomalies seem to be found in less than 50% of cases.

External malformations: cloudy corneae and microphthalmia, upward slanting palpebral fissures, short neck with nuchal folds, transverse palmar creases, and club foot.

Internal malformations: renal dysplasia and cortical cysts, cerebral malformations including Dandy-

Walker cyst, and multiple cerebellar glioneural heterotopias.

Aetiology and pathogenesis

Autosomal recessive inheritance is most likely. Two pairs of sibs have been reported^{1,2} and the parents were first cousins in two isolated patients reported by Meinecke and Fryns⁴ and Schinzel.⁶ The primary defect of the mutant allele is unknown. In most patients the fibrous part of the diaphragm, originating from the septum transversum, and the muscular portion of the diaphragm were well developed. In contrast, the posterolateral parts of the diaphragm, derived from the plicae pleuroperitoneales, were absent bilaterally. The formation of these plicae is induced by the outgrowth of both lungs. This suggests that lung hypoplasia with absence of lobulation might be the primary event, with secondary absence of formation and outgrowth of the plicae pleuroperitoneales.

Prevalence

At present no reliable incidence figures are available. In Leuven, we found three patients in a consecutive series of 900 perinatal necropsies and

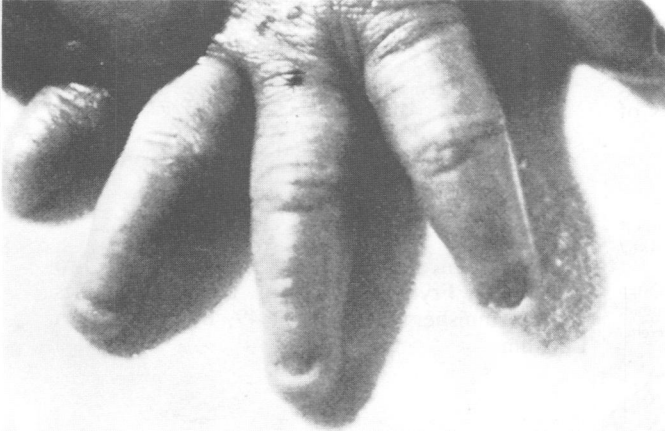

FIG 3 *Hypoplastic terminal phalanges of all fingers and toes with small nails.*

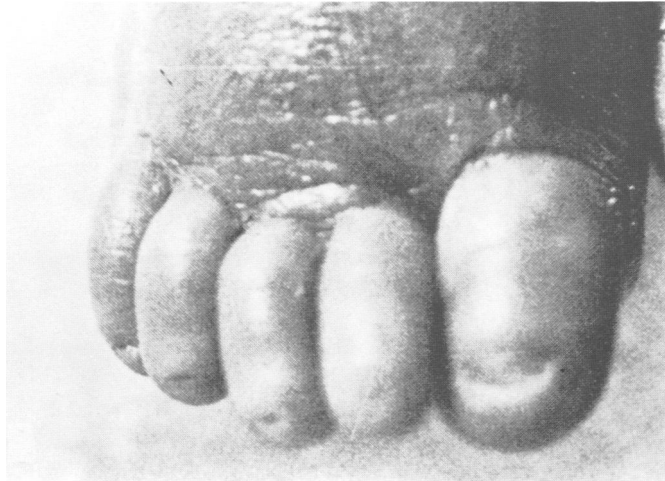


FIG 4 *Diaphragmatic defects with hypoplasia of the posterolateral parts, severe lung hypoplasia (lungs indicated by arrows), and herniation of abdominal organs into the thoracic cavity.*



Dr S Aymé (personal communication, 1986) found three newborns with this syndrome in a series of 850 perinatal necropsies. Long term prognosis seems to be poor and limited by the presence of severe lung hypoplasia. All patients died in the first weeks of life.

References

- ¹ Lubinsky M, Severn C, Rapoport JM. Fryns syndrome: a new variable multiple congenital anomaly (MCA) syndrome. *Am J Med Genet* 1983;**14**:461-6.
- ² Fryns JP, Moerman P, Goddeeris P, Bossuyt C, Van den Berghe H. A new lethal syndrome with cloudy corneae, diaphragmatic defects and distal limb deformities. *Hum Genet* 1979;**50**:65-70.
- ³ Goddeeris P, Fryns JP, Van den Berghe H. Diaphragmatic defects, craniofacial dysmorphism, cleft palate and distal limb deformities. A new lethal syndrome. *J Genet Hum* 1980;**28**:57-60.
- ⁴ Meinecke P, Fryns JP. The Fryns syndrome: diaphragmatic defects, craniofacial dysmorphism, and distal digital hypoplasia. *Clin Genet* 1985;**28**:516-20.
- ⁵ Young ID, Simpson K, Winter RM. A case of Fryns syndrome. *J Med Genet* 1986;**23**:82-4.
- ⁶ Schinzel A. *Catalogue of unbalanced chromosome aberrations in man*. Berlin, New York: Walter de Gruyter, 1984.

Correspondence and requests for reprints to Professor J P Fryns, Centre for Human Genetics, UZ Gasthuisberg, Herestraat 49, B-3000 Leuven, Belgium.