

Discussion

Only one case of similar deletion of bands 3q12→3q21 has previously been reported by Arai *et al.*¹ Other reports of 3q deletion had various deleted portions, such as 3q22.1→q24,² 3q23→q25,³ and 3q23→q26⁴ (table). The main clinical features of the present case were severe psychomotor retardation, craniofacial asymmetry, midfacial dysplasia, hypertelorism, epicanthus, high arched palate, long pointed chin, scoliosis, joint contractures, multiple skin pigmentations and renal anomaly. The case of Arai *et al.*¹ had different anomalies from our case including holoprosencephaly, arhinia, and cleft lip and palate. The proband survived only 58 hours after birth. This clinical inconsistency for the same chromosome deletion might be the result of individual difference of the recessive genes on the normal chromosome portion corresponding to the deletion or various environmental effects or both. There are still too

few cases to define common characteristics of deletion (3)(q12→q21).

References

- ¹ Arai K, Matukiyo H, Takazawa H. A case report of partial deletion of the long arm of the No 3 chromosome. *Med Genet Res* 1982;4:1-4.
- ² Williamson RA, Donlan MA, Dolan CR, Thuline HC, Harrison MT, Hall JG. Familial interstitial translocation of a portion of 3q into 11q resulting in duplication and deletion of region 3q22.1→q24 in different offspring. *Am J Med Genet* 1981;9:105-11.
- ³ Martsolf JT, Ray M. Interstitial deletion of the long arm of chromosome 3. *Ann Genet (Paris)* 1983;26:98-9.
- ⁴ Franceschini P, Silengo MC, Davi G, Bianco R, Biagioli M. Interstitial deletion of the long arm of chromosome 3 in a patient with mental retardation and congenital anomalies. *Hum Genet* 1983;64:97.

Correspondence and requests for reprints to Dr Noriko Okada, Department of Pediatrics, Tokyo Women's Medical College, 8-1 Kawata-cho, Shinjuku-ku, Tokyo 162, Japan.

Interstitial deletion and ring chromosome derived from 16q

CELESTE M KRAUSS*, DEBORAH CALDWELL†, AND LEONARD ATKINS†

*The Embryology-Teratology Unit, The Children's Service, and †the Department of Pathology, Massachusetts General Hospital, Harvard Medical School, Boston, Massachusetts, USA.

SUMMARY An interstitial deletion of 16q was identified in an infant with failure to thrive, dysmorphic facies, and congenital heart defects. The mother of this infant had a similar deletion of 16q with ring formation of a fragment presumed to be derived from the deleted portion of 16q. We discuss these cases and compare them to other reports of 16q deletions.

It has been suggested that there is a distinctive 'deletion 16q syndrome'¹ which is associated with 16q12.2→q13. We have studied two members of a family: the proband with 46,XX,del(16)(pter→q11.1::q13→qter) and her mother with 47,XX,del(16)(pter→q11.1::q13→qter)+r(16). Although the association of multiple congenital anomalies with deletions in this region is well known,²⁻⁷ this is the first report of an inherited 16q deletion.

*Present address: Cytogenetics Laboratory, Brigham and Women's Hospital/Harvard Medical School Department of Obstetrics and Gynecology, Boston, Massachusetts, USA.

Received for publication 16 December 1985.

Revised version accepted for publication 10 March 1986.

Case report

The proband was the 2.3 kg female product of a 22 year old G1 PO AbO woman. Gestation was thought to be 36 weeks, but the LMP date was not reliable. The pregnancy, delivery, and neonatal course were without complication. At three weeks of age, a 3/6 systolic ejection murmur was evaluated. Echocardiogram showed bicuspid aortic and pulmonic valves without severe obstruction. At four months the proband had failure to thrive with poor feeding tolerance resulting in vomiting and diarrhoea; her weight at this time was 3.5 kg (50th centile for a newborn infant),⁸ the length was 57.5 cm (50th centile for two months old), and the head circumference was 36 cm (50th centile for two weeks old). She was a small, dysmorphic child. The craniofacial features were remarkable for midfacial hypoplasia, a high forehead with prominent metopic ridge, a broad flat nasal bridge, and a small nose with anteverted nostrils. The intercanthal distance was 2.5 cm (97th centile) and the outer canthal distance 6.5 cm (75th centile). The palpebral fissures had an antimongoloid slant, the ears were low set and

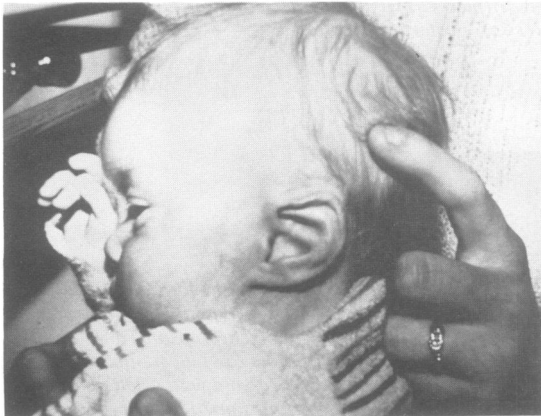
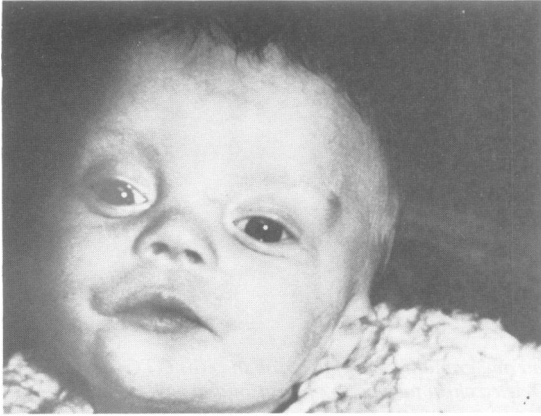

FIG 1 The proband showing mid-facial hypoplasia, prominent and high forehead, broad flat nasal bridge, small nose with anteverted nostrils, telecanthus, slanted palpebral fissures, and bow shaped mouth. The lateral views shows the prominent metopic ridge and low set and posteriorly rotated ears, with the upper part of the superior helix folded over.

posteriorly rotated and the upper part of the helix was folded over bilaterally, the mouth was bow shaped and the palate high arched (fig 1). The left hand was 6 cm in length and the third finger 2.25 cm (3rd centile). The left foot was 7.25 cm in length with the third toe anteriorly placed, and the right foot was 7 cm, with the second and fourth toes overlapping the third toe. Neurological examination showed an adequate suck, a weak cry, and generalised poor tone. She responded to visual and auditory stimuli.

The mother of the proband was the term product of an uncomplicated pregnancy weighing 3.2 kg at birth. Growth and development were reported to be normal. She had graduated from high school with

the help of 'special classes'. Her head circumference at the time of the examination at 23 years was 51 cm (50th centile for a six and a half year old). She had mild general hypotonia with a bow shaped mouth. The ears had bilateral folding over of the upper part of the helix (fig 2). There were no other abnormalities.

CYTOGENETIC ANALYSIS

Chromosome analysis was carried out on short term cultured peripheral lymphocytes from the proband, her parents, and maternal grandmother. The proband had a chromosome complement of 46. Evaluation of high resolution GTG banded chromosomes^{9 10} showed an interstitial deletion (fig 3c) with the breakpoints at 16q11·1q13.¹¹ Although normal variation in the heterochromatic region of 16q is well documented, further evaluation of this deletion with CGB banding¹² and DAPI fluorescence¹³ suggested that the deletion extended to include part of the centromere (fig 4).

Evaluation of the mother showed that in all of the

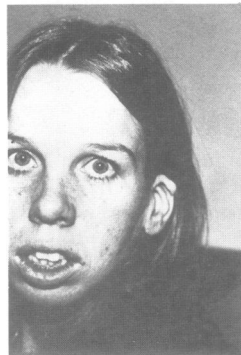
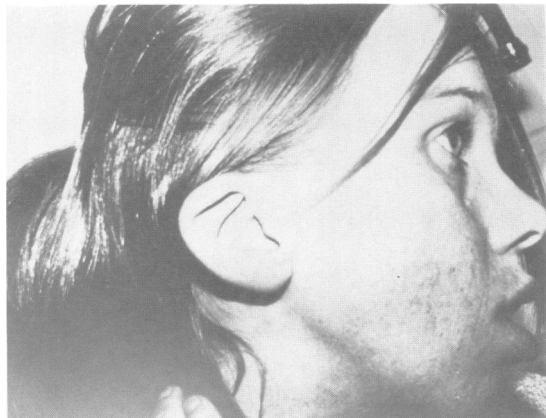
FIG 2 The mother showing a similar configuration of the nasal bridge and shape of the mouth and ears. The lateral view shows the low set, posteriorly rotated ears with overfolding of the superior helix.

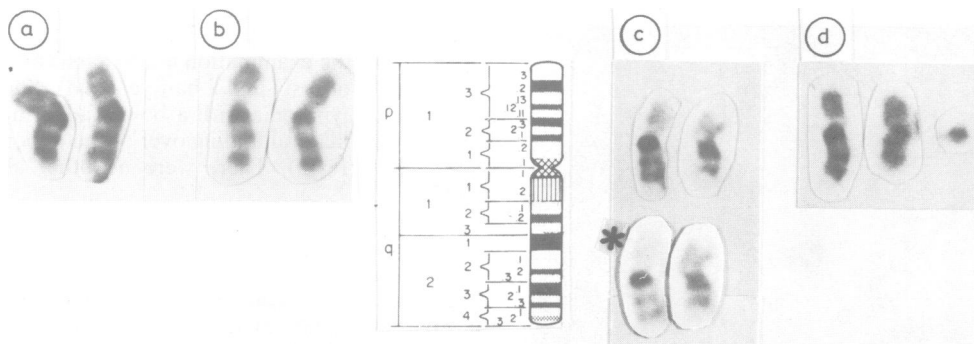


FIG 3 (a) GTG banded normal chromosome 16 pair from the maternal grandmother of the proband. (b) GTG banded normal chromosome 16 pair from the father of the proband. (c) Deleted chromosome 16 of the proband without the presence of a ring fragment. (*Note insert for magnification of this pair to show that there are two dark bands on the deleted long arm with absence of heterochromatin.) Karyotype 46,XX,del(16)(pter→q11·1::q13→qter) mat. (d) Deleted 16 plus the ring fragment of the mother. Karyotype 46,XX,del(16)(pter→q11·1::q13→qter)+r(16).

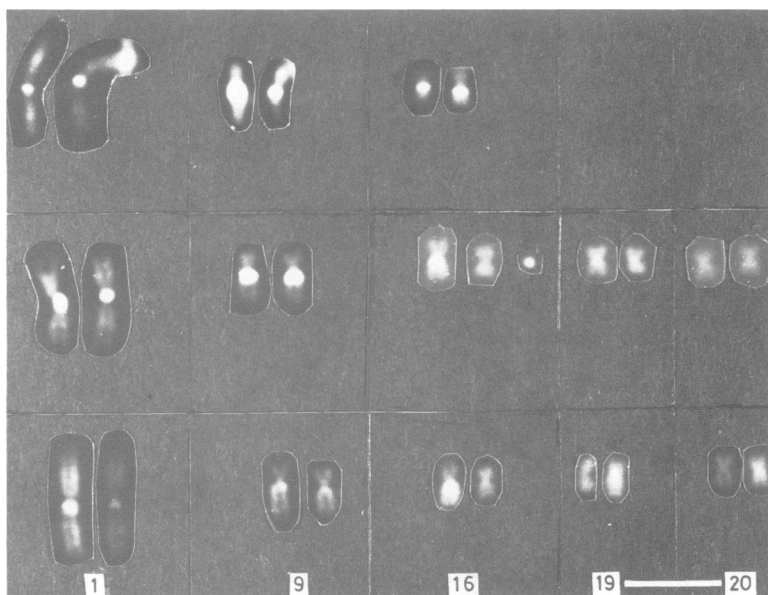


FIG 4 DAPI fluorescence of (top row) the maternal grandmother with no chromosome abnormality, (middle row) the mother of the proband with deletion of chromosome 16 and a ring fragment which stains positively with this centromeric stain, and (bottom row) the proband with one normally fluorescent chromosome 16, the deleted 16 without the fluorescence. The line connecting pairs 19 and 20 indicate that they cannot be distinguished.

cells examined an interstitial deletion of 16q was present, with the formation of a ring in 93·5% of these cells (fig 5). The breakpoints were at 16q11·1q13. The remaining 6·5% of cells did not have a ring. The ring was shown to contain centromeric material by CBG banding¹² and DAPI fluorescence.¹³ Although the ring could theoretically be derived from any chromosome, it seems most

reasonable to assume that it was derived from the deleted 16, where the deletion includes part of the centromere (fig 4).

Results of 90 metaphases evaluated from the proband's maternal grandmother and 30 cells from the father of the proband were normal (fig 3a and b). The maternal grandfather was not available for study.

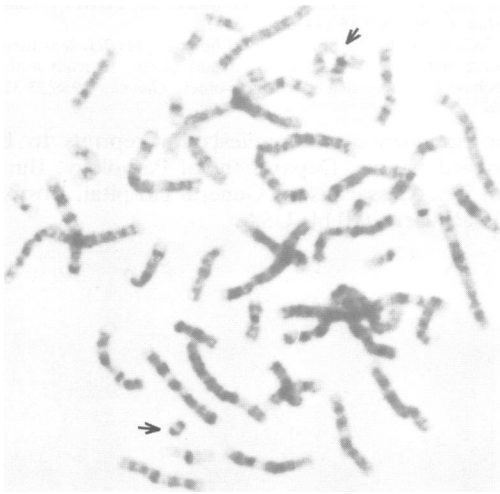


FIG 5 A GTG banded metaphase from the mother of the proband showing (upper arrow) a pair of chromosomes 16, one (on the right) with the expected heterochromatic darkly stained region at the centromere, and the other with this region deleted. Lower arrow shows the ring with darkly staining heterochromatin.

Discussion

We have reported a mother and daughter with an interstitial deletion of the long arm of chromosome 16 with the addition of a r(16) in the mother, presumed to be derived from the deleted interstitial fragment. Although the mother and daughter have some clinical features in common, the striking failure to thrive, severe cognitive delay, and heart defects are absent in the mother. The presence of functioning genetic material in the ring found in maternal cells presumably accounts for this phenotypic distinction. The less severe clinical abnormalities seen in the mother may be due to malalignment or loss of genes in the deleted 16 and the ring.

An unusual feature of this case is the proximal breakpoint through the centromere of chromosome 16 with active centromere material in the derived ring as well as in the original chromosome. This has been described in chromosomes of maize by McClintock.¹⁴ The presence of the centromere in the ring fragment accounts for its continued appearance in 93.5% of cells evaluated. However, the small ring remains susceptible to loss from the nucleus during mitosis, and this would account for the remaining 6.5% of the cells seen without the ring.¹⁴

The presence of the deletion in the more severely affected child without the ring suggests that the ring was either lost during maternal meiosis before

formation of the embryo, or was present during fertilisation and then subsequently lost during cell division, or perhaps the ring was not present during fertilisation because a maternal gamete without the ring but with the deletion was fertilised.

A 'deletion 16q syndrome' has been suggested which is associated with loss of 16q12.2→q13. There have been three terminal deletions of 16q and four interstitial deletions of 16q (including the present case) reported. The breakpoints have involved five different regions of the long arm of chromosome 16; this case represents a new region. The clinical features of the cases reported vary with regard to phenotype and organ systems affected and this has made it difficult to pick out the distinguishing features of this syndrome. Similarly, the cytogenetic abnormalities reported represent different structural defects. Each of the structural abnormalities may have a unique effect on genetic expression. The collection of additional cases such as the one described here may help clarify the phenotype(s) associated with 16q deletions.

Addendum

The proband died at 18 months.

We would like to thank Dr Lewis B Holmes for his comments on the clinical content of this paper. We also thank Cynthia McLaughlin for her technical assistance. This study was supported by the Department of Health and Human Services Public Health Service National Research Service Award 5T32 GM07748.

References

- Elder FFB, Ferguson JW, Lockhart LH. Identical twins with deletion 16q syndrome: evidence that 16q12.2-q13 is the critical band region. *Hum Genet* 1984;**67**:233-6.
- Fryns JP, Melchoir S, Jaeken J, van den Berghe H. Partial monosomy of the long arm of chromosome 16 in a malformed newborn karyotype 46,XX,del(16)(q12). *Hum Genet* 1977;**38**:343-6.
- Taysi K, Fishman M, Sekhon GS. A terminal long arm deletion of chromosome 16 in a dysmorphic infant: 46,XX,del(16)(q22). *Birth Defects* 1978;**14**:343-7.
- Fryns JP, Proesmans W, van Hoey G, van den Berghe H. Interstitial deletion 16q with typical dysmorphic syndrome. *Ann Genet (Paris)* 1981;**24**:124-5.
- Lin CC, Lowry RB, Snyder FF. Interstitial deletion for a region in the long arm of chromosome 16. *Hum Genet* 1983;**65**:134-8.
- Hoo JJ, Lowry RB, Lin CC, Haslam RHA. Recurrent de novo interstitial deletion of 16q in two mentally retarded sisters. *Clin Genet* 1985;**27**:420-5.
- Rivera H, Vargas-Moyeda E, Moller M, Torrew-Lamas A, Cantu JM. Monosomy 16q: a distinct syndrome. *Clin Genet* 1985;**28**:84-6.
- Smith DW, Jones KL. *Recognizable patterns of human malformations*. Philadelphia: Saunders, 1982:591-613.

- ⁹ Yunis JJ, Sawyer JR, Ball DW. The characterization of high resolution G-banded chromosomes of man. *Chromosoma* 1978;**67**:293–307.
- ¹⁰ Ikeuchi T. Inhibitory effect of ethidium bromide on mitotic chromosome condensation and its application to high-resolution chromosome banding. *Cytogenet Cell Genet* 1984;**38**:56–61.
- ¹¹ Harnden DG, Klinger HP. *An international system for human cytogenetic nomenclature*. New York: Karger, 1985.
- ¹² Sumner AT. A simple technique for demonstrating centromeric heterochromatin. *Exp Cell Res* 1972;**74**:304–6.
- ¹³ Donlon TA, Magenis RE. Methyl green is a substitute for distamycin A in the formation of distamycin A/DAPI C-bands. *Hum Genet* 1983;**65**:144–6.
- ¹⁴ McClintock B. The production of homozygous deficient tissues with mutant characteristics by means of the aberrant mitotic behavior of ring-shaped chromosomes. *Genetics* 1938;**23**:315–76.

Correspondence and requests for reprints to Dr Leonard Atkins, Department of Pathology, Burham 706, Massachusetts General Hospital, Boston, Massachusetts 02114, USA.