

Case reports

Journal of Medical Genetics 1988, **25**, 427–431

Translocation (1;22) in a child with bilateral oblique facial clefts

MAJED DASOUKI*, MASON BARR JR*†, ROBERT P ERICKSON*‡, AND BETH COX*

*Departments of Pediatrics and Communicable Diseases**, *Pathology†*, and *Human Genetics‡*, *University of Michigan Medical Center, Ann Arbor, Michigan 48109, USA.*

SUMMARY An eight month old girl was born with symmetrical bilateral oblique facial clefts and calcaneovarus foot deformity. CT scan of the head showed severe bilateral ocular hypoplasia and normal brain parenchyma. Peripheral blood karyotype showed a de novo balanced translocation between a chromosome 1 and 22. A submicroscopic imbalance secondary to this translocation cannot be ruled out. The pattern of the observed anomalies will help distinguish between oblique facial clefts and amniotic band disruption. Chromosomal studies should be performed in children with such rare malformations.

Cleft lip and palate are relatively common congenital anomalies seen separately or as part of many different congenital anomaly syndromes. Oblique facial clefts are much more rare, constituting 0.25% of all facial clefts.¹ Several different classifications of oblique clefts have been proposed.^{2–5} Based on the anatomy and severity of the defect, Morian² recognised two major types, naso-ocular and oro-ocular, with the latter type further subdivided into oromedial-canthal and orolateral-canthal types. A few case reports of oblique clefts have included information about the karyotype and those have been cytogenetically normal.⁶ The infant we are reporting had bilateral oblique facial clefts (oromedial-canthal type) associated with a balanced chromosomal translocation (1;22).

Case report

This girl, born at term, was referred at one week of age for evaluation of congenital anomalies. She was born to a 23 year old G1P0–1 white mother and 26

year old father; they were not consanguineous. The pregnancy was uncomplicated and there was no history of trauma, leakage of amniotic fluid, or exposure to unusual drugs. Delivery was assisted with low forceps because of failure to progress. Fetal membranes were intact. Apgar scores were 9 at one and five minutes. Growth measurements were: weight 3.6 kg (90th centile), head circumference 35.3 cm (90th centile), and length 49.6 cm (50th centile). The skull was of normal shape. Lateral to each nostril a complete cleft extended upwards to the medial canthus of the respective eye (fig 1). Inferiorly, the cleft involved the lip, gingiva, and palate. The middle third of the right lower eyelid had a coloboma. Both corneae and sclerae were covered by cutaneous ectoderm and granulation tissue and there were synechiae between this tissue and the eyelids. Four symmetrical circumferential

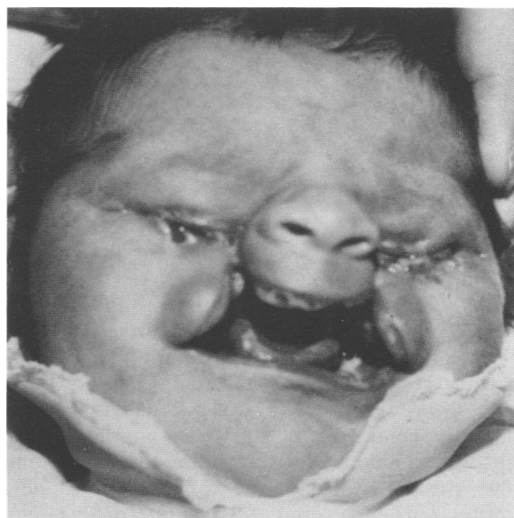

FIG 1 Patient's face showing the bilateral clefts. Also notice the right lower eyelid coloboma.

Received for publication 6 April 1987.

Revised version accepted for publication 16 June 1987.

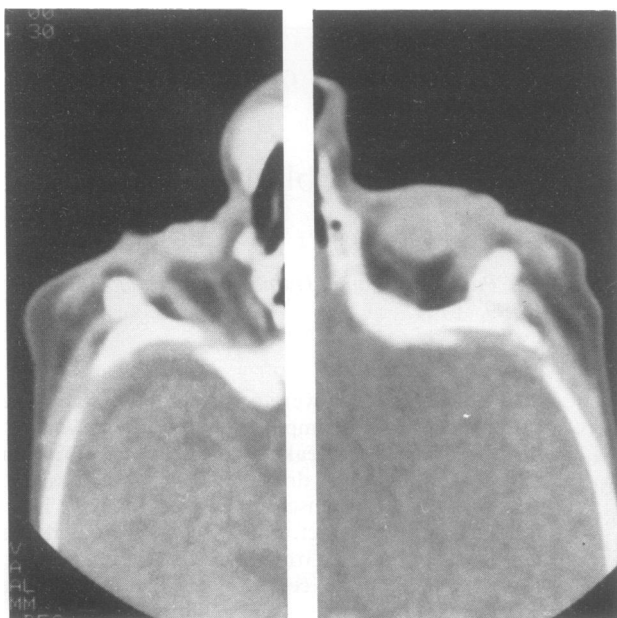

FIG 2 Computerised tomography of the head showing bilateral ocular hypoplasia.

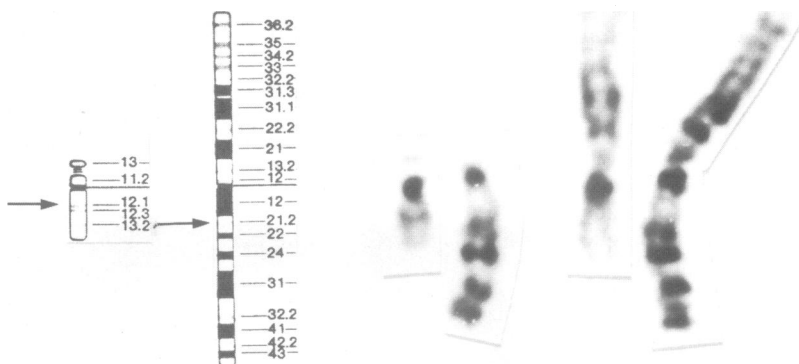


FIG 3 Partial karyotype showing the translocation between a chromosome 1 and 22 (right). Breakpoints are indicated by arrows on the idiogram (left).

cutaneous folds were seen on the arms and legs. The remainder of the physical examination was unremarkable except for unusually deep palmar creases and left calcaneovarus foot deformity. Chest and pelvic x rays were normal. Brain stem evoked auditory responses were normal. CT scan of the head showed normal brain parenchyma, severe bilateral ocular hypoplasia, more marked on the right, and a palatal cleft extending up to the vomer bone (fig 2). Ocular muscles and optic nerve bundles were also small and asymmetrical. Giemsa banded peripheral blood lymphocyte karyotype showed a balanced reciprocal translocation

[46,XX,t(1;22)(q21;q12)] (fig 3). Both parents had normal karyotypes.

At eight months of age, she has undergone multiple reconstructive surgical procedures. Her development has not been formally assessed but does not appear unduly delayed for a sightless infant.

Discussion

Among other anomalies, oblique facial clefts have been induced in laboratory animals by salicylate poisoning⁷ and vitamin A deficiency.⁸ No history of

unusual drug or chemical exposure was obtained in this case. Amniotic bands can disrupt craniofacial development but the resulting defects characteristically do not conform to the normal planes of closure and merging of the embryonic facial processes.⁹ In addition, they are known to cause limb and digital amputations in utero. Several patients with evidence of amniotic bands have been reported as cases of oblique facial cleft.^{1 4 10} On initial examination amniotic band facial disruption was considered because of the circumferential cutaneous folds, but with the symmetrical distribution of the facial clefts and absence of bands or constriction rings, this diagnosis seemed unlikely.

The clefts seen here correspond to the embryonic naso-optic furrow that lies between the nasolateral and nasomedial processes. As the volume of mesoderm in these processes expands, the processes merge and obliterate the furrow.¹¹ In our patient the furrow remains evident because normal merging did not occur. The clefts of the lip and palate are secondary to failure of fusion of the maxillary processes with the nasomedial process and failure of the palatal shelves to fuse across the midline. It also appears likely that eyelid formation was defective with failure of the lids to fuse and protect the developing eye. As a result of chronic exposure to the amniotic fluid the corneae could become dysplastic and be overgrown with fibrous tissue and cutaneous ectoderm from the eyelids. The abnormal palmar creases, club foot, and the observed limb cutaneous folds suggest disturbance of development more extensive in space and time than would be necessary to account for maldevelopment of the face.

To our knowledge there are no reports of familial incidence of oblique clefts to suggest a genetic basis. In addition, the few karyotypes reported in these patients have been normal.⁶ Our patient has an apparently de novo balanced translocation. Genetic imbalance may result from a small deletion or duplication, gene mutation, or position effect. This may be aetiologically important in this child's birth

defects. Large newborn surveys have shown a 1.9/1000 overall incidence of balanced chromosomal rearrangements including translocations and inversions.¹² The group with mental retardation had a higher incidence of de novo translocations (1.8/1000) versus the normal group (0.25/1000). This patient is too young to assess her development fully and other effects of this chromosomal translocation could become evident later in childhood.

References

- 1 Kubaček V, Pěnkava J. Oblique clefts of the face. *Acta Chir Plast (Praha)* 1974;16:152-63.
- 2 Morian R. Ueber die schrage Gesichtsspalte. *Arch Klin Chir* 1887;35:245-88.
- 3 Harkins CS, Berlin A, Harding RL. A classification of cleft lip and cleft palate. *Plast Reconstr Surg* 1962;29:31-9.
- 4 Boo-Chai K. The oblique facial cleft: a report of 2 cases and a review of 41 cases. *Br J Plast Surg* 1970;23:352-9.
- 5 Tessier P. Anatomical classification of facial, craniofacial and laterofacial clefts. *J Maxillofac Surg* 1976;4:69-92.
- 6 Sano S, Tani T, Nishimura Y. Bilateral oblique facial cleft. *Ann Plast Surg* 1983;11:434-7.
- 7 Warkany J, Takacs E. Experimental production of congenital malformations in rats by salicylate poisoning. *Am J Pathol* 1959;35:315-31.
- 8 Nelson MM, Wright HV, Ashing SH, Evans HM. Multiple congenital abnormalities resulting from transitory deficiency of pteroylglutamic acid during gestation in the rat. *J Nutr* 1955;56:349-69.
- 9 Jones KL, Smith DW, Hall BD, et al. A pattern of craniofacial and limb defects secondary to aberrant tissue bands. *J Pediatr* 1974;84:90-4.
- 10 Dey DL. Oblique facial clefts. *Plast Reconstr Surg* 1973;52:258-63.
- 11 Stark R. Development of the face. *Surg Gynecol Obstet* 1973;137:403-8.
- 12 Funderburk SJ, Spence M, Sparkes RS. Mental retardation associated with 'balanced' chromosome rearrangements. *Am J Hum Genet* 1977;29:136-41.

Correspondence and requests for reprints to Dr Majed Dasouki, Division of Pediatric Genetics, Department of Pediatrics, University of Michigan Medical Center, D1225 Medical Professional Building, Box 0718, Ann Arbor, Michigan 48109-0718, USA.