

Functional Xp disomy and de novo t(X;13)(q10;q10) in a girl with hypomelanosis of Ito

L S Correa-Cerro, H Rivera, A I Vasquez

Abstract

We report on a 16 month old girl with hypomelanosis of Ito and a balanced de novo (X;13)(q10;q10) translocation in which the der(Xp13q) had the X centromere (as assessed by FISH with the DXZ3 probe). A functional Xp disomy was shown in a small proportion of cultured lymphocytes by means of a BrdU terminal pulse. This observation supports the notion of a distinct form of hypomelanosis of Ito resulting from a functional Xp disomy. (*J Med Genet* 1997;34:161-163)

Keywords: hypomelanosis of Ito; X;autosome translocation; functional Xp disomy.

Hypomelanosis of Ito (HI) is characterised by hypopigmented whorls, streaks, and patches typically distributed along the lines of Blaschko; abnormalities of the central nervous, eye, and musculoskeletal systems have also been described.¹⁻³ When looked for, chromosomal abnormalities have been documented in nearly half of the patients and can be classified into two main groups: (1) various mosaicisms in about 20 patients with no instance of X;autosome translocation and a few XX/XY chimerisms,^{4,7} and (2) non-mosaic balanced X;autosome translocations in eight female patients (table 1). In the first group the pigmentary dysplasia seemingly reflects the clonal origin of chromosomally abnormal melanoblasts from neural crest precursors,⁴ whereas in the second group mosaicism for Xp functional disomy, rather than a disruption of a X linked gene, appears to be the causative mechanism.¹⁴

Case report

The patient was the fourth child born to a 35 year old mother and an unrelated 38 year old father. The mother had had one abortion. Both

parents and their three older children were normal; in particular, there was no family history of pigmentary anomalies. She was delivered at term by caesarean section because of pre-eclampsia; weight was 3110 g, length was 48 cm, and Apgar scores were 8 and 9 at one and five minutes respectively. At birth, streaky hypopigmented lesions were noted on the body. From 3 months of age she developed generalised tonic-clonic convulsions, which were unsuccessfully treated with phenobarbital. An EEG showed an abnormal generalised activity whereas a CT scan showed isodense zones in the frontal lobes. Ophthalmoscopic examination at 4 months showed nystagmus and hypoplasia of the fovea more apparent in the left eye. Physical examination at 16 months of age (fig 1) showed weight 10.5 kg (90th-97th centile), length 85 cm (above the 97th centile), OFC 44 cm (10th-20th centile), hypotonia, no head control, nystagmus, synophrys, upward slanting palpebral fissures, dysplasia of the teeth, widely spaced nipples, and irregular streaky hypopigmented lesions with a mottled, streaked, or whorled appearance on both sides of the trunk and the extremities; vesicobullous or verrucous lesions were not noted.

Radiographs showed brachycephaly, dorso-lumbar scoliosis, hypoplastic ischia, and an asynchronous accelerated bone age (pelvis 4 years, hands between 2 and 3 years).

CYTOGENETIC STUDIES

A peripheral blood karyotype (G bands) was 46,X,t(X;13)(Xp13q;Xq13p) in all 50 cells examined (fig 2A). The parents' karyotype was normal. A replication X study with a BrdU terminal pulse (n=150 cells) showed an inactive normal X chromosome as the predominant pattern, but in two cells (1.3%) the der(Xq13p) was inactive whereas the normal X and the der(Xp13q) were early replicating. FISH was performed according to the manu-

Table 1 Hypomelanosis of Ito with X; autosome translocations

Sex	Age	Karyotype	X inactivation patterns in cultured cells	Reference
F	5 y	46,X,t(X;9)(p11.2;q33.2) de novo (L)	Normal X inactive in 100% of 21 cells (L)	8
F	15 y	46,X,t(X;9)(p11;q34) de novo (L & S)	Normal X inactive in more than 90% of cells (L)	9
F	6 mth	46,X,t(X;14)(q11;q13) de novo (L)	—	10
F	3 y	46,X,t(X;22)(q11.2;q13.3) de novo (L)	—	5
F	3 y	46,X,t(X;18)(p11;q23) de novo (L & S)	—	11
F	12 mth	46,X,t(X;17)(q13;p13) de novo (L & T)	—	12
F	7 y	46,X,t(X;10)(p11;q11) mat (L)	Normal X inactive in 100% of 50 cells (L)	13
F	21 y	46,X,t(X;17)(cen;cen) de novo (L)	Normal X inactive in 100% of 33 cells (L) and in 100% of 29 cells (normal and abnormal S)	14
F	16 mth	46,X,t(X;13)(q10;q10) de novo (L)	Normal X inactive in 98.7%/der(Xq13p) inactive in 1.3% of 150 cells (L)	Present case

L = lymphocytes, T = tumour cells (plexus papilloma), S = skin fibroblasts.

División de Genética,
Instituto Mexicano del
Seguro Social, Ap
Postal 1-3838,
Guadalajara, Jalisco,
México

L S Correa-Cerro
H Rivera
A I Vasquez

Correspondence to:
Dr Rivera.

Received 15 April 1996
Revised version accepted for
publication
11 September 1996

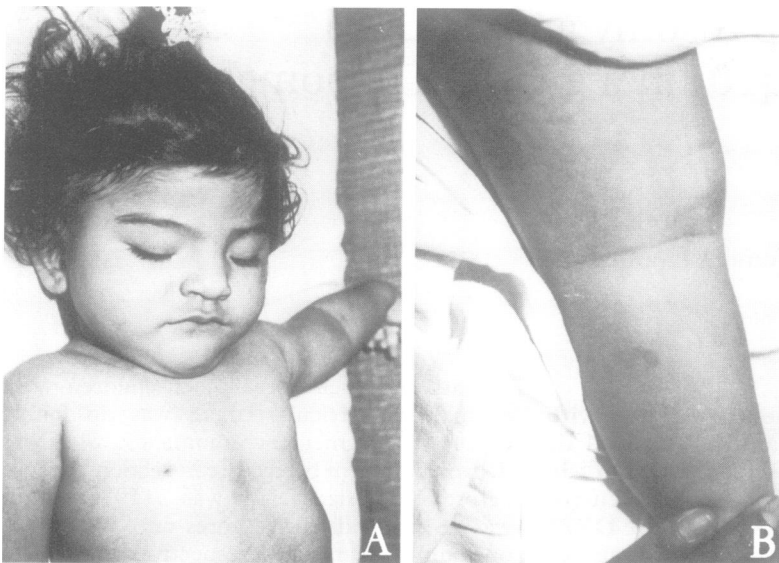

Figure 1 The patient at 16 months of age. (A) Note synophrys and upward slanting palpebral fissures. (B) Irregular streaky hypopigmented lesions on the dorsal aspect of the leg.

facturer's protocol (Oncor) with a digoxigenin labelled X centromere probe (DXZ3). The sites of hybridisation were visualised using either rhodamine labelled antidigoxigenin/DAPI or fluorescein labelled antidigoxigenin/propidium iodide. We observed the hybridisation signal on the normal X chromosome and on the der(Xp13q) chromosome (fig 2B). Therefore, the X breakpoint was assigned to q10. A cell line of this patient is not available.

Discussion

The balanced X;autosome translocations found in nine unrelated females with sporadic HI (table 1) exhibit some distinct characteristics, namely non-mosaic occurrence, a pericentromeric or centromeric X chromosome breakpoint, apparent randomness of the autosomes involved, and, apart from one case,¹³ a de novo origin. Therefore, these patients may constitute a distinct form of HI. The skewed X inactiva-

tion in the present case conforms to previous analyses in cultured cells^{8 9 13 14} (table 1), but the alternate pattern documented in a small proportion of cells confirms previous observations in either cultured lymphocytes⁹ or uncultured skin cells.¹⁴ As for the causative mechanism, the work of Hatchwell *et al*¹⁴ points to a mosaic Xp functional disomy rather than to a gene disruption, a conclusion supported by our findings. In fact, the six other translocations in which the X chromosome functional disomy was not assessed^{5 8 10-13} are consistent with this view, that is, the X chromosome breakpoint in all of them allows for the occurrence of the alternate inactivation pattern in which the derivative with the X inactivation centre is inactivated and so these cells are functionally disomic for Xp sequences. Since a functional non-mosaic Xp disomy does not result in a HI phenotype (for example, Gustashaw *et al*¹⁵), it may be inferred that Xp disomy, like other imbalances (triploidy, trisomy 18, and tetrasomy 12p⁴⁻⁷), only causes such a phenotype when occurring in a mosaic state.¹⁴ Moreover, the absence of male patients with HI and a balanced X;autosome translocation, if not a random event, is in keeping with this, as X chromosome disomy cannot occur in them. The single inherited X;autosome translocation¹³ may be accounted for by a more stringent selection in the mother whose nearly normal phenotype facilitated the transmission of the translocation to her affected daughter.

According to the banding patterns, the present translocation was regarded as a whole arm exchange, yet FISH results indicated that the X chromosome breakpoint was outside the centromere. Hence, this rearrangement differs from the single true whole arm translocation associated with HI.¹⁴

This work was supported in part by a grant from the Fundación Mexicana para la Salud.

1 Ito M. Studies on melanin. XI. Incontinentia pigmenti achromians: a singular case of nevus depigmentosus

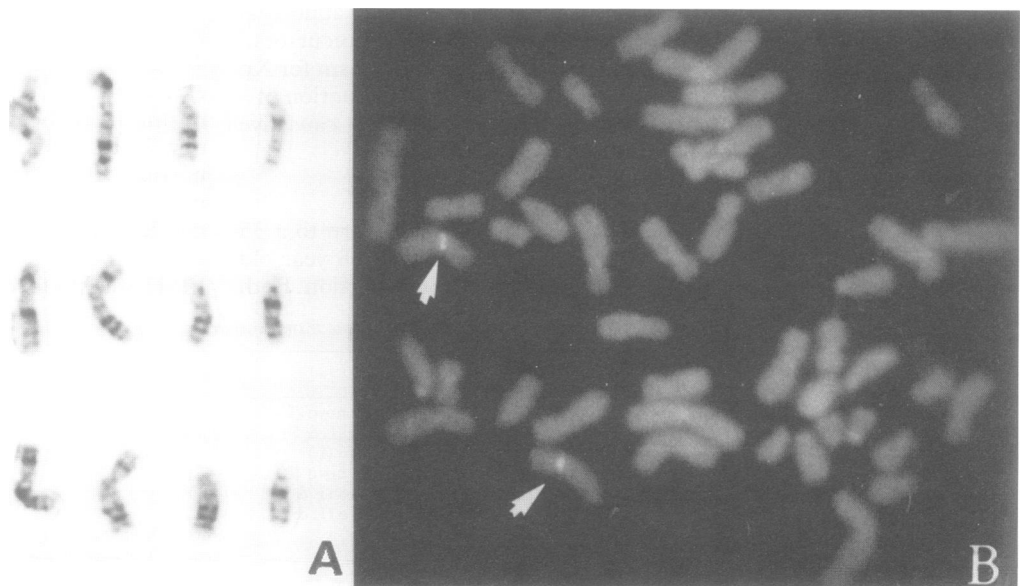


Figure 2 (A) Partial G banded karyotypes showing the $t(X;13)(Xp13q;Xq13p)$ in the patient; the derivatives are on the right in each pair. (B) Results after hybridisation with DXZ3 labelled with digoxigenin and detected with rhodamine labelled antidigoxigenin/DAPI. Note the signal on both the normal X and the der(Xp13q).

- systematicus bilateralis. *Tohoku J Exp Med* 1952;55(suppl):57-9.
- 2 Jelinek JE, Bart RS, Schiff GM. Hypomelanosis of Ito ("incontinentia pigmenti achromians"): report of three cases and review of the literature. *Arch Dermatol* 1973;107:596-601.
 - 3 Glover MT, Brett EM, Atherton DJ. Hypomelanosis of Ito: spectrum of the disease. *J Pediatr* 1989;115:75-80.
 - 4 Thomas IT, Frias JL, Cantu ES, Lafer CZ, Flannery DB, Graham JG. Association of pigmentary anomalies with chromosomal and genetic mosaicism and chimerism. *Am J Hum Genet* 1989;45:193-205.
 - 5 Sybert VP, Pagon RA, Donlan M, Bradley CM. Pigmentary abnormalities and mosaicism for chromosomal aberration: association with clinical features similar to hypomelanosis of Ito. *J Pediatr* 1990;116:581-6.
 - 6 Ritter CL, Steele MW, Wenger SL, Cohen BA. Chromosome mosaicism in hypomelanosis of Ito. *Am J Med Genet* 1990;35:14-17.
 - 7 Flannery DB. Pigmentary dysplasias, hypomelanosis of Ito, and genetic mosaicism. *Am J Med Genet* 1990;35:18-21.
 - 8 Hodgson SV, Neville B, Jones RWA, Fear C, Bobrow M. Two cases of X/autosome translocation in females with incontinentia pigmenti. *Hum Genet* 1985;71:231-4.
 - 9 Gilgenkrantz S, Tridon P, Pinel-Briquel N, Beurey J, Weber M. Translocation (X;9) (p11;q34) in a girl with incontinentia pigmenti (IP): implications for the regional assignment of the IP locus to Xp11? *Ann Genet (Paris)* 1985;28:90-2.
 - 10 Penchaszadeh VB, Babu A, Schwartz M, David KL, Popescu S, Rubenstein C. Hypomelanosis of Ito in a girl with a de novo translocation (X;14)(q11;q13). *Am J Hum Genet* 1989;45(suppl):A219.
 - 11 Lungarotti MS, Martello C, Calabro A, Baldari F, Mariotti G. Hypomelanosis of Ito associated with chromosomal translocation involving Xp11. *Am J Med Genet* 1991;40:447-8.
 - 12 Steichen-Gersdorf E, Trawoger R, Duba HC, Mayr U, Felber S, Utermann G. Hypomelanosis of Ito in a girl with plexus papilloma and translocation (X;17). *Hum Genet* 1993;90:611-13.
 - 13 Koiffmann CP, de Souza DH, Diament A, et al. Incontinentia pigmenti achromians (hypomelanosis of Ito, MIM 146150): further evidence of localization at Xp11. *Am J Med Genet* 1993;46:529-33.
 - 14 Hatchwell E, Robinson D, Crolla JA, Cockwell AE. X-inactivation analysis in a female with hypomelanosis of Ito associated with a balanced X;17 translocation: evidence for functional disomy of Xp. *J Med Genet* 1996;33:216-20.
 - 15 Gustashaw KM, Zurcher V, Dickerman LH, Stallard R, Willard HF. Partial X chromosome trisomy with functional disomy of Xp due to failure of X inactivation. *Am J Med Genet* 1994;53:39-45.