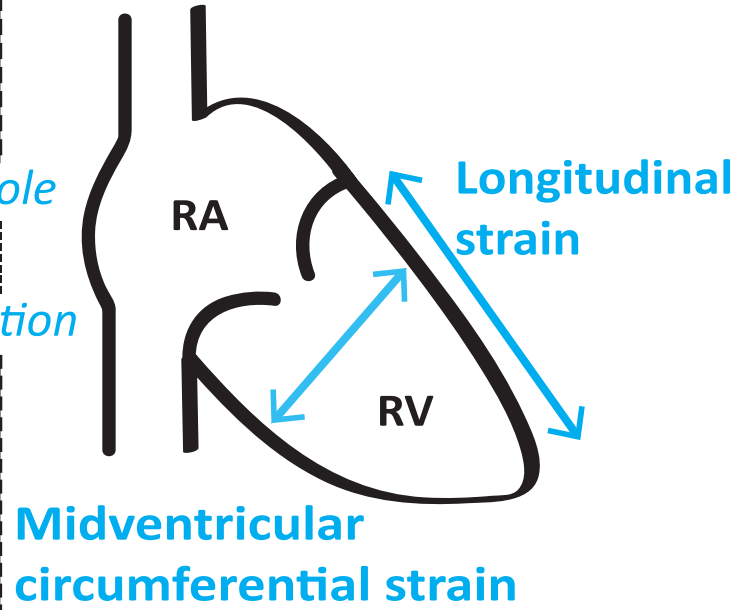
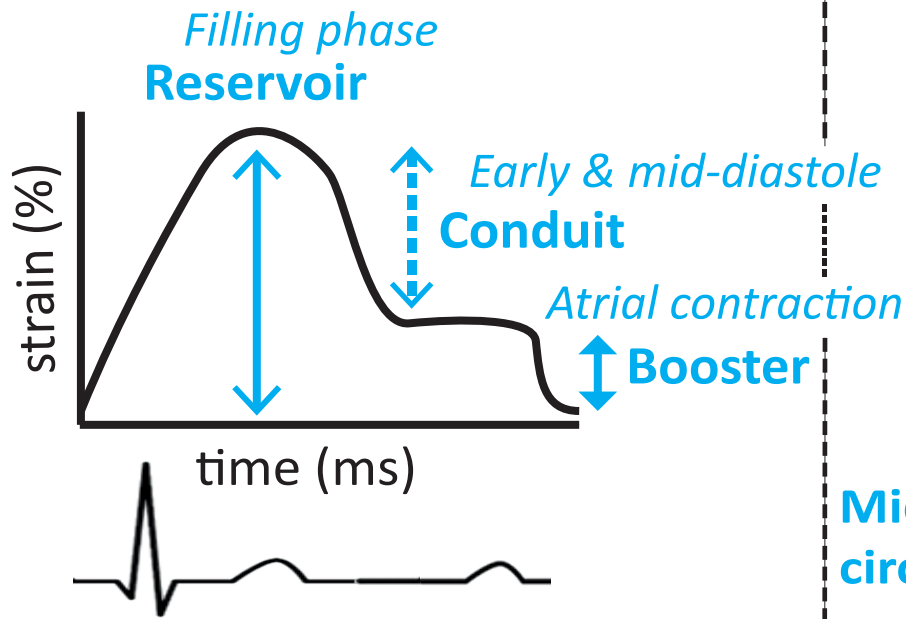


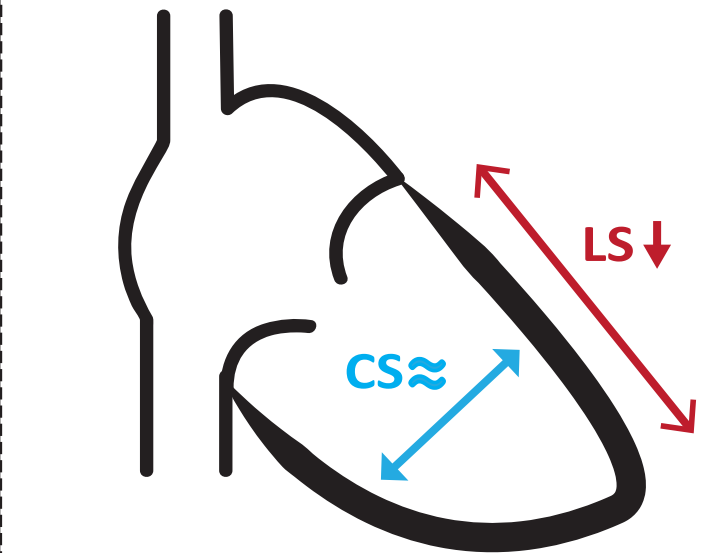
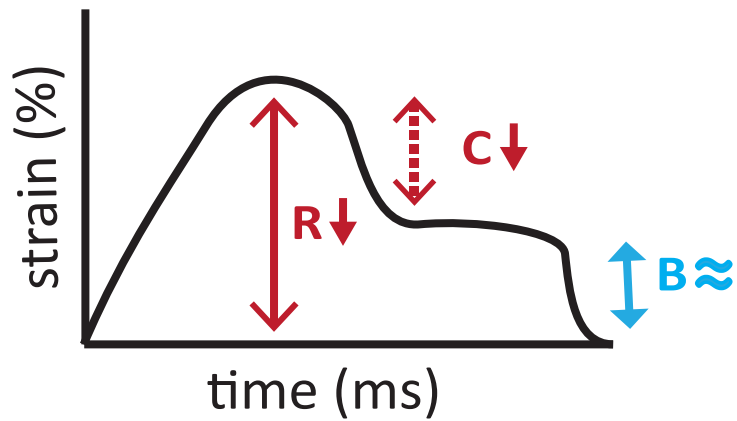
Right atrial strain

Right ventricular strain

Healthy control



Precapillary PH patients with relatively preserved RVEF (>40%)



Precapillary PH patients with severely reduced RVEF (<40%)

