

# Monozygotic twins discordant for Aicardi syndrome

T Costa, W Greer, G Rysiecki, J R Buncic, P N Ray

## Abstract

**Aicardi syndrome is a developmental disorder characterised by agenesis of the corpus callosum, retinal lacunae, seizures, and developmental delay. It is believed to be X linked with lethality in males. We report a set of monozygotic female twins one of whom is healthy and intellectually normal while the other has the classical Aicardi phenotype with profound retardation. Family history is negative. Both had normal karyotypes. Monozygosity was established by blood grouping, chromosomal heteromorphisms, and DNA analysis using six hypervariable probes (five autosomal and one X linked) and three X linked RFLP probes. We tested the hypothesis that preferential inactivation of a different X chromosome had occurred in each girl. Methylation sensitive RFLP analysis of DNA from EBV transformed B lymphocytes and cultured skin fibroblasts using *MspI/HpaII* digestion and probing with M27 $\beta$  showed a very similar pattern of X inactivation in both twins with no evidence of preferential expression of one particular X chromosome. We conclude that the abnormalities in the affected twin are probably the consequence of a postzygotic mutation in early embryonic development.**

(*J Med Genet* 1997;34:688-691)

**Keywords:** Aicardi syndrome; monozygotic twins; discordant; X linked inheritance

Aicardi syndrome is a developmental disorder characterised by agenesis of the corpus callosum, seizures, developmental delay, and distinctive chorioretinal abnormalities described as "lacunae". Since it was first reported by Aicardi *et al*<sup>1</sup> in 1965, nearly 200 cases have been reported,<sup>2</sup> all females with the exception of one male with a 47,XXY karyotype.<sup>3</sup> This is suggestive of X linked inheritance with lethality in males. Tentative mapping of the gene has been made to the Xp22 region based on an affected female with an apparently balanced X;3 translocation with a breakpoint through Xp22.<sup>4</sup> As expected for a dominant mutation with poor reproductive fitness, almost all cases have been sporadic. The one exception, in two daughters of healthy, non-consanguineous parents,<sup>5</sup> can be explained by germline mosaicism in one of the parents. Seven twin pairs have been reported<sup>2-9</sup> and all were discordant. Of the four girl-girl pairs, three were known to

be dizygotic,<sup>2</sup> while zygosity was not indicated in the fourth pair.<sup>8</sup> We describe here two young women who were shown conclusively to be monozygotic twins who are discordant for Aicardi syndrome.

## Case report

The 19 year old twins were the product of the fifth and last pregnancy of healthy, non-consanguineous parents of mixed European extraction. Of the other four children, two boys and two girls, three were in good health. One of the sons died at the age of 4 months presumably of sudden infant death syndrome. The oldest daughter had pyloric stenosis in infancy requiring surgical correction. The mother was 34 years of age at the time of delivery while the father was 39. The pregnancy was normal with the exception of a flu-like illness and vaginal spotting of a few days duration in the first trimester. Delivery was at term. The proband, twin 1, was delivered by vertex vaginal route without complications. Her twin was delivered in breech. Birth weight was 3080 g for twin 1 and 3420 g for twin 2. There was a single placenta with two separate cords. Findings on microscopic examination of the membranes were suggestive of a dichorionic gestation.

Twin 2 has been in good health and has had normal psychomotor development. The proband is patient 14 in the series described by Menezes *et al*.<sup>10</sup> She was noted to have unilateral microphthalmos in the newborn period. Seizure activity was first recognised at the age of 2½ months and has been a persistent problem despite anticonvulsant medication. A retinal detachment was noted in the right microphthalmic eye at the age of 8 years. Her psychomotor development has been profoundly delayed. She has not acquired any speech and remains wheelchair bound. She recognises members of the family and reaches for objects, suggesting that she does have some vision. A diagnosis of Aicardi syndrome was made at the age of 8 months on the basis of typical retinal abnormalities on fundoscopic examination and the finding of agenesis of the corpus callosum on pneumoencephalogram. On examination at the age of 17 years, the proband presented as a profoundly retarded young woman. The head circumference was 51 cm (<2nd centile). The occiput was flat. There was facial asymmetry with right microphthalmia, a right facial hemiatrophy, and prominent right auricle. There was a maxillary overbite. There was a left spastic hemiparesis with flexion contractures of the fingers, knee, and

Departments of Genetics and Pediatrics, The Hospital for Sick Children, and Department of Pediatrics, University of Toronto, Canada  
T Costa

Department of Pathology, Victoria General Hospital, Dalhousie University, Halifax, Canada  
W Greer

Department of Genetics, The Hospital for Sick Children, Toronto, Canada  
G Rysiecki\*

Department of Ophthalmology, The Hospital for Sick Children and University of Toronto, Toronto, Canada  
J R Buncic

Departments of Genetics and Pediatric Laboratory Medicine, The Hospital for Sick Children, and Department of Molecular and Medical Genetics, University of Toronto, Toronto, Canada  
P N Ray

Correspondence to:  
Dr Costa, Division of Clinical Genetics, The Hospital for Sick Children, 555 University Avenue, Toronto, Ontario, Canada M5G 1X8.

\*Present address: Cellmark Diagnostics, Oxfordshire, UK.

Received 28 October 1996  
Revised version accepted for publication 3 March 1997

hip. However, she was hyporeflexive, especially on the right. There was ankle clonus and a bilateral Babinski sign. Ocular examination showed a microphthalmic right eye, the fundus of which could not be visualised. In the left eye, the anterior segment and lens were normal. The fundus had numerous lacunae surrounding the disc (fig 1) but the macula appeared intact. She followed light and reached for objects. An MRI of the head showed complete absence of the corpus callosum. The septum pellucidum was present in the midline. The ventricles were large and misshapen secondary to associated parenchymal atrophy. The right orbit enclosed a microphthalmic eye with evidence of the sequelae of the previous retinal detachment.

#### Materials and methods

Blood was collected from the twins, both parents, and a brother and a sister. A skin biopsy was done on each twin in the deltoid region. Chromosomes were studied using G and C banding, solid staining, and prophase banding on blood lymphocytes. Blood groups (ABO, Rh, MNSS, and Lewis systems) were analysed by standard techniques.

Total genomic DNA was extracted from EBV transformed lymphoblastoid cell lines and from cultured skin fibroblasts. For zygosity determination and X chromosome segregation analysis, DNA samples (3 µg) were digested to completion with the appropriate restriction endonucleases, size fractionated on 0.6% agarose gels, and transferred to nylon membranes (Amersham, Hybond) by Southern blotting. X chromosome inactivation studies were conducted using the probe M27β.<sup>15</sup> DNA samples (9 µg) were predigested with restriction endonuclease *Pst*I. A 3 µg aliquot was further digested with *Msp*I. A second aliquot was digested with the methylation sensitive enzyme

*Hpa*II, which recognises the same restriction site as *Msp*I, but only when the site is not methylated. These samples were then size fractionated, transferred to nylon membranes as described above, and probed with <sup>32</sup>P labelled M27β.

Six hypervariable probes for markers on six different chromosomes were used to establish the zygosity of the twins. The probes were 3'HVR,<sup>12</sup> YNH24, JC23.1, CMM86, EFD64.2,<sup>13</sup> and M27β.<sup>14</sup> X linked RFLP probes include 782,<sup>15</sup> GMGX9,<sup>16</sup> and XJ1.1.<sup>17</sup>

#### Results

Chromosome studies on peripheral blood using G banding techniques were normal in both twins. The parents and twins were further studied using solid staining, Q banding, and C banding. The family was informative for heteromorphisms at C-1qh, C-9qh, Q-13 cent, and Q-21 sat. Both twins showed identical patterns. The family was informative for blood groups Rh and MNSS, the father being cde/cde and NNss, and the mother CDe/CDe and MNSs. The twins were both CDe/cde and NN/ss. The twins showed identical patterns with all six of the hypervariable probes tested. Taking into account the prior probability that the twins are monozygotic (1/3) as well as the blood group, cytogenetic, and molecular data, the probability that they are monozygotic is greater than 99%.

X linked probes from the putative Aicardi region, Xp21-22, were used to study X segregation in this family. The mother was found to be heterozygous at three of the loci tested. All four of the children inherited this region from the same maternal X chromosome (data not shown). In spite of having inherited the same maternal X chromosome as the proband, the brother and two sisters are unaffected.

Results of X chromosome inactivation studies in EBV transformed lymphoblastoid cell lines are summarised in fig 2. The *Msp*I/*Hpa*I sites flanking the DXS255 locus are extensively methylated on the active X chromosomes and unmethylated on inactive X chromosomes. Therefore, the M27β probe that binds to this locus can be used to differentiate between the active and inactive X through methylation patterns shown by *Msp*I and its methylation sensitive isoschizomer, *Hpa*II.<sup>14</sup> The patterns are similar in both twins; the unaffected twin shows equal proportions of active and inactive paternally derived X chromosomes while the affected twin shows slight skewing towards inactive. Neither case shows any evidence of exclusive expression of one particular X chromosome. Identical results were observed in cultured skin fibroblasts.

#### Discussion

Phenotypic variations and even discordance for genetic traits have been well documented in monozygotic twins.<sup>18</sup> Several genetic, epigenetic, and environmental factors may account for this phenomenon. Postzygotic mutations with resultant somatic mosaicism probably occur commonly in singletons.<sup>19</sup> In twins, a

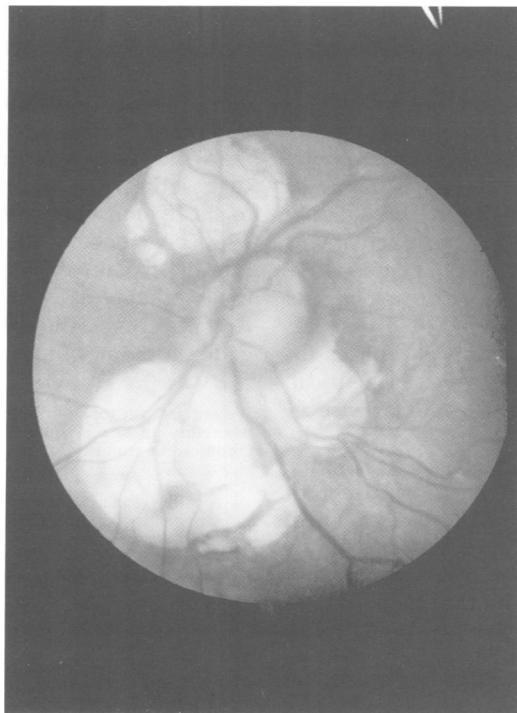
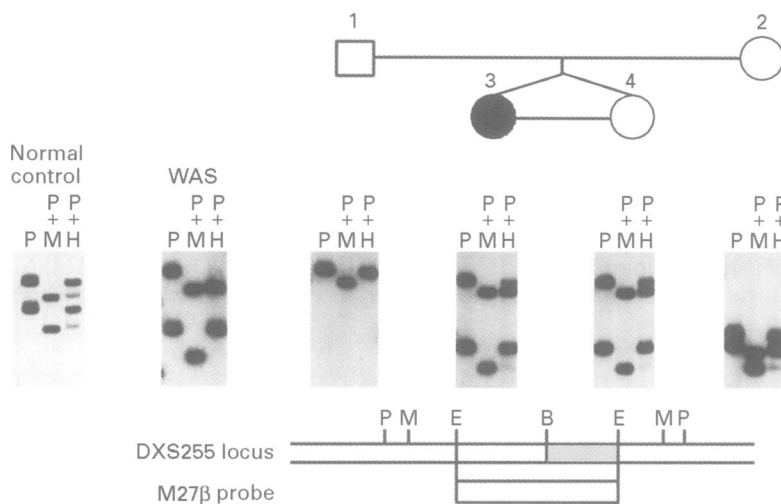


Figure 1 Retinal findings in the proband (left eye).



**Figure 2** RFLP methylation analysis using the probe M27 $\beta$  is shown for the Aicardi kindred, an obligate carrier of Wiskott-Aldrich syndrome, and a normal female control subject. X chromosome inactivation patterns are shown below the corresponding family members. DNA samples from EBV transformed B cells were digested with PstI (P), PstI plus MspI (M), or PstI plus HpaII (H). Heterozygosity was detected in all females upon digestion with PstI. Further digestion with HpaII reduced the size of only a portion of each band in the normal control. By contrast, the obligate carrier of Wiskott-Aldrich syndrome, who is known to exhibit non-random X inactivation in lymphoid cells,<sup>35</sup> shows the upper band remaining undigested, and the lower band completely digested. None of the females in this pedigree show non-random restriction patterns like that of the Wiskott-Aldrich syndrome carrier. A restriction map of the DXS255 locus is shown at the bottom, indicating the region of M27 $\beta$  hybridisation. The shaded area represents a polymorphic repeat segment in which the number of repeats varies from chromosome to chromosome. Restriction sites are indicated: PstI (P), MspI (M), EcoRI (E), and BamHI (B).

postzygotic mutation after cleavage would be expected to lead to complete discordance, while mutation occurring before or during the twinning process could lead to variable degrees of mosaicism and differing phenotypes. Surprisingly, to date, mosaicism has only been documented in one twin pair which was discordant for facioscapulohumeral muscular dystrophy (FSHD) and showed different digestion patterns at a restriction site within the FSHD gene.<sup>20</sup> Another possible cause of discordance, at least in female pairs, is skewed X inactivation, with one twin showing preferential expression of one X chromosome and the other twin showing expression of the other X chromosome. There are now several well documented examples of this phenomenon occurring in a variety of X linked disorders including Duchenne muscular dystrophy,<sup>21</sup> red-green colour blindness,<sup>22</sup> Hunter disease,<sup>23</sup> and fragile X syndrome.<sup>24</sup> In the family described here, studies using peripheral lymphocytes showed random X inactivation.<sup>25</sup> Since the twins had shared a single placenta with a high likelihood of vascular connections,<sup>26</sup> we obtained skin fibroblasts for further studies. The results were identical. This, of course, does not rule out skewed X inactivation in the central nervous system, the tissue primarily involved in Aicardi syndrome, since different tissues might show different patterns of X inactivation.<sup>27</sup> However, the most likely explanation for the findings in this family is a mitotic mutation in the affected girl after twinning. Alternately the mutation could have occurred before or during twinning with unequal allocation of mutated cells to the two embryos. The last scenario raises the possibility that the unaffected twin might have a small proportion of cells with the mutation and

might therefore be at risk for having an affected child. Accordingly the elucidation of the molecular basis for Aicardi syndrome will be invaluable in counselling this young woman about her reproductive options.

The relevance of X inactivation studies in the twins reported here depends on the validity of the hypothesis that the disease is X linked. The evidence for this, in fact, is not compelling. In females heterozygous for some X linked disorders, selection against or favouring the mutation will lead to apparent skewing of X inactivation, as has been shown for incontinentia pigmenti.<sup>28</sup> The results of X inactivation studies in Aicardi syndrome have been inconclusive. Of the nine cases investigated to date, the twin described here and eight unrelated singletons,<sup>29,30</sup> only three were shown to have non-random inactivation. Furthermore, the inactivation pattern correlated poorly with the phenotype.<sup>30</sup> Chromosome studies similarly have not been very fruitful. There is a striking paucity of karyotypically abnormal girls with the syndrome. The only two cases reported had atypical findings. One patient with an X;3 translocation had agenesis of the corpus callosum, vertebral anomalies, and right microphthalmia.<sup>4</sup> However, the fundoscopic findings were atypical. There were clumps of retinal pigment and pin head sized whitish areas but no large depigmented lacunae. This picture is strikingly similar to that reported by Donnenfeld *et al*<sup>31</sup> in a girl with Xp22-pter who initially had been described as having Aicardi syndrome but, on further review, was judged not to meet the diagnostic criteria for Aicardi syndrome.<sup>32</sup> The phenotype described for several other cases of deletion Xp22 appears to be a distinct syndrome, labelled by some authors as MLS or MIDAS syndrome.<sup>33</sup> The disorder is characterised by microphthalmia and linear skin defects. Some affected children have had agenesis of the corpus callosum and chorioretinal lesions, but none has had the typical stigmata of Aicardi syndrome. MLS may well be a contiguous gene syndrome encompassing the Aicardi gene, but the differences in ophthalmological presentation may indicate that the two disorders are unrelated. We suggest that the assignment of the Aicardi locus to the X chromosome therefore is premature. The occurrence of the disorder in females can also be explained by an autosomal gene with male lethality as argued by Migeon *et al*<sup>34</sup> for Rett syndrome. Future searches for the Aicardi gene should not focus solely on Xp22.

We are grateful to Dr I Teshima, director of the cytogenetic laboratory at The Hospital for Sick Children, for doing the chromosome studies.

- 1 Aicardi J, Lefevre J, Lericque-Koechlin A. A new syndrome: spasms in flexion, callosal agenesis, ocular abnormalities. *Electroencephalogr Clin Neurophysiol Suppl* 1965;19:609-10.
- 2 Chevre JJ, Aicardi J. The Aicardi syndrome. In: Pedley TA, Meldrum BS, eds. *Recent advances in epilepsy*. Vol 13. Edinburgh: Churchill Livingstone, 1986:189-210.
- 3 Hopkins IJ, Humphrey I, Keith CG, *et al*. The Aicardi syndrome in a 47,XXY male. *Aust Paediatr J* 1979;15:278-80.
- 4 Ropers HH, Zuffardi O, Bianchi E, Tiepolo L. Agenesis of the corpus callosum, ocular, and skeletal anomalies (X-linked dominant Aicardi's syndrome) in a girl with balanced X/3 translocation. *Hum Genet* 1982;61:264-8.
- 5 Molina JA, Mateos F, Merino M, *et al*. Aicardi syndrome in two sisters. *J Pediatr* 1989;115:282-3.

- 6 Musumeci E, Baciocco A, Barogi G, Calderazzo L, Calvani M. Sindrome di Aicardi con deficit dell'immunità cellulo-mediata. *Minerva Pediatr* 1981;33:95-9.
- 7 Yamamoto N, Watanabe K, Negoro T, et al. Aicardi syndrome. Report of 6 cases and a review of Japanese literature. *Brain Dev* 1985;7:443-9.
- 8 Pavari E, Galluzzi F, LaCauza C, Frosini R. La sindrome di Aicardi. *Minerva Pediatr* 1979;31:863-8.
- 9 Constand WH, Wagner RS, Caputo AR. Aicardi syndrome in one dizygotic twin. *Pediatrics* 1985;76:450-3.
- 10 Menezes AV, MacGregor DI, Buncic JR. Aicardi syndrome: natural history and possible predictors of severity. *Pediatr Neurol* 1994;11:313-18.
- 11 Southern EM. Detection of specific sequences among DNA fragments separated by gel electrophoresis. *J Mol Biol* 1975;98:503-17.
- 12 Reeders S, Breuning MH, Davies KE, et al. A highly polymorphic DNA marker linked to adult polycystic kidney disease on chromosome 16. *Nature* 1985;317:542-4.
- 13 Nakamura Y, Leppert M, O'Connell P, et al. Variable number of tandem repeats (VNTR): markers for human gene mapping. *Science* 1987;235:1616-22.
- 14 Fraser N, Boyd Y, Brownlee G, Craig JW. Multi-allelic RFLP for M27 $\beta$  an anonymous single copy genomic clone at Xp11/3-X cen. *Nucleic Acids Res* 1987;15:9616.
- 15 Boyd Y, Buckle V, Holt S, Munro E, Hunter D, Craig I. Muscular dystrophy in girls with X<sub>1</sub>autosome translocations. *J Med Genet* 1986;23:484-90.
- 16 Gillard E, Affara NA, Yates JR, et al. Deletion of a DNA sequence in eight of 9 families with X-linked ichthyosis (steroid suphatase deficiency). *Nucleic Acids Res* 1987;15:3977-85.
- 17 Thompson MW, Ray PN, Belfall B, Duff C, Logan C, Oss I, Worton RG. Linkage analysis of polymorphisms within the DNA fragment XJ, cloned from the breakpoint of an X;21 translocation associated with X linked muscular dystrophy. *J Med Genet* 1986;23:548-56.
- 18 Machin GA. Some causes of genotypic and phenotypic discordance in monozygotic twin pairs. *Am J Med Genet* 1996;61:216-28.
- 19 Hall JG. Somatic mosaicism: observations related to clinical genetics. *Am J Hum Genet* 1988;43:355-63.
- 20 Tawil R, Storvick D, Weiffenbach R, Altherr MR, Fasby TE, Griggs RC. Chromosome 4q DNA rearrangement in monozygotic twins discordant for facioscapulohumeral muscular dystrophy. *Hum Mutat* 1993;2:492-4.
- 21 Richards CS, Watkins SC, Hoffman EP, et al. Skewed X inactivation in a female MZ twin results in Duchenne muscular dystrophy. *Am J Hum Genet* 1990;46:672-81.
- 22 Jorgensen A, Philip J, Christensen B, Rashind W, Matsushita M, Motulsky A. Opposite patterns of X-inactivation in MZ twins discordant for red-green color deficiency. *Am J Hum Genet* 1992;51:291-8.
- 23 Winchester B, Young E, Geddes S, et al. Female twin with Hunter disease due to non-random inactivation of the X-chromosome. *Am J Med Genet* 1992;44:834-8.
- 24 Kruyer H, Mila M, Glover G, Carbonell P, Ballestra F, Estivill X. Fragile X syndrome and the (CGG) in mutation: two families with discordant MZ twins. *Am J Hum Genet* 1994;54:437-42.
- 25 Costa T, Greer W, Duckworth-Rysiecki G, Musarella M, Ray P. Monozygotic twins discordant for Aicardi syndrome. *Am J Hum Genet* 1990;47:A53.
- 26 Robertson EG, Neerk KJ. Placental injection studies in twin gestation. *Am J Obstet Gynecol* 1988;147:170-4.
- 27 Tan S, Williams EA, Tam PPL. X-chromosome inactivation occurs at different times in different tissues of the post-implantation mouse embryo. *Nat Genet* 1993;3:170-4.
- 28 Migeon BR, Axelman J, de Beur SJ, Valle D, Mitchell G, Rosenbaum KN. Selection against lethal alleles in females heterozygous for incontinentia pigmenti. *Am J Hum Genet* 1989;44:100-6.
- 29 Wieacker P, Zimmer J, Ropers HH. X inactivation patterns in two syndromes with probable X-linked dominant, male lethal inheritance. *Clin Genet* 1985;28:238-42.
- 30 Neidich JA, Nussbaum RL, Packer RJ, Emanuel BS, Puck JM. Heterogeneity of clinical severity and molecular lesions in Aicardi syndrome. *J Pediatr* 1990;116:911-17.
- 31 Donnenfeld AE, Graham JM, Packer RJ, Aquino R, Berg SZ, Emanuel BS. Microphthalmia and chorioretinal lesions in a girl with an Xp22.2-pter deletion and partial 3p trisomy: clinical observations relevant to Aicardi gene localization. *Am J Med Genet* 1990;37:182-6.
- 32 Neidich JA, Nussbaum RL, Packer R, et al. Heterogeneity in clinical severity and molecular lesions in Aicardi syndrome. *Am J Hum Genet* 1988;43:A91.
- 33 Bird LM, Krous HF, Eichenfield LF, Savalwell CI, Jones MC. Female infant with oncocyctic cardiomyopathy and microphthalmia with linear skin defects (MLS). *Am J Med Genet* 1994;53:141-8.
- 34 Migeon BR, Dunn MA, Thomas G, Schmeckpeper BJ, Naid S. Studies of X inactivation and isodisomy in twins provide further evidence that the X chromosome is not involved in Rett syndrome. *Am J Hum Genet* 1995;56:647-53.
- 35 Greer WL, Kwong PC, Peacocke M, Ip P, Rubin LA, Siminovitich KA. X-chromosome inactivation in the Wiskott-Aldrich syndrome: a marker for detection of the carrier state and identification of cell lineages expressing the gene defect. *Genomics* 1989;4:60-7.