

LETTERS TO THE EDITOR

Homozygosity for Asn86Ser mutation in the CuZn-superoxide dismutase gene produces a severe clinical phenotype in a juvenile onset case of familial amyotrophic lateral sclerosis

A 13 year 9 month old girl, the daughter of consanguineous (first cousin) Pakistani parents, presented with pain in her right calf of two months duration and increasing weakness in her right leg with an inability to bear weight. Neurological deficit was initially confined to the right lower limb. Examination showed an asymmetrical lower motor neurone pattern with distal hypotonia and weakness, wasting in the right quadriceps and peroneal muscles, and absent reflexes and flexor plantar responses. After one week of inpatient observation muscle weakness progressed and lower amplitude compound muscle potentials were also seen in the upper limb, confirming an ascending picture of disease progression. The muscle weakness extended to involve facial muscles with definite weakness distally in the right upper limb and profound weakness in the lower limbs. Further progression led to reduced expiratory air flow and pneumonia with respiratory failure and death 14 weeks after presentation.

The predominant clinical features in this patient were progressive asymmetrical lower motor neurone weakness and wasting with more marked involvement of lower limbs and distal musculature, together with bulbar involvement. A paternal uncle had also recently died, aged 34, following an 11 month illness with rapidly progressive motor neurone disease with initial spastic features and later a flaccid symmetrical pattern. These observations suggested a diagnosis of familial motor neurone disease of the progressive muscular atrophy type.

Blood samples were collected from this patient, her parents, her paternal grandmother, and a paternal aunt and uncle. Genomic DNA was isolated and screened for mutations in the superoxide dismutase (SOD1) gene by PCR amplification, single strand conformation polymorphism analysis, and DNA sequencing. An aberrant band shift was identified in amplified DNA in exon 4 of the SOD1 gene. The amplified DNA was sequenced and a single base change was identified (nucleotide 257A→G) causing an amino acid change of asparagine (Asn) (AAT) to serine (Ser) (AGT) at codon 86. The proband was homozygous for this mutation, both of her parents (III.1, III.2) (fig 1), and her paternal uncle (III.7) were heterozygous, while her aunt (III.4) and grandmother (II.4) were homozygous for the normal allele.

In order to check that this sequence change was not a harmless polymorphism, 67

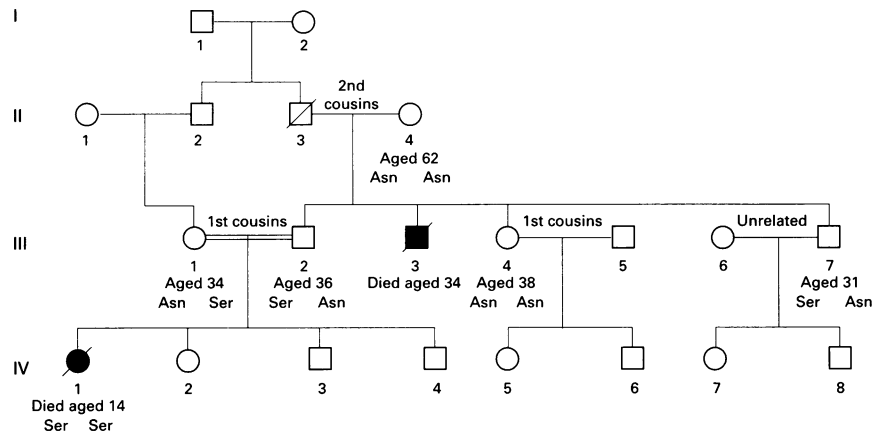


Figure 1 Pedigree of family segregating the Asn86Ser mutation. Members with ALS are represented by solid symbols. Age and Asn86Ser status are shown beneath the symbols.

Scottish amyotrophic lateral sclerosis (ALS) patients, 60 anonymous Scottish controls, and 84 anonymous healthy Pakistani controls were also analysed using allele specific oligonucleotides and dot blot hybridisation. All were homozygous for the normal allele at codon 86. This codon is extremely well conserved throughout the animal and plant kingdom, specifying Asn in 54 different species in the EMBL-SWISS-PROT alignment database.¹ This fact alone implies that this amino acid is functionally important.

The family described here is extensive with many first cousin marriages and potentially many heterozygotes or homozygotes for this mutation. To date two people have died of ALS. The proband was homozygous for the mutation Asn86Ser, while her paternal uncle was probably heterozygous (fig 1). The other heterozygotes in this family appear to be clinically healthy. Therefore, at present, it is not possible to predict the ALS risk factor associated with heterozygosity of Asn86Ser. Recently, a Japanese family with two affected members heterozygous for the Asn86Ser mutation has been reported.² The clinical phenotypes of these two subjects were very different.³ The father died of respiratory failure at the age of 56 years, four years after onset of symptoms but with only upper body involvement. His daughter, diagnosed at the age of 36 years with lower limb weakness and slow progression of the disease to a general muscular atrophy nine years after onset of the first symptoms, survived for more than 11 years.

There has only been one previous report of homozygosity for a SOD1 mutation in ALS. An autosomal recessive form of FALS in a Swedish/Finnish population has been described in nine families.⁴ Homozygosity for the Asp90Ala mutation caused ALS in 30/37 subjects identified. There have been no reports of heterozygosity for the mutation associated with ALS in this population. However, the heterozygous form of the same mutation identified in Belgian subjects has led to the development of ALS.⁵

The clinical phenotype associated with a given mutation in the SOD1 gene is clearly not only dependent on the mutation itself, but may also be influenced by the genetic background of the patient, and possibly by environmental factors. The Asn86Ser mutation has only been identified in a small number of people as yet. In our Pakistani family there were two patients with ALS. The proband was homozygous for Asn86Ser and had a more severe form of disease than her uncle, who was probably heterozygous. Along

with the possible complication of variable penetrance, the true relationship between this mutation and ALS may not be discovered for some time.

CAROLINE HAYWARD
DAVID J H BROCK

Human Genetics Unit, Molecular Medicine Centre,
University of Edinburgh, Western General Hospital,
Edinburgh EH4 2XU, UK

ROBERT A MINNS
Department of Paediatric Neurology, Royal Hospital
for Sick Children, Edinburgh EH9 1LF, UK

ROBERT J SWINGLER
Department of Neurology, Dundee Royal Infirmary,
Dundee DD1 9ND, UK

- Bairoch A, Apweiler R. The SWISS-PROT protein sequence data bank and its new supplement TrEMBL. *Nucleic Acids Res* 1996;24:21-5.
- Radunovic A, Leigh PN. Cu/Zn superoxide dismutase gene mutations in amyotrophic lateral sclerosis: correlation between genotype and clinical features. *J Neurol Neurosurg Psychiatry* 1996;61:565-72.
- Kurahashi K, Okushima T, Kimura K, Narita S, Matsunaga M. Different phenotype and clinical course in a family with motor neurone disease. *Med J Aomori* 1993;38:142-6.
- Anderson PM, Nilsson P, Ala-Hurala V, et al. Amyotrophic lateral sclerosis associated with homozygosity for an Asp90Ala mutation in Cu/Zn superoxide dismutase. *Nat Genet* 1995; 10:61-6.
- Anderson PM, Forsgren L, Binzer M, et al. Autosomal recessive adult-onset amyotrophic lateral sclerosis associated with homozygosity for Asp90Ala CuZn-superoxide dismutase mutation. A clinical and genealogical study of 36 patients. *Brain* 1996;119:1153-72.
- Robberecht W, Aguirre T, Van den Bosch L, Tilkin P, Cassiman JJ, Matthijs G. D90A heterozygosity in the SOD1 gene is associated with familial and apparently sporadic amyotrophic lateral sclerosis. *Neurology* 1996;47: 1336-9.

RP11 is the second most common locus for dominant retinitis pigmentosa

Autosomal dominant retinitis pigmentosa (ADRP), an inherited retinal degeneration, is caused by mutations in two known genes, rhodopsin and peripherin/RDS, and seven loci identified only by linkage analysis, on chromosomes 1cen, 7p, 7q, 8q, 17p, 17q, and 19q. This high level of locus heterogeneity

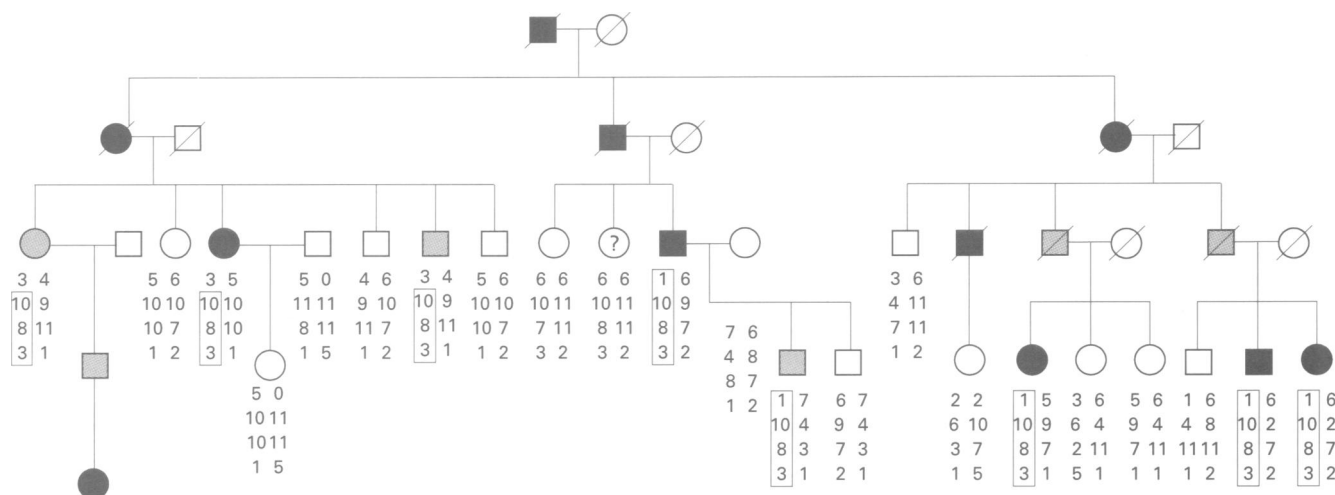


Figure 1 New RP11 linked UK family with haplotypes for 19q13.4 markers shown beneath. Alleles are for, from top to bottom, D19S921, D19S572, D19S927, and D19S924. Filled symbols represent affected subjects and shaded symbols represent gene carriers. Lod scores were calculated with these subjects marked as unaffected, but with penetrance set at 0.7. The symbol containing a question mark represents a subject in whom there has been a crossover between D19S921 and the more distal markers. This crossover makes it impossible to determine genetically whether she is a gene carrier or is normal. Analysis of this patient could potentially have refined the locus further, but it is not possible to distinguish carriers from normal subjects in the clinic beyond doubt.

poses considerable difficulties to any laboratory proposing to undertake genetic counseling in dominant RP families. We recently described four families with dominant RP which mapped to the RP11 locus on 19q.¹ Locus refinement based on linkage analysis in these families placed the RP11 gene between D19S180 and D19S926, and though inheritance was clearly dominant, each pedigree was noted to include non-expressing carriers. Of a total of 20 large ADRP pedigrees analysed in our laboratory at that time, 20% were therefore shown to map to the RP11 locus, a frequency second only to the rhodopsin locus, which in this data set accounted for approximately 50%.² This observed high frequency for the RP11 locus was further substantiated by a report of a Japanese RP11 family, also with variable penetrance.³

We have now tested for linkage to 19q markers in three new UK pedigrees and a family of Spanish origin. This led to the identification of one further RP11 linked UK family, shown in fig 1. Multipoint analysis with markers D19S572, D19S927, and D19S924, all mapping within the interval for the RP11 gene, gave a maximum multipoint

lod score of 4.38 at D19S924/927. A new proximal crossover in this family, together with a change in the published Genethon marker order, further refines the RP11 locus to within the interval D19S921-D19S418, with markers D19S572, D19S927, and D19S924 showing no crossovers with the RP phenotype in affected subjects (fig 2). Once again unaffected family members could not be included in the haplotype analysis since the family includes several carriers who show no symptoms. The linked haplotype in this family is unique, indicating that it is unrelated to other UK 19q linked families. Our frequency estimate for RP11 as a proportion of all ADRP is therefore still approximately 20%, but with increased significance resulting from a slightly larger sample size. We also note with interest that McGee *et al*⁴ reported an additional three RP11 linked families from the USA, once again with reduced penetrance. This brings to a total of nine the number of published RP11 pedigrees, well above the number identified for the six other linked loci. A much larger number of peripherin/RDS mutations have been identified in ADRP patients, but where the gene is known it is possible to identify the causative mutation in the absence of any family structure, so such mutations will inevitably be over-represented. Current estimates of the frequency of peripherin/RDS mutations as a cause of ADRP are less than 5%.⁵⁻⁶

These data therefore further refine the RP11 locus. They also serve to underline the conclusions of our previous study, namely that 19q13.4 is the site for a major locus for dominant RP, probably the second most common after rhodopsin, and that partial penetrance is a consistent observation in families with this form of RP. An investigation of the mechanism of variation in severity of the disease phenotype in these families could have important implications in the search for a cure for RP. In the mean time, analysis of a new ADRP family should begin by determining the level of penetrance. A fully penetrant phenotype implicates rhodopsin as the most likely site for mutations, which could then be screened for by strategies we described in a previous letter to the Journal.⁷ Evidence of non-penetrance would suggest the RP11 locus. Though the 7p and 8q ADRP loci do also exhibit variation in severity of disease,^{8,9}

it is increasingly evident that the locus on 19q13.4 is more common, both in the UK and in other populations.

We gratefully acknowledge the Wellcome Trust (grant numbers 043006/Z/94, 042375/Z/94, and 035535/Z/92) for funding.

ERANGA VITHANA
MAI AL-MAGHTHEH
SHOMI S BHATTACHARYA
CHRIS F INGLEHEARN*

Department of Molecular Genetics, Institute of Ophthalmology, University College London, London, UK

*Present address: Molecular Medicine Unit, Clinical Sciences Building, St James's University Hospital, Leeds LS29 7TF, UK

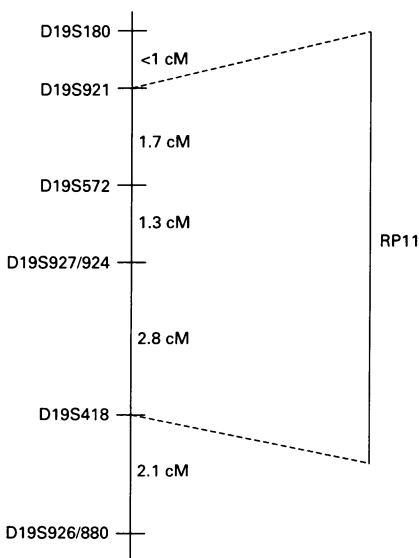


Figure 2 The RP11 locus and surrounding markers.

- Al-Magtheth M, Vithana E, Tarttelin EE, *et al*. Evidence for a major retinitis pigmentosa locus on 19q13.4 (RP11) and association with a unique bimodal expressivity phenotype. *Am J Hum Genet* 1996;59:864-71.
- Inglehearn CF, Tarttelin EE, Plant C, *et al*. A linkage survey of 20 dominant retinitis pigmentosa families: frequencies of the nine known loci and evidence for further heterogeneity. *J Med Genet* 1998;35:1-5.
- Xu S, Nakazawa M, Tamai M, Gal A. Autosomal dominant retinitis pigmentosa locus on chromosome 19q in a Japanese family. *J Med Genet* 1995;32:915-16.
- McGee TL, Devoto M, Ott J, Berson TP, Dryja TP. Dominant retinitis pigmentosa with reduced penetrance: refinement of the RP11 locus to a 4.9 cM interval on 19q. *Invest Ophthalmol Vis Sci* 1997;38(suppl):1139.
- Wells J, Wroblewski J, Keen TJ, *et al*. Mutations in the human retinal degeneration slow (RDS) gene can cause either retinitis pigmentosa or macular dystrophy. *Nat Genet* 1993;3:213-18.
- Souied EH, Rozet JM, Gerber S, *et al*. Screening for mutations within the rhodopsin, peripherin-RDS and ROM1 genes in autosomal dominant retinitis pigmentosa (ADRP) in pedigrees from France. *Invest Ophthalmol Vis Sci* 1995;36(suppl):890.
- Tarttelin EE, Al-Magtheth M, Keen TJ, Bhattacharya SS, Inglehearn CF. Simple tests for rhodopsin involvement in retinitis pigmentosa. *J Med Genet* 1996;33:262-3.
- Inglehearn CF, Carter SA, Keen TJ, *et al*. A new locus for autosomal dominant retinitis pigmentosa (adRP) on chromosome 7p. *Nat Genet* 1993;4:51-3.
- Blanton SH, Heckenlively JR, Cottingham AW, *et al*. Linkage mapping of autosomal dominant retinitis pigmentosa (RP1) to the pericentric region of human chromosome 8. *Genomics* 1991;11:857-69.