

geal atresia<sup>13</sup> and renal agenesis and renal dysplasia with von Maeyer-Rokitanski-Küster complex.<sup>14</sup>

As yet, there is no consistent detectable chromosomal or metabolic cause of the 3C syndrome, including the 22q11.2 deletion discussed here. In the 16 families known to have children with the 3C syndrome, four males and 14 females, two had two affected daughters, three are related, and five belong to a small, isolated part of Canada with its own dialect. The most likely aetiology, therefore, is autosomal recessive inheritance, as proposed in the first report of the syndrome. It would be prudent, however, to exclude a deletion in 22q11.2 before a definitive diagnosis of 3C syndrome is made owing to possible overlap of the variable clinical features.

JORGE M SARAIVA

Consulta de Genética, Hospital Pediátrico de Coimbra,  
Avenida Bissaya Barreto, 3000 Coimbra, Portugal

EUNICE MATOSO

ISABEL MARQUES

Unidade de Citogenética e Diagnóstico Pré-natal,  
Instituto de Biologia Médica, Faculdade de Medicina  
de Coimbra, Portugal

- Butler MG, Mowrey P. Should the 3C (cranio-cerebellocardiac) syndrome be included in the spectrum of velocardiofacial syndrome and DiGeorge sequence? *J Med Genet* 1996;33:719-20.
- Saraiva JM, Gama E, Pires MM, Sequeira JF. First report of glaucoma as a feature of the 3C syndrome. *Clin Dysmorphol* 1995;4:156-60.
- McKusick VA. *Mendelian inheritance in man: catalogs of autosomal dominant, autosomal recessive and X-linked phenotypes*. 11th ed. Baltimore: The Johns Hopkins University Press, 1994.
- Digilio MC, Marino B, Giannotti A, Mingarelli R, Dallapiccola B. Atrioventricular canal and 3C (cranio-cerebello-cardiac) syndrome. *Am J Med Genet* 1995;58:97-8.
- Marles SL, Chodirker BN, Greenberg CR, Chudley AE. Evidence for Ritscher-Schinzel syndrome in Canadian native Indians. *Am J Med Genet* 1995;56:343-50.
- Wulfsberg EA, Leana-Cox J, Neri G. What's in a name? Chromosome 22q abnormalities and the DiGeorge, velocardiofacial, and conotruncal anomalies face syndromes. *Am J Med Genet* 1996;65:317-19.
- Lynch DR, McDonald-McGinn DM, Zackai EH, et al. Cerebellar atrophy in a patient with velocardiofacial syndrome. *J Med Genet* 1995;32:561-3.
- Goldberg R, Motzkin B, Marion R, Scambler PJ, Shprintzen RJ. Velo-cardio-facial syndrome: a review of 120 patients. *Am J Med Genet* 1993;45:313-19.
- Wilson DI, Burn J, Scambler P, Goodship J. DiGeorge syndrome - part of CATCH 22. *J Med Genet* 1993;30:852-6.
- Lauener R, Seger R, Jörg W, Hallé F, Aeppli R, Schinzel A. Immunodeficiency associated with Dandy-Walker-like malformation, congenital heart defect, and craniofacial abnormalities. *Am J Med Genet* 1989;33:280-1.
- Devriendt K, van Thienen MN, Swillen A, Fryns JP. Cerebellar hypoplasia in a patient with velo-cardio-facial syndrome. *Dev Med Child Neurol* 1996;38:949-53.
- Hoo JJ, Kreiter M, Halverson N, Perszyk A. 3C (cranio-cerebello-cardiac) syndrome - a recently delineated and easily recognizable congenital malformation syndrome. *Am J Med Genet* 1994;52:66-9.
- Fokstuen S, Bottani A, Medeiros PFV, Antonarakis SE, Stoll C, Schinzel A. Laryngeal atresia type III (glottic web) with 22q11.2 microdeletion: report of three patients. *Am J Med Genet* 1997;70:130-3.
- Devriendt K, Moerman P, van Schoubroeck D, Vandenberghe K, Fryns JP. Chromosome 22q11 deletion presenting as the Potter sequence. *J Med Genet* 1997;34:423-5.

## A mother with VCFS and unilateral dysplastic kidney and her fetus with multicystic dysplastic kidneys: additional evidence to support the association of renal malformations and VCFS

Devriendt *et al* recently described in this journal a female fetus with Potter sequence caused by unilateral renal agenesis and contralateral multicystic renal dysplasia, who was retrospectively found to have a deletion in chromosome 22q11 following identification of the deletion in the father. The father presented with typical VCFS features but no urological anomalies. We describe a patient with a clinical diagnosis of VCFS and a unilateral dysplastic kidney but with negative high resolution cytogenetic and FISH studies, who had a female fetus with bilateral multicystic kidneys. This provides additional evidence to support the conclusion of Devriendt *et al* that in VCFS the renal malformation can dominate the clinical phenotype.

Our patient is a 24 year old female initially referred because of facial dysmorphism and developmental delay. She had a long nose and a long, thin face, a small chin, prominent incisors, a deep philtrum (fig 1), a high palate which had the appearance of a cleft, velopharyngeal insufficiency, and long, thin fingers and toes. She also had a repaired ASD, developmental and speech delay, depression, chemical dependency, and seizures. A renal ultrasound showed a unilateral multicystic dysplastic kidney. Karyotype analysis and FISH using a digoxigenin labelled probe localised to 22q11.2 (Oncor Inc, Gaithersburg, MD) were negative. Her first pregnancy was uncomplicated and she delivered a healthy male with no dysmorphic features. He had a normal renal ultrasound and at the age of 2 years is developmentally appropriate. During her second pregnancy, ultrasound examination of her female fetus at 19 weeks 4 days identified bilateral multicystic kidneys

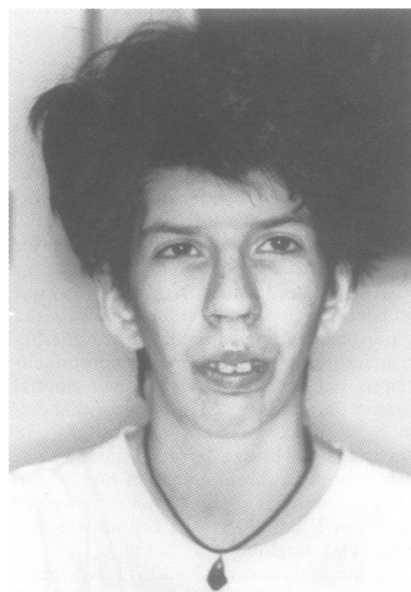


Figure 1 Patient with long nose, long, thin face, small chin, prominent incisors, and deep philtrum.

and anhydramnios. The pregnancy was terminated and necropsy confirmed the presence of multicystic dysplastic kidneys, hypoplastic bladder, and low set ears. No other abnormalities were noted. Karyotype analysis was normal.

Of patients diagnosed clinically with VCFS, only 68 to 81% have a deletion of 22q11.2.<sup>2,3</sup> Several recent articles have noted the presence of nephrourological malformations as a component of VCFS syndrome.<sup>4,7</sup> Of the 39 patients reported by Devriendt *et al* with 22q11 deletions, four had nephrourological malformations. Another patient with unilateral renal agenesis and dysmorphic features suggestive of DiGeorge sequence had a normal G banded karyotype.<sup>4</sup> Driscoll *et al* reported a patient with a multicystic kidney and a normal karyotype; however, molecular studies showed the absence of a paternal 22q11 allele. Of 11 patients with DiGeorge syndrome reported by Palacios *et al*,<sup>7</sup> one had a dysplastic right kidney and left ureterohydronephrosis and one had a right megaureter; karyotype analysis was not performed on these two patients.

We concur with Devriendt *et al* that renal malformations associated with VCFS can lead to the Potter sequence and can dominate the clinical phenotype. These authors retrospectively investigated 10 additional cases of Potter sequence and no other patient with a del(22q11) was found. The possibility of performing FISH for 22q11.2 on all fetuses with Potter sequence, along with a thorough evaluation of both parents for physical features of VCFS, needs to be examined further.

PAULA M CZARNECKI

DANIEL L VAN DYKE

SUBODH VATS

GERALD L FELDMAN

Department of Medical Genetics, Henry Ford Hospital,  
2799 W Grand Blvd, CFP-4, Detroit, Michigan  
48202, USA

- Devriendt K, Moerman P, Van Schoubroeck D, et al. Chromosome 22q11 deletion presenting as the Potter sequence. *J Med Genet* 1997;34:423-5.
- Driscoll DA, Salvin J, Sellinger B, et al. Prevalence of 22q11 microdeletions in DiGeorge and velocardiofacial syndromes: implications for genetic counselling and prenatal diagnosis. *J Med Genet* 1993;30:813-17.
- Lindsay EA, Greenberg F, Schaffer LG, et al. Velo-cardio-facial syndrome: frequency and extent of 22q11 deletions. *Am J Med Genet* 1995;56:191-7.
- Baldellou A, Bone J, Tamparillas M, et al. Congenital hypoparathyroidism, ocular colobomata, unilateral renal agenesis and dysmorphic features. *Genet Couns* 1991;2:245-7.
- Devriendt K, Swillen A, Fryns JP, et al. Renal and urological tract malformations caused by a 22q11 deletion. *J Med Genet* 1996;33:349.
- Driscoll DA, Budarf ML, Emanuel BS. A genetic etiology for DiGeorge syndrome: consistent deletions and microdeletions of 22q11. *Am J Hum Genet* 1992;50:924-33.
- Palacios J, Gamallo C, Garcia M, Rodriguez JJ. Decrease in thyrocalcitonin-containing cells and analysis of other congenital anomalies in 11 patients with DiGeorge anomaly. *Am J Med Genet* 1993;46:641-6.

## New overgrowth syndrome and FGFR3 dosage effect

The 4p16 chromosome band is the object of intense scrutiny because the region is known to be genetically dense,<sup>1</sup> containing many genes responsible for well known disorders such as the HD gene,<sup>2</sup> FGFR3,<sup>3</sup> and the Wolf-Hirschhorn critical region.<sup>4</sup> More recently, the question has been raised whether