

Short reports

Autosomal dominant juvenile recurrent parotitis

Evan Reid, Fiona Douglas, Yanick Crow, Anne Hollman, John Gibson

Abstract

Juvenile recurrent parotitis is a common cause of inflammatory salivary gland swelling in children. A variety of aetiological factors has been proposed for the condition. Here we present a family where four members had juvenile recurrent parotitis and where two other family members may have had an atypical form of the condition. The segregation pattern in the family is consistent with autosomal dominant inheritance with incomplete penetrance and this suggests that, at least in some cases, genetic factors may be implicated in juvenile recurrent parotitis.

(*J Med Genet* 1998;35:417-419)

Keywords: juvenile recurrent parotitis; autosomal dominant

panied by xerostomia. During acute attacks, there was swelling and mild erythema of the right side of the face over the region of the parotid gland. As commonly occurs in JRP, the number of episodes of gland swelling started to lessen with the onset of puberty. Each acute episode was managed with bed rest, adequate hydration, and drug therapy (potent oral analgesics and antibiotics). Her general health was otherwise good, she was taking no medications, and had no known allergies.

On examination between attacks, there was no residual salivary gland swelling and there was no tenderness around the head or neck. A painless temporomandibular joint click was present on wide mouth opening. There was no trismus and the teeth were not tender to percussion. The oral mucosa had a normal appearance. Minimal saliva could be expressed from the right parotid duct orifice, but clear saliva could easily be expressed from the other three major salivary gland ducts. A clinical diagnosis of JRP was made. This diagnosis was strengthened by parotid gland ultrasonography, which showed the right parotid gland to be enlarged, with areas of altered texture and flecks of calcification. A technetium scan showed normal tracer activity in both parotid glands, but discharge of tracer activity following lemon juice was poor, strongly suggesting chronic parotid disease. A panoramic radiograph was normal and a sialogram was unhelpful, owing to artefact resulting from high pressure filling. MRI scanning of salivary glands was normal, as is occasionally found in JRP. Tests for anti-Ro, -La, -nuclear factor and rheumatoid factor autoantibodies were negative, as was radioimmunosorbant testing for IgE against numerous antigens.

The proband's mother denied ever having experienced attacks of facial pain or salivary gland swelling.

Juvenile recurrent parotitis (JRP) is a common cause of inflammatory salivary gland swelling in children.¹⁻³ The condition is characterised by episodes of usually unilateral, painful parotid swelling, which typically last for several days and which may occur more than 10 times per year. Age of onset is most commonly between 3 and 6 years, while remission is usual at the time of puberty.¹⁻³

A variety of aetiological factors have been proposed for JRP, including allergy,³ viral infection,⁴ autoimmunity,⁵ and congenital structural defects.⁶ Here, we describe clinical and radiological findings in a family where four members in two generations were affected by JRP and where two further family members were affected by what may have been an atypical form of the condition. The pattern of disease segregation in the family is consistent with autosomal dominant inheritance and suggests that genetic factors are important in at least some cases of JRP.

Case reports

The family pedigree is illustrated in fig 1.

CASE 1: PROBAND (IV.1)

The proband presented at the age of 12 years with a five year history of recurrent right sided, painful facial swelling. Attacks occurred approximately three to four times per year, came on over a few hours, and typically lasted for 24 to 48 hours. They were associated with a sensation of unpleasant taste and were accom-

CASE 2 (IV.3)

Case 2 experienced two to three attacks of painful parotid gland swelling per year, beginning at the age of 3 years. Attacks were very similar in character to those of the proband, although facial swelling was more prominent and attacks could occur on either side. Parotid ultrasonography showed bilateral punctate calcification. A panoramic radiograph showed multiple small calculi within the left parotid gland.

Department of
Medical Genetics,
University of
Cambridge, Box 134,
Addenbrooke's NHS
Trust, Cambridge CB2
2QQ, UK
E Reid

Department of Human
Genetics, Royal
Victoria Infirmary,
Newcastle upon Tyne,
UK
F Douglas

Department of
Medical Genetics,
Royal Hospital for Sick
Children, Glasgow, UK
T Crow

Department of
Radiology, Royal
Hospital for Sick
Children, Glasgow, UK
A Hollman

Department of Oral
Medicine, Glasgow
Dental Hospital and
School NHS Trust,
Glasgow, UK
J Gibson

Correspondence to:
Dr Reid.

Received 23 September 1997
Accepted for publication
12 November 1997

CASE 3 (IV.4)

Case 3 had two to three attacks of painful parotid gland swelling per year, involving both sides, from the age of 3 years. Again, the attacks were very similar in character to those described by the proband. Parotid gland ultrasonography showed areas of abnormal texture with punctate calcification in both glands, more prominent on the right, suggestive of chronic inflammatory change. A panoramic radiograph was normal.

CASE 4 (III.4)

The mother of cases 2 and 3 was affected by recurrent, painful parotid gland swelling which was usually unilateral, though occasionally bilateral. Attacks occurred between the ages of 8 and 14 years, after which they spontaneously disappeared. However, the attacks recurred during each of two pregnancies, remitting shortly after delivery. Parotid gland ultrasonography showed areas of abnormal texture with punctate calcification on both sides, with the left side more severely affected. A panoramic radiograph was normal.

CASE 5 (II.1)

Case 5 had experienced recurrent attacks of right submandibular salivary gland swelling 30 years before. Radiographs carried out at the time identified a right submandibular duct

stone. The duct was explored operatively but the stone could not be removed for technical reasons. However, his symptoms settled after this. He was reinvestigated shortly after the proband's presentation and a panoramic radiograph showed a single left submandibular calculus. Ultrasonography showed both parotid glands to be atrophic and abnormal, containing areas of calcification.

CASE 6 (I.2)

Only historical data were available for this case, who died several years before the proband's presentation. Family members recalled her suffering throughout her life from recurrent episodes of unilateral facial pain and swelling.

Discussion

Juvenile recurrent parotitis is the second most common cause of inflammatory salivary gland swelling in children after mumps. Acute episodes are characterised by painful, tender, unilateral or bilateral parotid gland swelling which may last from one to two days to over two weeks. The swelling typically appears suddenly over a period of a few hours and may be accompanied by systemic symptoms, including fever and general malaise. Xerostomia is well recognised during acute episodes and a mucopurulent discharge can often be milked from the parotid duct. The frequency of these acute events may range from one to more than 10 per year. The age of onset is generally between 3 and 6 years, although earlier and later ages of onset have been recorded. In general, the condition tends to become quiescent around puberty, although attacks may persist into adult life.¹⁻³

In our family, the clinical picture was typical of JRP in cases 1-3. Case 4 had a typical clinical picture of JRP during childhood, but also suffered from the condition in adult life, interestingly during each of two pregnancies. Case 5 was not typical of JRP. He had never experienced acute parotitis, but during adult life did have several episodes of right submandibular gland swelling, thought to be caused by ductal obstruction. On reassessment 30 years later, he had a left submandibular gland stone and bilaterally abnormal and atrophic parotid glands, suggesting the presence of previous subclinical parotid disease. No firm diagnosis was possible in case 6, although the historical description of recurrent facial pain and swelling is consistent with recurrent parotitis.

In our patients, ultrasonography was useful for confirming parotid gland pathology and showed gland atrophy, variations in parenchymal texture, and multiple areas of calcification. The majority of cases of JRP show ultrasonographic abnormalities, in particular multiple small hypoechoic areas, although the areas of punctate calcification reported here are highly suggestive of previous inflammatory change within the salivary gland parenchyma.⁷ The radiological investigation of choice for confirmation of a diagnosis of JRP is sialography, and it is unfortunate that the sialogram carried out in case 1 was unhelpful. She has declined repeat sialographic examination.

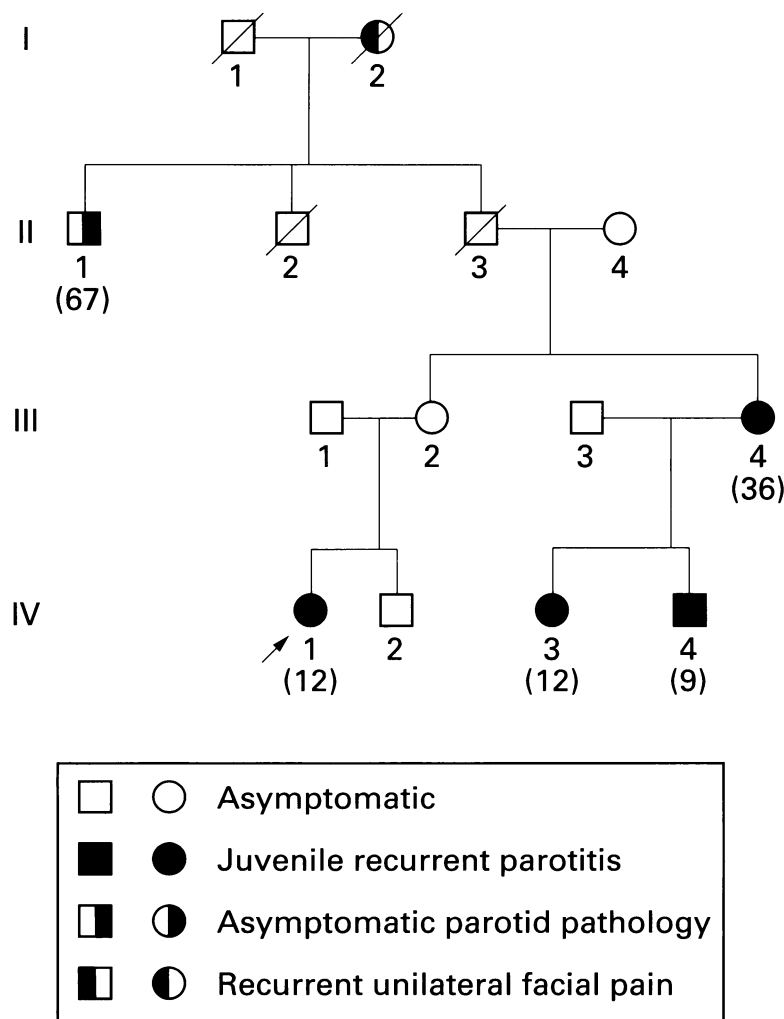


Figure 1 Family pedigree. Age at examination is shown in brackets.

A variety of aetiological factors have been proposed for JRP, including viral infection, autoimmunity, allergy, and ascending infection caused by congenital structural defects.³⁻⁶ Genetic factors have also been suggested to have a role; rarely, families have been described where two sibs were affected, or where members of more than one generation were affected.^{1,6,8} Our family strengthens and extends these observations. At least four family members in two generations (cases 1-4) were affected by JRP, and it is likely that two other family members in a further two generations (cases 5 and 6) had parotid disease, although the clinical picture in these two relatives was atypical of, but did not exclude, JRP. Thus, the transmission pattern in the family is consistent with autosomal dominant inheritance with incomplete penetrance and variable expression. Assuming that I.2 and II.1 were indeed affected, the gene penetrance may be estimated at 75% (6/8), since II.3 and III.2 were asymptomatic. Of course, it is possible that these subjects may have had subclinical disease. The occurrence of chronic or recurrent exocrine gland inflammation with a genetic aetiology is not without precedent, for example, mutations in the cationic trypsinogen gene are responsible for hereditary pancreatitis, a condition where recurrent acute episodes of pancreatitis result in chronic pancreatic exocrine and endocrine insufficiency.⁹ It is tempting to speculate on the nature of the gene which may be responsible for JRP in our family. Salivary enzyme genes, genes coding for structural elements of the pancreatic duct system, or genes involved in aspects of the immune response may be candidates.

The most important differential diagnosis for JRP is Sjögren's syndrome, in which lymphocytic infiltration of the lacrimal and salivary glands leads to keratoconjunctivitis sicca or xerostomia or both.^{10,11} This condition may present with recurrent parotid gland swelling and can closely mimic JRP. It may be associated with the presence of autoantibodies (particularly rheumatoid factor, antinuclear antibodies, anti-Ro antibodies, and anti-La antibodies),¹⁰ although only a proportion of children with autoantibodies and recurrent parotid swelling have Sjögren's syndrome.¹⁰ Clarification of the diagnosis by minor salivary gland biopsy may be considered in such children.

The prognosis in JRP is generally good, with spontaneous resolution usually occurring at adolescence, and so treatment of the condition should be conservative. Remission of acute

attacks may be hastened by the use of sialogogues, gland massage, encouragement of fluid intake, and oral antibiotics.³ More radical treatment is seldom required and is restricted to the severe cases where resolution does not occur. Total parotidectomy is the most effective treatment and is usually curative, although it carries a risk of facial nerve damage.^{3,12} It is contraindicated in children, because of the likelihood of spontaneous remission.¹²

In summary, we report a family where parotid gland disease is segregating in an autosomal dominant fashion. Expression of the disease gene appears variable, with four family members suffering from JRP (cases 1-4), one affected by asymptomatic parotid gland pathology (case 5) and one possibly affected by recurrent parotitis throughout adult life (case 6). The gene penetrance is estimated at 75%.

We thank the family members for allowing us to describe their condition.

Addendum

Parotid gland ultrasonography was carried out on the proband's asymptomatic mother (III.2) after acceptance of this paper. It showed flecks of calcification in the left parotid gland, suggestive of previous inflammatory change and consistent with previous parotitis. It seems likely that she had subclinical disease, widening the phenotypic range observed in the family and indicating that the 75% figure suggested for gene penetrance is an underestimate.

- 1 Jones HE. Recurrent parotitis in children. *Arch Dis Child* 1953;28:182-6.
- 2 Cohen HA, Gross S, Nussinovitch M, et al. Recurrent parotitis. *Arch Dis Child* 1992;67:1036-7.
- 3 Mandel L, Kaynar A. Recurrent parotitis in children. *NY State Dent J* 1995;61:22-5.
- 4 Akaboshi I, Katsuki T, Yamamoto J, et al. Unique pattern of Epstein-Barr virus specific antibodies in recurrent parotitis. *Lancet* 1983;ii:1049-51.
- 5 Friis B, Karu-Pedersen F, Schiodt M, et al. Immunologic studies in two children with recurrent parotitis. *Acta Paediatr Scand* 1983;72:265-8.
- 6 Smith M. Familial incidence of siallectasis. *BMJ* 1953;ii:1359.
- 7 Nozaki H, Harasawa A, Hara H, et al. Ultrasonographic features of recurrent parotitis in childhood. *Pediatr Radiol* 1994;24:98-100.
- 8 Galili D, Marmary Y. Juvenile recurrent parotitis: clinicoradiologic follow-up study and the beneficial effect of sialography. *Oral Surg Oral Med Oral Pathol* 1986;61:550-6.
- 9 Whitcomb DC, Gorry MC, Preston RA, et al. Hereditary pancreatitis is caused by a mutation in the cationic trypsinogen gene. *Nat Genet* 1996;14:141-5.
- 10 Hara T, Nagata M, Mizuno Y, et al. Recurrent parotid swelling in children: clinical features useful for differential diagnosis of Sjögren's syndrome. *Acta Paediatr Scand* 1992;81:547-9.
- 11 Heath-Holmes M, Baethge BA, Abreo F, et al. Autoimmune exocrinopathy presenting as recurrent parotitis of childhood. *Arch Otolaryngol Head Neck Surg* 1993;119:347-9.
- 12 Bowling DM, Rauch SD, Goodman ML. Intraductal tetracycline therapy for the treatment of chronic recurrent parotitis. *ENT J* 1994;73:262-74.