

# Bony orbital morphology in neurofibromatosis type 1 (NF1)

Sue C Kaste, Eniko K Pivnick

## Abstract

**We retrospectively compared patients with NF1 with and without optic pathway gliomas (OPG) to determine the incidence and range of orbital developmental abnormalities and compared the incidence of OPG in African-Americans and whites. From cranial MR scans, we manually measured 14 orbital dimensions, compared them to published standards of Waitzman *et al*, calculated orbital volumes, and determined the presence or absence of volumetric symmetry ( $\Delta v$ ) ( $\Delta v \leq 0.3 \text{ cm}^3$  was considered to be symmetrical). We compared the results of orbital configurational assessment between patients with (group I) and those without OPG (group II). The study population comprised 58 patients, 24 boys, 18 African-American, and one Hispanic. Median age at imaging was 7 years (range 0.5-25.5 years). Fifty-eight percent had conformational abnormalities, 16 of whom had more than one abnormality (28%), the most frequent being increased intertemporal distance (n=10), increased lateral orbital distance (n=8), increased medial wall length (n=6), and decreased medial wall length (n=6). The increased intertemporal and lateral orbital distances may contribute to the appearance of hypertelorism. Only two patients had sphenoid wing hypoplasia. We found a high incidence of orbital dimensional abnormalities in the total population but more often saw multiple abnormalities in patients with OPG. However, no pattern of configurational abnormality emerged. OPG is less frequent in African-Americans. Orbital volumetric disparity seems to be independent of the presence of OPG.**

(*J Med Genet* 1998;35:628-631)

**Keywords:** neurofibromatosis type 1; orbital morphology; MRI

Neurofibromatosis type 1 (NF1) or von Recklinghausen neurofibromatosis is one of the most common autosomal dominant disorders

in man, primarily affecting cells of neural crest origin and resulting in developmental, pigmentary, and neoplastic abnormalities. Developmental defects of the skull and the facial bones are commonly seen in association with NF1 and macrocephaly is the most prevalent and familiar.<sup>1</sup> The most distinctive craniofacial bone dysplasia in NF1 involves the sphenoid wings. Sphenoid wing hypoplasia is almost always unilateral and involves the greater wing of the sphenoid bone. The incidence of sphenoid dysplasia ranges from 4-58% of NF1 patients.<sup>2-6</sup> However, patients with NF1 are known to have other osseous craniofacial aberrations, which include simple skull asymmetry, localised defects of the parietal and occipital bones of various sizes,<sup>7</sup> deformity of the lateral aspect of the sphenoid body, widened middle cranial fossa and sella turcica,<sup>5 8-11</sup> petrous bone dysplasia, enlarged outline of the orbit and frontal dysplasia with lateral enlargement of the frontal sinus as opposed to hypoplasia of the other sinuses,<sup>12 13</sup> maxillary sinus asymmetry,<sup>14</sup> maxillo-zygomatico-temporomandibular hypoplasia, and hypertelorism.<sup>15 16</sup>

To determine the incidence and range of orbital developmental abnormalities of patients with NF1, we retrospectively reviewed cranial MRI in the clinical populations of NF1 patients with and without optic pathway tumours.

## Materials and methods

The study population comprised 58 patients with NF1 (39 whites, one Hispanic, 18 African-American) who had been evaluated at St Jude Children's Research Hospital (SJCRC) or LeBonheur Children's Medical Center (LBCMC) between 1984 and 1997, and for whom cranial MR scans were available for review. The study cohort was drawn from an available population of 255 children with NF1, 55 of whom were African-American.

Orbital volumes and dimensions were manually measured from previously acquired axial cranial MRI studies. We chose a single image through the orbits at the level of the optic nerve and manually measured 14 orbital dimensions based on the published standards by Waitzman *et al*<sup>17</sup> (table 1). We calculated orbital volumes

Diagnostic Imaging, St Jude Children's Research Hospital, Memphis, Tennessee, and Department of Radiology, University of Tennessee, Memphis, Tennessee, USA  
S C Kaste

Department of Pediatrics, Division of Clinical Genetics, University of Tennessee, Memphis, Tennessee, USA  
E K Pivnick

Correspondence to:  
Dr Kaste, Diagnostic Imaging, St Jude Research Hospital, 332 N Lauderdale, Memphis, TN 38105, USA.

Received 22 December 1997  
Revised version accepted for publication 9 February 1998

Table 1 Definition of terms<sup>17</sup>

Dimension	Description
Lateral orbital distance	Distance between anterior tips of the lateral orbital walls
Anterior interorbital distance	Distance between the anterior ends of the medial orbital walls
Mid interorbital distance	Distance across the ethmoid bone, midway between the optic strut base and the lacrimal bone
Intertemporal distance	Distance between the most medial aspect of the greater sphenoid wing
Medial orbital wall length	Distance between the lacrimal bone and optic strut base
Lateral orbital wall length	Distance from base of the optic strut and the most anterior tip of the lateral orbital wall
Lateral orbital angle	The angle defined by the sagittal axis and a line from the most anterior and posterior tips of the lateral orbital wall

Table 2 Comparison of patient characteristics, volumetric asymmetry, and dimensional abnormalities in patients with neurofibromatosis type 1

No of patients	Group I (patients without OPG)	Group II (patients with OPG)
Total evaluated	38	20
With NF1 lesions	15 (39%)	17 (85%)
Who received orbital or cranial irradiation	0	9
With orbital volumetric asymmetry	26 (68%)	14 (70%)
	Range 0.4–6.5 cm <sup>3</sup>	Range 0.4–7.7 cm <sup>3</sup>
With increased dimensions	14 (37%)	10 (5%)
With decreased dimensions	7 (18%)	7 (35%)
With multiple dimensional abnormalities	7 (18%)	9 (45%)
Sphenoid wing dysplasia	1 (3%)	1 (5%)

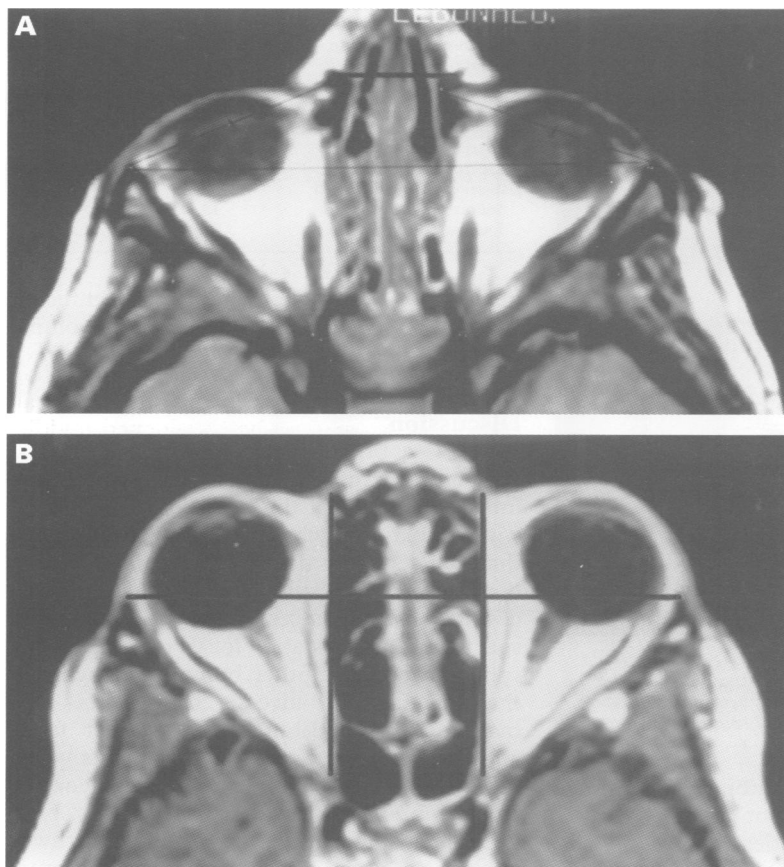


Figure 1 Examples of abnormal orbital dimensions in groups I and II. (A) A 5 year old boy (group I) with symmetrical orbital volumes but with increased anterior orbital distance (heavy black line). (B) A 7 year old boy (group II) with symmetrical orbital volumes but with increased medial wall lengths bilaterally (vertical lines) and increased transorbital dimension (horizontal line).

and determined the presence or absence of volumetric asymmetry ( $\Delta v$ ). As the bony orbit is conical in configuration,<sup>18</sup> orbital volumes were determined using the transverse and anteroposterior orbital dimensions and the equation for the volume of a cone ( $\pi r^2 h/3$ ). A volumetric difference of equal to or less than 0.3 cm<sup>3</sup> was considered to be normal. The designation of symmetry was based on a disparity in a single orbital dimension of greater than 1 mm representing asymmetry.<sup>19</sup>

## Results

### PATIENTS WITHOUT OPTIC PATHWAY GLIOMAS (GROUP I)

The 38 patients comprising group I ranged in age from 1.1 to 25.5 years (median 5.5 years) at the time of imaging; 18 were males, 20 were females, 16 (42%) were African-American, and 22 (58%) were white. One patient had unilateral sphenoid wing hypoplasia. Fifteen

Table 3 Distribution of dimensional abnormalities of patients with neurofibromatosis type 1

Measured dimension	Group I (patients without OPG)	Group II (patients with OPG)
Lateral orbital distance		
Increased dimension	5	3
Decreased dimension	0	3
Anterior interorbital distance		
Increased dimension	4	2
Decreased dimension	1	1
Mid interorbital distance		
Increased dimension	3	2
Decreased dimension	0	0
Intertemporal distance		
Increased dimension	6	4
Decreased dimension	0	2
Lateral orbital angle		
Increased dimension	1	0
Decreased dimension	0	0
Medial orbital wall length		
Increased dimension	2	4
Decreased dimension	6	0
Lateral orbital wall length		
Increased dimension	1	4
Decreased dimension	2	2

patients (39%) had intracranial NF1 lesions (UBOs). Five patients had received radiation therapy for intracranial tumours before imaging for this study. Twenty-six patients (68%) had a median orbital volumetric asymmetry of 0.8 cm<sup>3</sup> (range 0.4 to 6.5 cm<sup>3</sup>). Twenty-one (55%) patients had abnormal orbital dimensions (14 with increased dimension and seven with decreased dimension), and seven (18%) had multiple dimensional abnormalities (table 2, figs 1A and 2A). Only one of the five patients who received cranial irradiation had abnormal orbital dimensions and this comprised decreased lateral orbital wall lengths bilaterally.

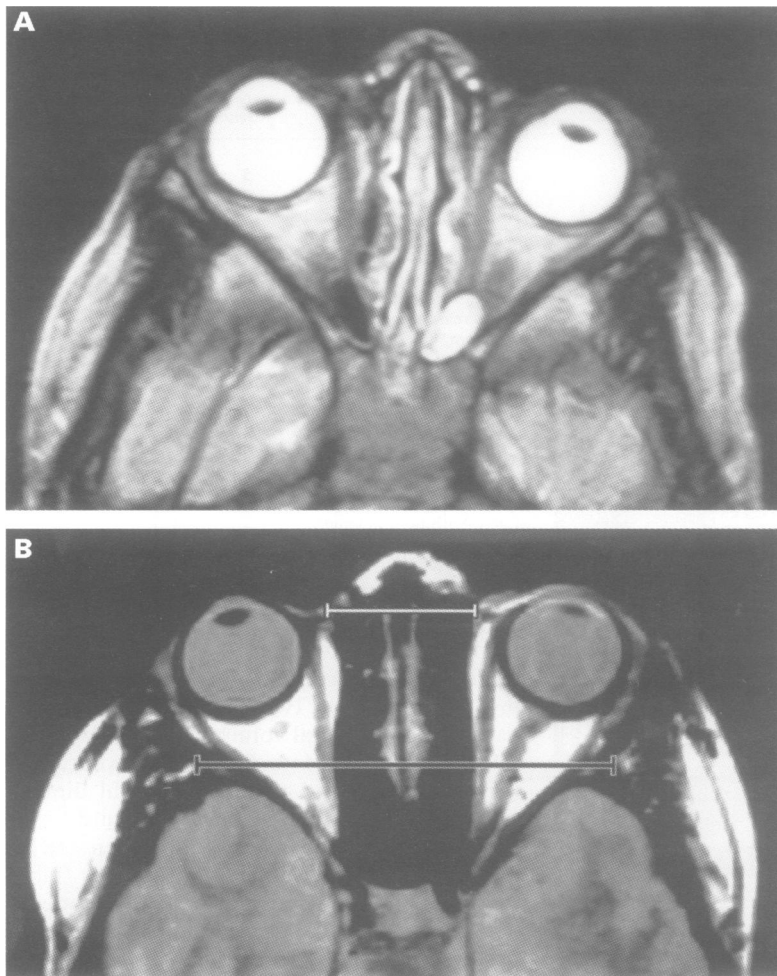
### PATIENTS WITH OPTIC PATHWAY GLIOMAS (GROUP II)

The 20 patients comprising group II ranged in age from 0.5 to 24.5 years (median 8.1 years) at the time of imaging. Six were males, 14 were females, one (5%) was Hispanic, two (10%) were African-American, and 17 (85%) were white. The prevalence of OPG in African-American patients was less than that observed among the remaining patients of other racial origins in the study group, 11% *v* 45%, respectively ( $p < 0.012$ ).

One patient had unilateral sphenoid wing hypoplasia. In this group, 17 patients (85%) had NF1 lesions (UBOs) of the brain. Two patients also had brainstem glioma, one patient underwent unilateral optic nerve resection for optic pathway glioma, and four patients had received orbital or cranial radiation for treatment of OPG or intracranial tumours before imaging. Of the four patients who received cranial or orbital irradiation, only one had unilateral decrease in the lateral orbital wall length.

OPGs were confined to the optic chiasm in two cases (both with bilateral involvement) and to the orbits in four (of which one case had unilateral involvement). The remaining 14 cases (70%) had involvement of both the intraorbital optic nerves and the optic chiasm. Eight of these 14 had symmetrical involvement and only one had unilateral involvement.

Fourteen patients (70%) in group II had a median orbital volume asymmetry of 1.1 cm<sup>3</sup>



**Figure 2** Examples of orbital volumetric disparity in groups I and II. (A) A 5 year old boy (group I) with asymmetrical orbital volumes (OD 2.8 cm larger than OS). He has no other dimensional aberrations. (B) A 6 year old girl (group II) with asymmetrical orbital volumes (OD 5.2 cm smaller than OS). She also has an increase in both the anterior (white line) and lateral interorbital distances (black line).

(range 0.4 to 7.7 cm<sup>3</sup>). Orbital dimensional abnormalities were present in 17 patients (85%). Ten of the 17 patients had increased dimensions, seven had decreased dimensions, and one had both increased and decreased dimensions. Nine patients (45%) had multiple dimensional abnormalities (table 3, figs 1B and 2B).

#### ORBITAL SYMMETRY AND ORBITAL DIMENSIONS IN AFRICAN-AMERICAN AND WHITE PATIENTS

Eleven of the 18 African-American patients had abnormal orbital dimensions (61%). Seven of these 11 patients had increased dimensions (64%) and three patients had decreased dimensions (27%). None had both increased and decreased dimensions. The most common abnormalities were an increased intertemporal distance (n=3) and increased lateral orbital dimension (n=4).

Twenty-three of the 39 white patients had abnormal orbital dimensions (59%). A total of 15 patients had increased dimensions (65%). The most common abnormalities were increased intertemporal distance (n=7), increased lateral temporal distance (n=5), and increased anterior interorbital distance (n=5). There were seven patients who had decreased dimensions (30%) and two who had a combination of decreased and increased di-

**Table 4** Comparison of orbital symmetry and orbital dimensions in African-American and white patients with neurofibromatosis type 1

Measured dimension	African-American	White
Lateral orbital distance		
Increased dimension	4	5
Decreased dimension	0	3
Anterior interorbital distance		
Increased dimension	1	5
Decreased dimension	0	2
Mid interorbital distance		
Increased dimension	2	3
Decreased dimension	0	0
Intertemporal distance		
Increased dimension	3	7
Decreased dimension	0	2
Lateral orbital angle		
Increased dimension	1	0
Decreased dimension	0	0
Medial orbital wall length		
Increased dimension	1	2
Decreased dimension	3	2
Lateral orbital wall length		
Increased dimension	1	3
Decreased dimension	0	2

mensions (8%). There was no significant difference in the orbital median volume between the races (table 4).

#### Discussion

There is a broad spectrum of facial skeletal aberrations among patients with NF1. At the most severe end of this spectrum is sphenoid wing dysplasia which may progress to a severity that will seriously disrupt the integrity of the bony orbit and result in serious medical and cosmetic consequences. At the other end of the spectrum, mild, static, local lesions of the sphenoid bone or other bony components of the orbit have no adverse consequences and may merely contribute to a distinct facial appearance in some of the NF1 patients.<sup>7</sup>

In this study we examined the incidence of orbital abnormalities in two groups of NF1 patients: (1) patients without optic pathway gliomas (group I) and (2) patients with optic pathway gliomas (group II) and we compared these patients to normal standards. There was a significantly increased incidence of conformational abnormalities present in both NF1 groups as compared to normal controls. Although no specific pattern of configurational abnormality emerged, there was a trend towards increased distance between the orbits. The most common abnormalities in both NF1 groups were the increased transorbital diameter, intertemporal distance, anterior interorbital distance, and mid interorbital distance, all of which probably contribute to the hypertelorism observed in many patients with NF1.

Multiple conformational abnormalities were more frequent in patients with OPG than in those without OPG. Though our study populations are small, these findings suggest that more numerous and severe developmental abnormalities manifest in patients with the more severe phenotypic expression (that is, OPG).

There was a notable difference in the incidence of UBOs, increased signals on T2 weighted images, between groups I and II. These foci of altered signal were seen more

commonly in the OPG group (group II) than in those without OPGs (group I). The clinical significance of UBOs is not well known. As NF1 patients who develop OPGs have more UBOs than patients without OPGs, the increased incidence of UBOs in patients in the OPG group may reflect the severity of the disease process. The association of UBOs and OPG must be approached with caution. In as much as patients with OPG tend to undergo more frequent neuroimaging than those without OPG, the increased frequency of UBOs in group II may reflect imaging bias.

There was a significant difference in the racial distribution between groups I and II. Group I comprised 16 African-Americans (42%) in contrast to group II comprising only two (10%) African-Americans ( $p < 0.012$ ). These data support the observations made by others that there are racial differences in the incidence of optic pathway tumours in NF1.<sup>7 20 21</sup> However, when we compared orbital symmetry and orbital dimensions in African-American and white patients, we found no significant difference between the two groups.

Both study groups displayed orbital volumetric disparity to the same degree, thereby suggesting that orbital volumetric inequality is independent of the presence of OPG, and that volumetric asymmetry is a manifestation of the potential for growth disturbances in patients with NF1. Further, by the preponderance of patients with extensive OPGs (that is, involving both the optic chiasm and orbits), any possible effect on orbital growth that may result from the distribution of OPGs would have been exaggerated. Though a total of nine patients from both study groups had received orbital or cranial irradiation, only two had decreased orbital dimensions and a third had an increased dimension. We do not believe that the facial developmental aberrations (that is, the prevailing increased orbital dimensions) are necessarily related to radiation therapy in that orbital irradiation decreases bony orbital growth.<sup>22-25</sup>

The observations of this study suggest that the NF1 gene plays an important role in the embryonic development of the orbit. We propose that the orbital developmental abnormalities in NF1 are more prevalent and show a wider spectrum than was previously appreciated. Orbital abnormalities, as a skeletal substrate, may contribute to the characteristic NF1 facial appearance in some cases. Larger studies and correlation with genotype will be needed to understand this complex syndrome better.

We are grateful to Dr Vincent M Riccardi for his comments on this paper. We thank Dr Elizabeth A Tolley for the statistical analysis. This work was supported by grants P30 CA-21765 and PO1 CA-23099 from the National Cancer Institute, by the American Lebanese Syrian Associated Charities (ALSAC) (SCK), from the Herbert and Mary Shainberg Neuroscience's Research Program, and the Crippled Children's Foundation Research Center Grant at the LeBonheur Children's Medical Center from Memphis Tennessee (EKP).

- Huson SM, Harper PS, Compston DAS. Von Recklinghausen neurofibromatosis: a clinical and population study in South East Wales. *Brain* 1988;111:1355-81.
- Burrows EH. Bone changes in orbital neurofibromatosis. *Br J Radiol* 1963;36:549-61.
- Jacoby CG, Go RT, Beren RA. Cranial CT of neurofibromatosis. *AJR* 1980;135:553-7.
- Hunt JC, Pugh DG. Skeletal lesions in neurofibromatosis. *Radiology* 1961;76:1-19.
- Zimmerman RA, Bilaniuk LT, Metzger RA, Grossman RI, Schut L, Bruce DA. Computed tomography of orbital-facial neurofibromatosis. *Radiology* 1983;146:113-16.
- Bognanno JR, Edwards MK, Lee TA, Dunn DW, Roos KL, Klatte EC. Cranial MR imaging in neurofibromatosis. *AJR* 1988;151:381-8.
- Riccardi VM. *Neurofibromatosis: phenotype, natural history and pathogenesis*. 2nd ed. Baltimore: The John Hopkins University Press, 1992.
- Rootman J, Robertson W. Tumors. In: Rotman J, ed. *Disease of the orbit*. New York: J B Lippincott, 1988.
- Binet EF, Kieffer SA, Martin SH, Peterson HO. Orbital dysplasia in neurofibromatosis. *Radiology* 1969;93:829-33.
- Moore RF. Diffuse neurofibromatosis with proptosis. *Br J Ophthalmol* 1993;15:272-9.
- LeWald LT. Congenital absence of the superior orbital wall associated with pulsating exophthalmos. *AJR* 1933;30:756-64.
- Gardeur D, Palmieri A, Mashaly R. Cranial computed tomography in the phakomatoses. *Neuroradiology* 1983;25:293-304.
- Murtaugh FR, Boyd RE, Okuski TA. Internal auditory canal flaring in neurofibromatosis without acoustic neuroma. *Arch Neurol* 1980;37:785.
- DiMario FJ, Bowers P, Jagiavan B, Burleson J, Langshur S, Greenstein RM. Analysis of skull anthropometric measurements in patients with neurofibromatosis type-1. *Invest Radiol* 1992;28:116-20.
- Westerhof W, Delleman JW, Wolters E, Dijkstra P. Neurofibromatosis and hypertelorism. *Arch Dermatol* 1984;120:1579-81.
- Wolters EC, Westerhof W, Delleman JW, Dijkstra P. Hypertelorism in neurofibromatosis. *Neuropediatrics* 1986;17:175-7.
- Waitzman AA, Posnick JC, Armstrong DC, et al. Craniofacial skeletal measurements based on computer tomography. Part II. Normal values and growth trends. *Cleft Palate Craniofac J* 1992;29:118-28.
- Kennedy RE. The effect of early enucleation on the orbit in animals and humans. *J Ophthalmol* 1965;60:277-306.
- Newton TH, Potts DG. *Radiology of the skull and brain*. Vol 1, book 2. St Louis: Mosby, 1971:465-9.
- Saal HM, Schorry EK, Lovell AM, et al. Racial differences in the prevalence of optic nerve gliomas in neurofibromatosis type 1. *Am J Hum Genet* 1995;280:A54.
- Pletcher BA, Magee MI, Frohman IP, et al. Conformation of decreased risk of optic glioma in African Americans with NF type I. *Am J Hum Genet Suppl* 1996;59:A101.
- Kaste SC, Chen G, Fontanesi J, Crom DB, Pratt CB. Orbital development in longterm survivors of retinoblastoma. *J Clin Oncol* 1997;15:1183-9.
- Guyuron B, Dagens AP, Munro IR, et al. Effect of irradiation on facial growth: a 7- to 25-year follow-up. *Ann Plastic Surg* 1983;11:423-7.
- Egawa S, Tsukiyama I, Akine Y, et al. Suppression of bony growth of the orbit after radiotherapy for retinoblastoma. *Radiat Med* 1987;5:207-11.
- Ju DMC, Moss M, Crikelaier GF. Effect of radiation on the development of facial structures in retinoblastoma cases. *Am J Surg* 1963;106:807-15.