

# Twenty-four cases of the EEC syndrome: clinical presentation and management

P W Buss, H E Hughes, A Clarke

## Abstract

**Twenty-four cases of EEC syndrome were identified as part of a nationwide study. Ectodermal dysplasia, by study definition, was present in all cases and hair and teeth were universally affected. Nail dysplasia was present in 19 subjects (79%) and the skin was affected in 21 (87%). The presence of hypohidrosis was not noted as a predominant feature in the syndrome and its occurrence appeared to depend on the presence of all other features. Distal limb defects from simple syndactyly to tetramelic cleft hand and foot were identified, including preaxial anomalies. Orofacial clefting was identified in 14 cases (58%) and lacrimal duct anomaly in 21 (87%).**

**Significant clinical problems encountered were chiefly cosmetic or ophthalmological, but conductive deafness and genitourinary problems in some cases required surgical intervention. Altered self-image was also noted in some cases. Multidisciplinary management is necessary with the early involvement of the clinical geneticist.**

**Developmentally, the EEC syndrome and related disorders represent disorders of ectodermal/mesodermal interaction. Candidate regions include 7q21.3, the "ectrodactyly" locus; other candidates include developmental genes implicated in the ectodermal/mesodermal interactive process.**

(J Med Genet 1995;32:716-723)

The EEC syndrome is a multiple congenital anomaly syndrome characterised by ectodermal dysplasia, distal limb anomaly, cleft lip and palate, and lacrimal duct anomalies. The acronym was first used by Rudiger *et al*<sup>1</sup> describing a girl with trimelic ectrodactyly, ectodermal features involving hair, teeth, and nails, and bilateral cleft lip and palate. Cockayne<sup>2</sup> had previously reported a case of dacryocystitis and orofacial clefting and both Walker and Clodius<sup>3</sup> and Rosselli and Gulinetti<sup>4</sup> described cases with anomalies similar to those described by Rudiger *et al*<sup>1</sup> with, in addition, lacrimal duct anomalies.

There exist numerous case reports of EEC and phenotypically related syndromes. The Rapp-Hodgkin ectodermal dysplasia<sup>5</sup> and the ankyloblepharon, ectodermal dysplasia, and clefting (AEC) syndrome<sup>6</sup> are believed, by many, to represent separate clinical entities. The overlap between these and the EEC syn-

drome has become more apparent as the recognised clinical spectrum of the EEC syndrome has continued to broaden. Kuster and Majewski<sup>7</sup> reported eight members in two families with the EEC syndrome with no limb defects. Majewski and Kuster<sup>8</sup> later coined the term "oligosymptomatic EEC syndrome" and suggested that ectrodactyly was not mandatory for syndrome diagnosis. Penchaszadeh and de Negrotti<sup>9</sup> had previously indicated that the lack of a major component in the syndrome should not preclude diagnosis and subsequently Wallis<sup>10</sup> reported a four generation family with EEC syndrome without orofacial clefting. Renal anomalies are also frequently reported in the syndrome.<sup>11</sup> Other reported anomalies include choanal atresia,<sup>12</sup> growth retardation,<sup>13</sup> and EEG abnormalities.<sup>14</sup> We undertook a clinical study of the EEC syndrome in the UK to delineate closely such aspects of the condition in a defined population, although recognising that complete ascertainment would not be possible.

## Methods

Case ascertainment was through a letter circulated to over 1000 clinicians (paediatricians, clinical geneticists, orthodontists, and plastic surgeons) and the criteria for notification included cases with the following:

- (1) A definite or provisional diagnosis of EEC syndrome.
- (2) Ectodermal dysplasia with distal limb anomalies.
- (3) Ectodermal dysplasia with orofacial clefting, with/without distal limb anomalies.

## Diagnostic criteria

For the purpose of the study ectodermal dysplasia was chosen as a mandatory feature in syndrome definition. Cases were also considered eligible for inclusion if at least one family member had ectodermal dysplasia and they also possessed: (1) a minimum of *two* additional major signs (table 1); (2) absence of a specific pointer towards one of the other syndrome diagnoses; (3) a clear reason *not* to categorise them among one of the overlap syndromes currently recognised as distinct. If in

Table 1 Major and minor anomalies in EEC syndrome (criteria for acceptance into the UK study)

Major	Minor
Ectodermal dysplasia	Renal anomalies
Ectrodactyly	Deafness
Cleft lip/palate	Mental retardation
Lacrimal duct anomalies	Choanal atresia

Institute of Medical Genetics,  
University of Wales  
College of Medicine,  
Heath Park,  
Cardiff CF4 4XN,  
UK

P W Buss  
H E Hughes  
A Clarke

Correspondence to:  
Dr Buss.

Received 10 January 1995  
Revised version accepted for  
publication 10 April 1995

Table 2 A summary of clinical findings in 24 cases of the syndrome

Syndrome component	Case No
Ectodermal dysplasia*	
Three components	2, 3, 4, 6
Four components	1, 5, 8, 9, 10, 11, 12, 13, 14, 15, 16, 17, 18, 19, 22, 23
Five components	7, 20, 21 (all with hypohidrosis)
Limb deficit	
Cleft limb only (No of affected)	2(4), 4(4), 8(4), 9(4), 10(2), 11(4), 14(1), 16(1), 18(4), 19(1), 20(4), 21(4), 22(4), 23(4)
Cleft limb/syndactyly	1, 5, 6, 7, 8, 17
Syndactyly only	15
Preaxial	6 (absent thumb), 19 (small proximal thumbs)
Orofacial clefting	
CLP (unilateral)	1, 2, 4, 17, 19, 21
CLP (bilateral)	12, 18, 20, 22, 23
CP	7 (submucous), 16
Cleft lip	No cases
Lacrimal duct anomaly	
Uni/bilateral	1, 2, 4, 5, 6, 7, 8, 9, 10, 11, 12, 14, 16, 17, 18, 19, 20, 21, 22, 23, 24
Deafness	
Conductive	2, 4, 6, 7, 16, 18, 19, 20, 21, 22
Sensorineural	No cases
UG tract anomaly	
Hypospadias	7
Reflux	19
Hydronephrosis	13, 21, 22, 24
Other	23 (reduced bladder volume)

Familial cases: 3, 4, 10, 11, 12, 14, 15, 23, 24.

\* Case 24 omitted owing to age at entry.

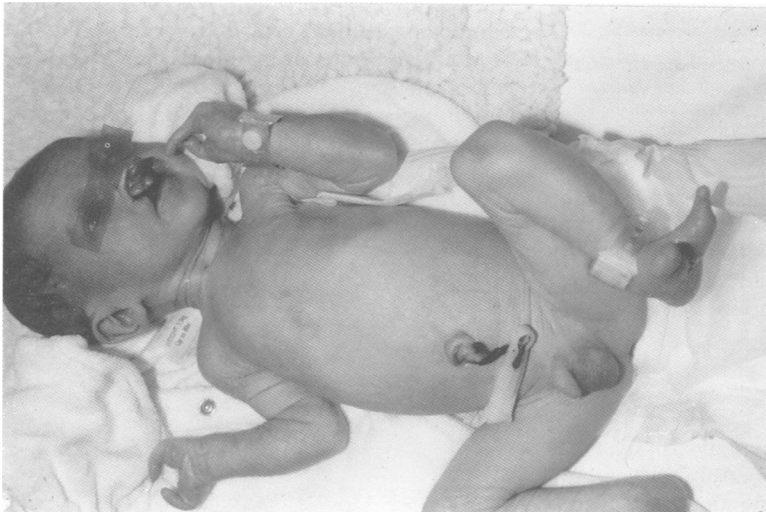

Figure 1 The infant with EEC syndrome. Case 12 shows evidence of three major features of the syndrome. He has additional bilateral lacrimal duct anomalies.

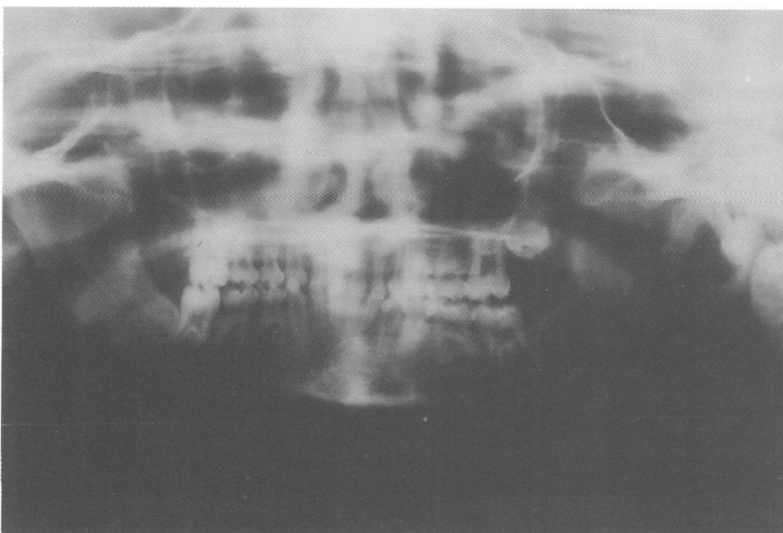


Figure 2 Dental x ray of case 14 shows oligodontia (reduced number of teeth) and those present are taurodontic (have widened tooth pulp).

a particular case clinical features (for example, ankyloblepheron, hypospadias, skin pigmentation) suggested significant doubt, then this case was excluded from the study group despite satisfying our first criterion.

### Result of ascertainment

Twenty-nine replies indicated possible EEC syndrome. Three cases (following examination) had Rapp-Hodgkin ectodermal dysplasia and two cases had ankyloblepheron, ectodermal dysplasia, and clefting syndrome. Three cases clearly did not fit into our study criteria and three cases, identified as cases of the EEC syndrome by clinical geneticists, were unwilling to participate. Eighteen cases met the inclusion criteria and they and their immediate families were visited at home leading to a total ascertainment of 24 cases (in 18 families).

### Clinical findings (table 2)

The total group consisted of 16 males and eight females with ages ranging from 1 month to 52 years and with mean birth weight for males at term of 2770 g (below 10th centile) and females of 3010 g (25th centile). Two males (cases 19 and 22) and a female (case 24) were preterm, both with birth weights appropriate for gestational age. Subsequent postnatal growth in all cases was satisfactory. By definition all cases showed evidence of ectodermal involvement (however, no relatives of probands were excluded because of its absence). Distal limb deficit was present in 21/24 (87.5%) (fig 1), facial clefting in 14/24 (58%), and lacrimal duct anomaly in 21/24 (87.5%).

### ECTODERMAL DYSPLASIA

Freire-Maia and Pinheiro<sup>15</sup> deemed that at least two abnormal ectodermal components should be present. Over three quarters of the cases in our study had four or five ectodermal features clinically apparent.

### TEETH

The teeth were universally affected although historically the primary dentition was usually complete though not always morphologically normal. The dentition of three cases under 1 year of age could not be adequately assessed. Abnormalities noted in secondary dentition included microdontia and oligodontia. The teeth were not as conical as in cases of XHED, being more often straight edged with gaps. Dental caries was universally present and usually severe. Where x rays had been visualised taurodontism (deepened pulp space) was a consistent finding (fig 2).

### HAIR

Hair was affected in all cases, generally being light in colour (as were eyelashes) and coarse and dry in 18/23 (78%). In five cases it was poorly formed, sparse, and extremely slow growing (fig 3). Affected postpubertal males

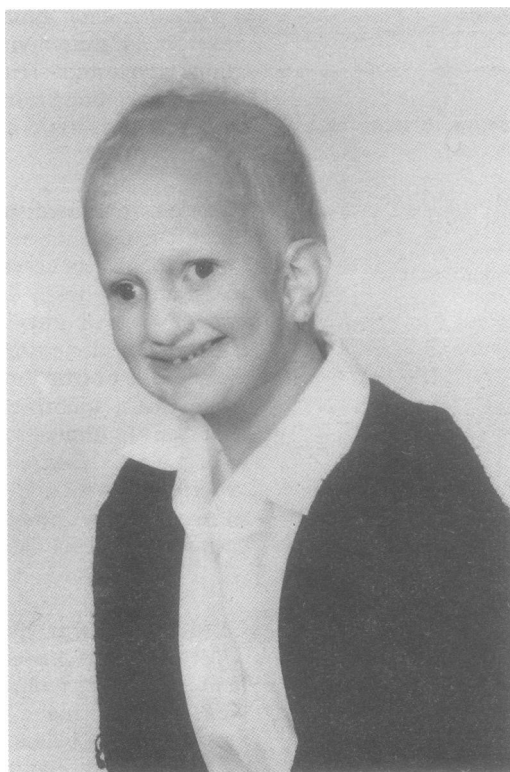

Figure 3 Case 6 with evidence of severe hair dysplasia and loss, leading to sparse, "downy", soft hair quality rather than to coarse, dry hair seen in most cases.

tended to have less body hair than usual (particularly on the limbs) but facial and axillary hair grew normally. A gradual tendency for increase in hair pigmentation with age was noted in several cases.

#### NAILS

Nineteen cases (79%) had nail dystrophy. Nails were slow growing, transversely ridged and pitted, and showed varying degrees of concavity. Such findings could be readily visualised with magnification using a hand lens.

#### SKIN

Clinical problems were often minor but were noted in 21 cases (87%). One case was severely affected (case 10). Dry, scaled skin on the extremities was the most common manifestation, occasionally also present around the neck. Notably other flexures were spared. Painful fissuring in interdigital webs and finger pulps was reported in a number of cases; this occurred on the feet of case 23. Case 12 had major skin problems at birth (fig 4) though as a clinical problem this was diminishing. His grandfather (case 10) had ichthyosiform erythroderma<sup>16</sup> affecting his neck with Candidal superinfection infection. Case 2 showed evidence of solar keratosis in the third decade as well as recurring Candidal paronychia. He was also noted to have recurring precancerous scrotal skin lesions. In most cases a pale complexion was noted with two cases (cases 7 and 20) having an almost albinoid appearance.

#### SWEATING

Reduced sweating did not manifest as a major problem. Three cases (13%) (case 24 not assessed) had symptomatic hypohidrosis. All three, however, reported scalp sweating in particularly warm conditions. Those with symptomatic hypohidrosis possessed all major features of the syndrome.

#### LIMB ANOMALY

This was identified in 21 cases (87%) of whom 12 (57%) had tetramelic involvement (10 possessing tetramelic cleft limb). Six cases had a central ray deficit in the upper limbs combined with syndactyly of the toes. Eight cases (38%) had asymmetry of the limb defect with the same number possessing at least one limb with isolated syndactyly. Two cases (9%) had pre-axial anomalies, one with a unilateral absent thumb (case 6) and one with two small proximally placed thumbs (case 19). The digits most commonly involved in syndactyly were digits three and four, in both upper and lower limbs.<sup>17</sup>

Functional impairment was usually not a significant problem provided opposition could be attained. Some cases had had surgery closing wide cleft hands, or to separate a syndactyly. Obtaining suitably wide fitting shoes was a frequently encountered problem. The 16 parents of eight isolated cases were examined and no subtle manifestations were found in the limbs.

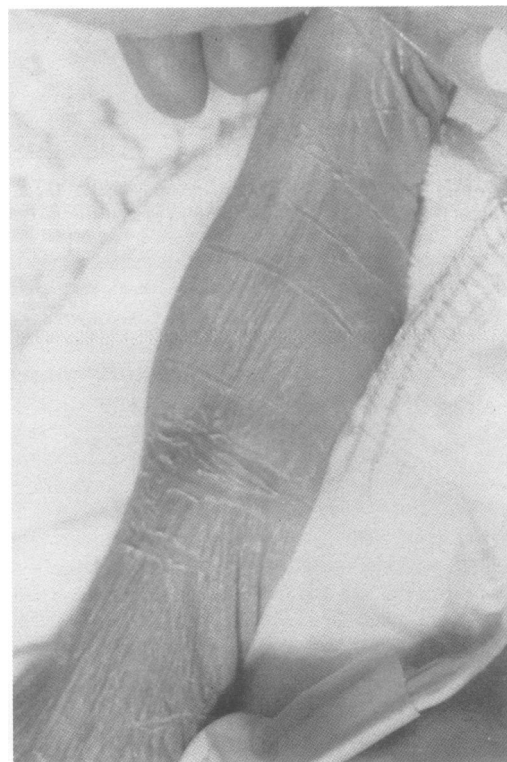

Figure 4 Case 12, an early clinical clue, dry skin at birth despite prematurity. In this case dry, scaly skin remained throughout childhood.

**OROFACIAL CLEFTING**

Thirteen cases had orofacial clefting. Five (38%) had bilateral cleft lip and palate and six possessed unilateral cleft lip and palate. Two cases had a central cleft palate, submucous in one (case 7). All cases with cleft palate had nasal quality of speech indicating velopharyngeal incompetence.

**LACRIMAL DUCT INVOLVEMENT**

Twenty-one cases (87%) had had lacrimal duct problems, usually bilateral, causing most difficulty in infancy. Epiphora and recent recurrent infections were commonly reported reflecting varying degrees of nasolacrimal duct obstruction, Meibomian gland dysfunction, and reduced tear production. Four cases (cases 5, 10, 20, and 22) had severe visual impairment from chronic corneal scarring (cases 6 and 20 are registered partially sighted). Infections reduced in number with age and following operative procedures. Case 5 required corneal grafting (which to date has been successful) and case 11 required urgent surgical intervention and corneal grafting following an anterior chamber haemorrhage.

**HEARING**

Ten of 23 cases (44%) reported a degree of hearing loss. In the seven cases where audiograms were examined a conductive deficit was observed. In no case was the hearing loss sensorineural in origin. Many cases reported impacted cerumen as a transient cause of hearing deficit, but those with persistent deficit consistently reported episodes of recurrent otitis media in childhood and had a repaired orofacial cleft. Case 2 had required surgery for cholesteatoma.

**GENITOURINARY ANOMALIES**

Fourteen cases (58%) had had a renal ultrasound scan performed before our survey and six (42%) had a problem. Anomalies included glandular hypospadias (case 7), ureteric reflux (case 19), and hydronephrosis (cases 13 and 24) which led to unilateral nephrectomy in case 13 and ureterostomy in case 24. Cases 7 and 9 had recurrent urinary tract infections and subsequent ultrasound scans were normal (although more detailed radiological investigations had not been performed). Case 23 reported long term dysuria and frequency and was shown to have a thick walled, very small volume bladder. Similar symptoms were reported at 2 years by the parents of case 17.

**DEVELOPMENT**

No affected subject had mental retardation or evidence of developmental delay. Language milestones were normal despite some having moderate hearing impairment. All affected people attended normal schools. A formal intellectual and behavioural assessment was not undertaken. Occupations of the affected adults were varied, from postman to clerk/typist to professional artist.

**OTHER REPORTED PROBLEMS**

Two cases (cases 7 and 22) reported difficulties with eating dry food, probably related to altered salivary gland function and frequent fluids were required while eating. Case 7 (with associated hypohidrosis) refused warm drinks in infancy. Postpubertal females reported normal breast development. Case 15 had poorly defined areolae and nipples; her father (case 13) also had this. Cases 11 and 23 elected not to breast feed because of hypoplastic nipples. An additional reason for case 11 was the facial cleft in her affected child.

In those families where prenatal diagnosis was considered, all parents were aware of a 50% risk. The fetus of case 23 was noted to have marked renal dilatation but normal face and limbs on high resolution scanning. Confirmation of disease status was, however, possible within several weeks of delivery. Fetal limb anomalies were detected at 22 weeks' gestation in case 10.

Many cases experienced frustration at apparent late recognition of the syndrome. For example case 22 (with all four major manifestations) was not offered appropriate counselling until he was 20 years of age. Psychologically most cases appeared to cope with their condition well. Most were self-confident and had developed good interpersonal communication skills. Affected adults did express unhappiness with their body image, wished for public acceptability, and recalled particularly unhappy adolescent years. In addition the persistent hiding of hands was a common behavioural trait.

**FAMILY HISTORIES**

The four families in this study, although small, clearly show the autosomal dominant nature of this condition. Variability in expression was observed both within and between families. The family with cases 3 and 4 manifested the gene purely as ectodermal dysplasia (case 3). This was also evident in a second family (case 13). Only one three generational family was ascertained. Case 24 had no orofacial or limb aspects of the syndrome, unlike her mother. A sib of case 18 had isolated ulnar hypoplasia but no other signs. This was deemed to be interesting but a possibly unrelated occurrence. In nine isolated cases both parents were examined and were normal, and a total of three normal children were born to isolated cases. Karyotype analysis of one affected member from each family was normal as was analysis of seven isolated cases.

**Discussion**

The variability of the EEC phenotype has become increasingly apparent over the last decade. The condition can appear as isolated ectodermal dysplasia in one family member and then in a more fully developed state in a subsequent child.

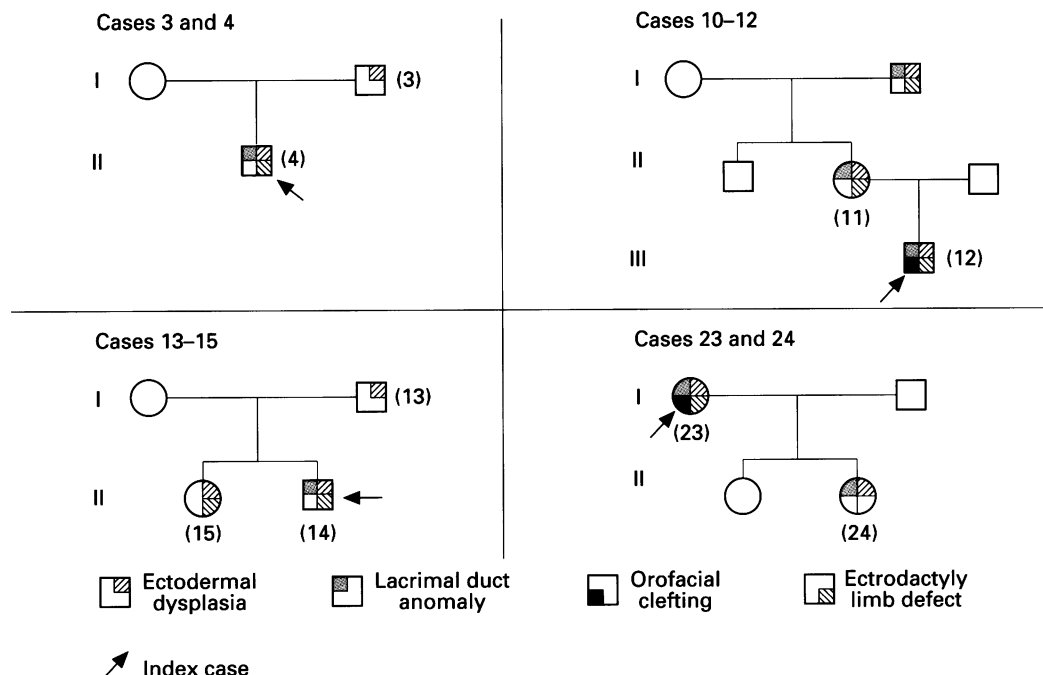


Figure 5 Basic pedigrees showing small families and autosomal dominant inheritance.

#### INHERITANCE

Although dominant inheritance is confirmed in the familial cases (fig 5), the small size of the families is difficult to explain. Families with isolated ectrodactyly may be extensive. There is also no physiological reason to expect reduced reproductive fitness in EEC families. No cases of recessive inheritance or parental consanguinity were recorded. Pries *et al*<sup>18</sup> referred to possible autosomal recessive inheritance when describing two affected sibs of apparently clinically normal parents and De Silva *et al*<sup>19</sup> reported similar findings. Both reports, however, contain sparse data on parents and germinal mosaicism or altered gene penetrance cannot be excluded. Clear parental consanguinity was recorded in an isolated case by Rogmanoli and Zunin.<sup>20</sup>

#### ECTODERMAL FEATURES

Ectodermal features were, by definition, present in all cases. Secondary dentition was always affected. The frequently noted normal number of deciduous teeth has been recorded by Psaume *et al*<sup>21</sup> previously. Hair, although usually lightly pigmented, dry, and coarse, may sometimes be sparse. Salinas and Marcos Montes<sup>22</sup> suggested that there were specific potentially diagnostic characteristics of hair in the Rapp-Hodgkin syndrome using polarising light.<sup>22</sup> Studies on hair morphology in EEC syndrome are currently being undertaken. Hypohidrosis is not a common or severe problem as in XHED, where the erroneous diagnosis of infection and subsequent placement of the neonate in an incubator may endanger life.<sup>23</sup> Abnormalities of eccrine glands may take a number of forms and studies of these are necessary in the EEC syndrome. Those cases with altered hidrosis fulfilled all four major criteria of the syndrome. Although this finding may

result from ascertainment bias it could also suggest that hypohidrosis in the EEC syndrome is dependent on the presence of all major features.

Skin and hair hypopigmentation have been described previously and were frequently noted in our group. Severe skin problems were uncommon however. Although dryness of the skin was noted by many, it posed a clinical problem in just two cases. Reference has been made to premalignancies arising in cases of the EEC syndrome<sup>24,25</sup> and Clouston type ectodermal dysplasia.<sup>26</sup> These reports are of significance in view of the premalignant biopsy reports of ulcerated scrotal skin in case 2.

#### OPHTHALMIC FEATURES

Freid<sup>27</sup> indicated that visual difficulties were potentially the most serious clinical feature of the syndrome. Progressive visual loss and spontaneous corneal perforation have been documented as serious ocular complications of the EEC syndrome.<sup>28</sup> Corneal scarring may result from Meibomian gland dysfunction and also from recurrent blepharitis which is more common in infancy and ameliorated by operations to improve lacrimal drainage. Case 11 suffered spontaneous corneal perforation with severe visual impairment and both cases 5 and 11 had corneal grafts functioning reasonably well during the early months.

#### LIMB ANOMALIES

While the central ray defect is the hallmark of the EEC syndrome its absence clearly does not exclude the diagnosis. In some cases isolated soft tissue syndactyly or thumb anomalies may occur. The coexistence of preaxial and central ray anomaly within the syndrome is an aspect which hitherto has not been much appreciated,

although preaxial digital anomalies have featured in the descriptions of trigger thumb<sup>8</sup> and duplication.<sup>29</sup> Preaxial anomalies also occur in the LADD syndrome.<sup>30</sup>

#### OROFACIAL CLEFTING AND HEARING

Typically both lip and palate were cleft although a single case of submucous cleft palate was noted. Successful repair was achieved in all but one case (case 7). Historically both conductive and sensorineural hearing impairment have been described in the EEC syndrome. In one case ear ossicles were absent on tympanotomy.<sup>31</sup> All affected cases had a history of middle ear infection confirmed by review of seven audiograms. Eight of the nine cases with hearing impairment interestingly had orofacial clefts. Impacted cerumen was a common cause of transient hearing loss generally (cf XHED). Despite several reported cases of sensorineural hearing loss in EEC syndrome,<sup>32 33</sup> no case was noted in our group. Structural pinna anomalies have been previously reported (usually down folding)<sup>11 29</sup> but are unusual, only one case showing an anomaly of the external ear (case 5) which in this case was of the tragus and associated with minor posterior rotation.

#### RENAL TRACT

Rollnick and Hoo<sup>34</sup> suggested that renal tract involvement occurred in up to 50% of cases. This aspect of the EEC syndrome is not widely appreciated by UK physicians. Fewer than half of the cases ascertained had had a renal ultrasound scan. Occasionally UG tract anomalies may be life threatening with two of our cases requiring emergency surgery in the first few weeks of life. Painful micturition with an associated small volume bladder in case 23 was noted throughout childhood. Case 17 has recently noted similar symptoms. Several members of a Dutch family have identical symptomatology (R C M Hennekam, personal communication).

#### GROWTH AND MENTAL DEVELOPMENT

EEC syndrome has been described with severe mental retardation<sup>1 25</sup> and comparison with the syndrome described by Bowen and Armstrong<sup>35</sup> has been made. The estimate of Richiera-Costa *et al*<sup>36</sup> that 15% of cases have mental retardation (a review of 41 cases) is almost certainly an overestimate. Because the present study is cross sectional rather than longitudinal, our study of growth in the EEC syndrome has not been definitive. Low birth weight has only recently been suggested as a consistent feature of the syndrome,<sup>37</sup> but this is not confirmed in our group. Adenohypophyseal dysfunction has been described in EEC syndrome<sup>14</sup> but this was not suggested by our data.

#### SALIVARY GLANDS AND CHOANAL ATRESIA

Dental examination of case 7 showed absence of Stensens duct. This resulted in difficulty with mastication and severe dental caries owing

to reduced oral pH. Pries *et al*<sup>18</sup> reported reduced parotid secretions in a number of cases. No other cases had this problem. There were also no cases with nasal problems indicating total or partial nasal obstruction.

#### MANAGEMENT OF CASES OF EEC SYNDROME

The management of cases requires multidisciplinary action. Early syndrome diagnosis will allow parents to gain access to accurate counselling and in particular the reassuring information regarding the low risk of mental handicap. When faced with a case of EEC syndrome the paediatrician should coordinate a multidisciplinary management team including plastic surgeon, ophthalmologist, and renal specialist, etc. Children ideally should be placed on prophylactic antibiotics until renal investigation has taken place. Early audiological assessment is necessary before distraction testing becomes possible. The geneticist should be ideally involved at an early stage. Genetic counselling of families with oligosymptomatic EEC syndrome may prove very difficult as the clinician is often making a diagnosis without the complete clinical picture. Recurrence risks can usually be given to such families, but as clinical manifestation may be broad, problems with labelling are frequently encountered.<sup>37 38</sup>

The decision as to whether or not ectodermal involvement is present may be critical to diagnosis and counselling. However, establishing the presence of ectodermal involvement may not be easy; a history of slow growing hair or nails may be helpful. Magnification of nails with a hand lens in the infant with EEC syndrome looking for definite transverse ridging, nail concavity, and pitting may provide useful clues as to the presence of nail dystrophy. Interpretation of dental x rays in the infant is possible but also not easy. Cases may sometimes present as apparent lacrimal duct anomalies with orofacial clefting or with limb anomalies. The presence of recurrent ophthalmic infection or epiphora in infants with clefting or limb reduction/syndactyly indicates that subtle manifestations of ectodermal dysplasia should be sought.

Managing cases is difficult from both practical and psychological viewpoints. Severe ectodermal manifestations can be helped considerably by the use of wigs and cosmetics. Expert dental advice may preserve primary teeth (encouraging mandibular growth). Simple emollients may be satisfactory for dry skin but the two cases with painful and severe fissuring of the skin were both helped by cocoa butter based, unperfumed creams. Visual complications are particularly difficult to manage. Anticipation of recurrent infection in the early years is necessary and artificial tears may also be protective if reduced lacrimal secretions is found. Surgery for duct blockage is usually necessary. Little experience, even nationally, exists of corneal grafting (the specific corneal vascularisation in this syndrome is thought to make long term successful grafting unlikely).

Prenatal diagnosis has been achieved<sup>39</sup> but cases where a risk of fetal involvement exists must be cautioned with regards to the potential

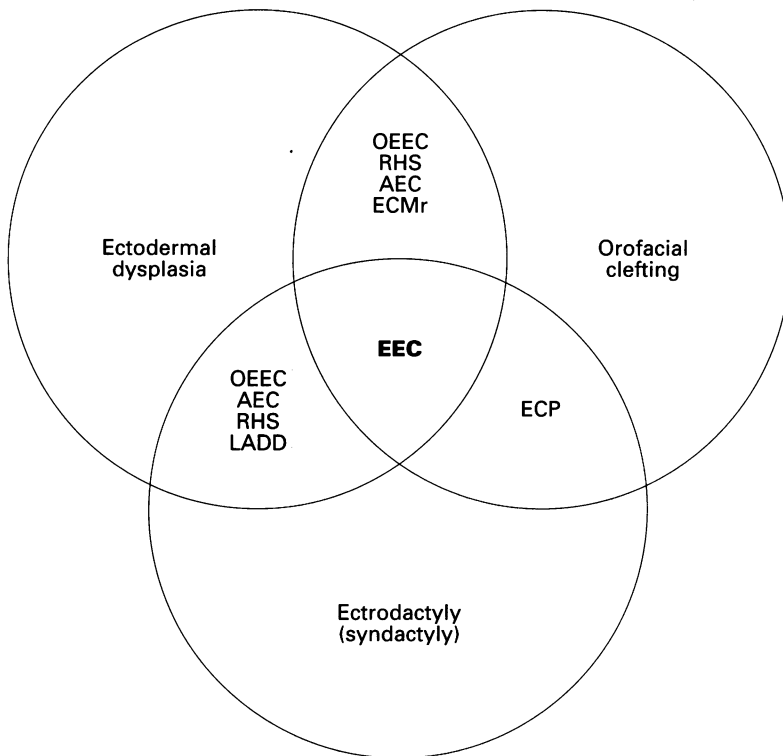


Figure 6 The phenotypic Venn: a schematic representation of the EEC syndrome in relation to other phenotypically related ectodermal dysplasias. OEEC = oligosymptomatic EEC syndrome; RHS = Rapp-Hodgkin syndrome; AEC = ankyloblepharon, ectodermal dysplasia, and clefting syndrome; ECMr = ectodermal dysplasia, cleft palate, and mental retardation syndrome; LADD = lacrimoauricular-dento-digital syndrome; ECP = ectrodactyly-cleft palate syndrome.

difficulties in identifying affected fetuses in a condition with such a variable presentation.

Other syndromes with overlapping features, such as the Rapp-Hodgkin syndrome and the AEC syndrome, have several features in common with the EEC syndrome but are thought to have distinctive characteristics. Rodini and Richiera-Costa<sup>40</sup> discussed the clinical diagnostic criteria in a review of the EEC syndrome, indicating that relatively minor differences between the disorders confers separate syndromic status. In the authors' view this group of disorders can be considered as points on a phenotypic Venn diagram (fig 6).

#### MOLECULAR CONSIDERATIONS

Embryologically, the cluster of features seen in the EEC syndrome may be explained by anomalies of ectodermal/mesodermal interaction. The skin, nails, teeth, palate, limbs, salivary glands, and lacrimal duct have similar developmental profiles, developing either as intrusions of embryonic ectoderm into underlying mesenchyme or showing crucial reliance of ectoderm on underlying mesodermal signalling. A rational aetiological classification of the autosomal dominant ectodermal dysplasias with distal limb deficit orofacial clefting awaits the outcome of collaborative studies which may elucidate their molecular basis. Candidate chromosomal regions include 7q21.3 (identified as a prime locus for ectrodactyly<sup>41</sup>), 7q11, and 9p21 (identified as breakpoints in family with a translocation and

EEC syndrome).<sup>32</sup> Other possible candidate genes for such a syndrome could include transforming growth factors alpha and beta (possibly involved in palatogenesis<sup>42,43</sup>) and also homeobox genes (particularly MSX1 and MSX2, implicated in ectodermal mesodermal interaction in developing limbs,<sup>44,45</sup> teeth,<sup>46</sup> and palate<sup>47</sup>).

Contiguous genes may be involved in producing the EEC phenotype. Allelic heterogeneity at a single locus could also explain the considerable overlap between the EEC and other syndromes. Until we have a clearer understanding of the molecular basis of the EEC syndromes and similar disorders, difficulty will remain in their classification and hence in the practicalities of making a firm diagnosis.

Dr Buss wishes to acknowledge that his work on EEC syndrome was undertaken while Action Research Training Fellow in Medical Genetics based at the Institute of Medical Genetics, UWCM, Cardiff.

- Rudiger R, Haase W, Passarge E. Association of ectrodactyly, ectodermal dysplasia and cleft lip and palate. *Am J Dis Child* 1970;120:160-3.
- Cockayne E. Cleft palate, hare lip, dacrocystitis and cleft hand and feet. *Biometrika* 1936;28:60-1.
- Walker J, Clodius L. The syndrome of cleft lip and lobster claw deformity of hands and feet. *Plast Reconstr Surg* 1963; 32:627-36.
- Rosselli D, Gullinetti R. Ectodermal dysplasia. *Br J Plast Surg* 1961;14:190-204.
- Rapp R, Hodgkin W. Anhidrotic ectodermal dysplasia. *J Med Genet* 1968;5:269-72.
- Hay RJ, Wells RS. The syndrome of ankyloblepharon, ectodermal dysplasia and cleft lip and palate. *Br J Dermatol* 1976;94:277-89.
- Kuster W, Majewski F. EEC syndrome without ectrodactyly. *Clin Genet* 1985;28:130-5.
- Majewski F, Kuster W. EEC syndrome sine sine. *Clin Genet* 1988;33:60-72.
- Penchaszadeh VB, de Negrotti TC. Ectrodactyly, ectodermal dysplasia and clefting syndrome (EEC)—dominant inheritance and variable expression. *J Med Genet* 1976;13:281-4.
- Wallis C. Ectrodactyly and ectodermal dysplasia with normal lip and palate in a four generation kindred. *Clin Genet* 1988;34:252-7.
- Preus M, Fraser FC. The lobster claw defect with ectodermal dysplasia cleft lip and palate, tear duct anomaly and renal anomalies. *Clin Genet* 1973;4:369-75.
- Christodolou J, McDougall P. Choanal atresia as a feature of the EEC syndrome. *J Med Genet* 1989;26:586-9.
- Knudtzon J, Aarskog A. Reduced growth hormone secretion in the EEC syndrome and isolated septum pellucidum. *Pediatrics* 1987;79:410-12.
- Ostorharics-Horvath G. EEG abnormality in EEC syndrome. *Orvosi Hetilap* 1989;41:2211-12.
- Freire Maia N, Pinheiro M. *The ectodermal dysplasias*. New York: Alan Liss, 1989.
- Holbrook K. Ultrastructural findings in the ectodermal dysplasias. *Birth Defects* 1988;24(2):50-65.
- Temtamy S, McKusick V. *The genetics of hand malformation*. New York: Alan Liss, 1978.
- Pries C, Mittelman D, Miller M, Pashayan HM, Pruzansky S. The EEC syndrome. *Am J Dis Child* 1974;127:840-4.
- De Silva EO, Alves JG, Almieda E. Is the EEC syndrome genetically heterogeneous? *Rev Bras Genet* 1984;4:735-42.
- Rogmanoli G, Zunin C. L'associazione displasia ectodermica ectrodactilia e labio palatoschisis la sindrome EEC. *Pathologica* 1974;66:95-104.
- Psaume J, Gray F. EEC syndrome report on 12 cases. *Rev Stomatol (Paris)* 1981;82:226-9.
- Salinas C, Marcos Montes G. Rapp-Hodgkin syndrome—ten cases and characteristic hair changes. *Birth Defects* 1988;24(2):149-68.
- Clarke A, Phillips D, Harper P. Clinical aspects of X linked hypohidrotic ectodermal dysplasia. *Arch Dis Child* 1987; 62:989-96.
- Brill CB, Hsu LYF, Hirschhorn K. The syndrome of ectrodactyly ectodermal dysplasia and cleft and palate. A report of a family demonstrating dominant inheritance. *Clin Genet* 1972;3:295-302.
- Swallow JN, Gray OP, Harper PS. Ectrodactyly ectodermal dysplasia and cleft lip and palate (EEC syndrome). *Br J Dermatol* 1973;89:54-6.
- Clouston HR. The major forms of hereditary ectodermal dystrophy. *Can Med Assoc J* 1939;40:1-7.
- Freid K. Ectrodactyly, ectodermal dysplasia and clefting syndrome. *Clin Genet* 1972;3:396-400.
- NcNab A, Potts M, Welham A. EEC syndrome and its ocular manifestations. *Br J Ophthalmol* 1989;73:261-4.

- 29 Schmidt M, Salzano FM. New case of an EEC-like syndrome in twins. *Acta Genet Med Gemellol* 1988;37:347-50.
- 30 Hollister DW, Klien SH, Dejager HJ, Lachman RS, Rimoin D. The lacrimo auricular dento digital syndrome. *J Pediatr* 1973;83:438-44.
- 31 Robinson G, Wildervanck LS. Ectrodactyly, ectodermal dysplasia and cleft lip and palate syndrome. *J Pediatr* 1973;3:107-9.
- 32 Hasegawa T, Hasegawa Y, Asamura S, et al. EEC syndrome with a balanced reciprocal translocation between 7q11.21 and 9p21 in three generations. *Clin Genet* 1991;40:202-6.
- 33 Anneren G, Andersson T, Lindgren PG. EEC syndrome—the clinical variation and prenatal diagnosis. *Clin Genet* 1991;40:257-62.
- 34 Rollnick BR, Hoo J. Genitourinary anomalies are a component of the EEC syndrome. *Am J Med Genet* 1987;29:131-6.
- 35 Bowen P, Armstrong HB. Ectodermal dysplasia, mental retardation, defects of lip and palate and other anomalies in three siblings. *Clin Genet* 1985;9:35-42.
- 36 Richiera Costa A, Vilhena Mores S, Ferrareto I, et al. Ectodermal dysplasia ectrodactyly in monozygotic twins. Report of a case—review and comments on the ectodermal dysplasia, ectrodactyly (cleft lip, palate) syndromes. *Rev Bras Genet* 1986;9:39-47.
- 37 Tse K, Templer IK, Baraitser M. Dilemmas in counselling. The EEC syndrome. *J Med Genet* 1990;27:752-5.
- 38 Sybert V. Early diagnosis in the ectodermal dysplasias. *Birth Defects* 1988;24(2):277-8.
- 39 Kohler R, Sousa P, Jorge C, et al. Prenatal diagnosis of the EEC syndrome. *J Ultras Med* 1989;8:337-9.
- 40 Rodini ESO, Richiera-Costa A. EEC syndrome: 20 new cases. *Am J Med Genet* 1990;37:42-5.
- 41 Buss PW. Cleft hand/foot: clinical and developmental aspects. *J Med Genet* 1994;31:726-30.
- 42 Ardinger H, Buetow KH, Bell GI, Bardach J, et al. Association of genetic variation of the TGFA gene with cleft lip and palate. *Am J Hum Genet* 1990;45:345-8.
- 43 Fitzpatrick D, Denhez F, Kendoaih P, et al. Differential expression of TGFB isoforms in murine palatogenesis. *Development* 1990;109:585-95.
- 44 Izpisua-Belmonte J, Tickle JL, Dolle P, et al. Hox expression in the specification of position in chick wing development. *Nature* 1991;350:585-9.
- 45 Benoit R, Lyons G. The apical ectodermal ridge regulates Hox 7 and Hox 8 gene expression in developing chick limb buds. *Genes Dev* 1991;5:2363-74.
- 46 McKenzie A, Leeming GL, Jowett AK, Ferguson MWJ, Sharpe PT. Human Hox 7 in regional and temporal expression in craniofacial and tooth development. *Development* 1991;111:269-85.
- 47 Satokata I, Maas R. MSX1 deficient mice exhibit cleft palate and abnormalities of craniofacial and tooth development. *Nature Genet* 1995;9:173-8.