

**YMTHE, Volume 31**

**Supplemental Information**

**Epithelioid neoplasm of the spinal cord  
in a child with spinal muscular atrophy treated  
with onasemnogene abeparvovec**

**Laura Retson, Nishant Tiwari, Jennifer Vaughn, Saunder Bernes, P. David Adelson, Keith Mansfield, Silvana Libertini, Brent Kuzmiski, Iulian Alecu, Richard Gabriel, and Ross Mangum**

SUPPLEMENTAL MATERIAL

SUPPLEMENTAL FIGURES

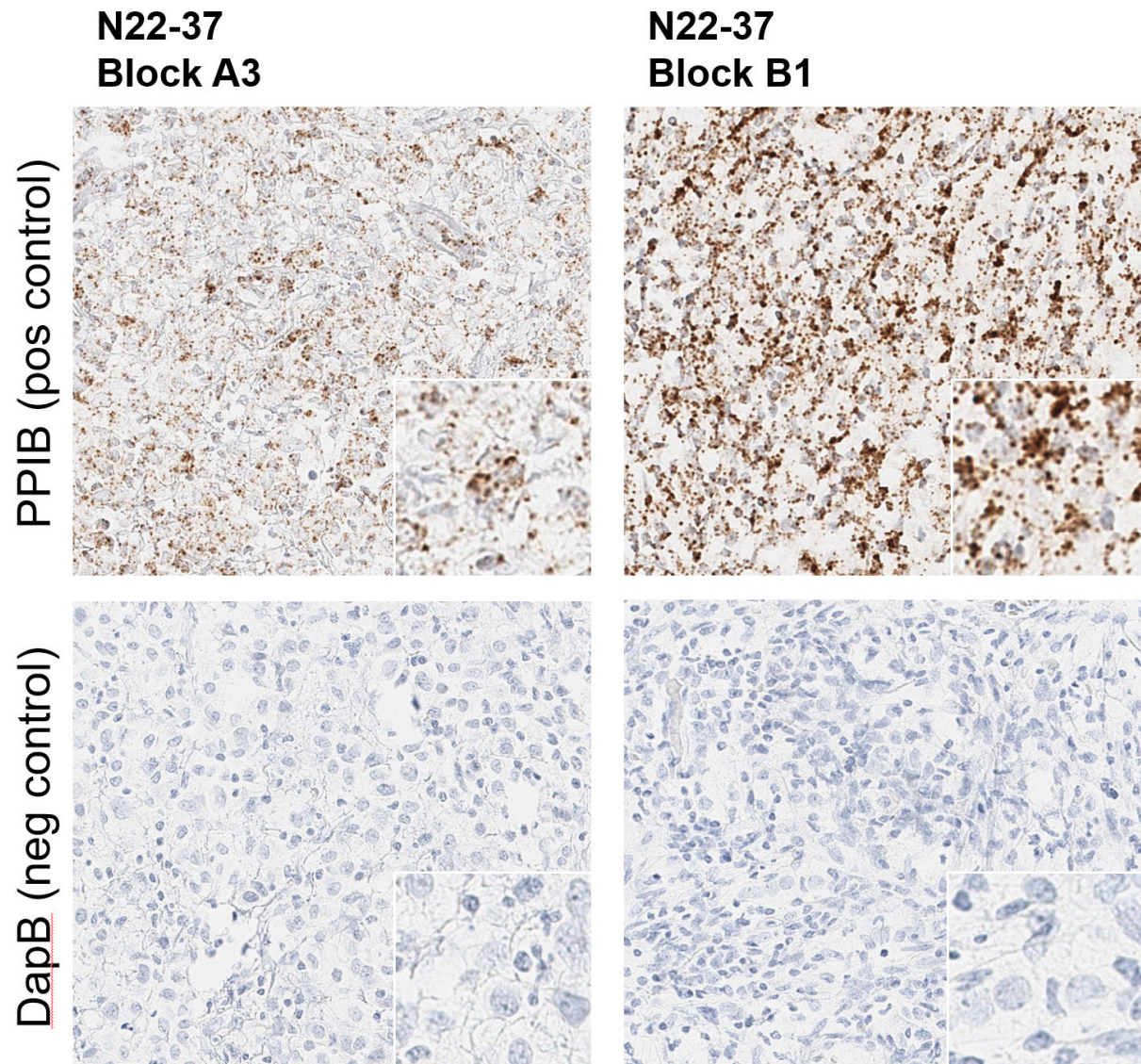


Figure S1. *In situ* hybridization for tissue positive (PPIB) and negative (DapB) controls.