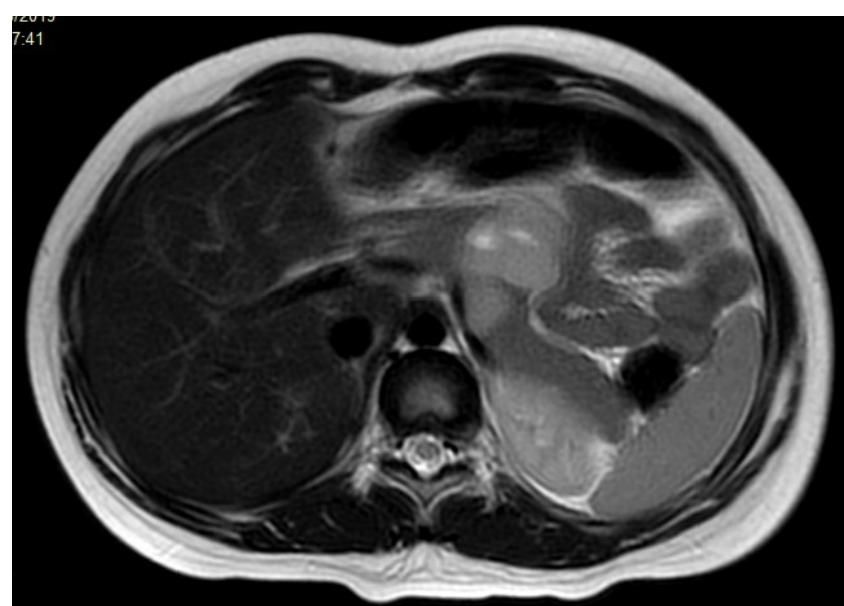
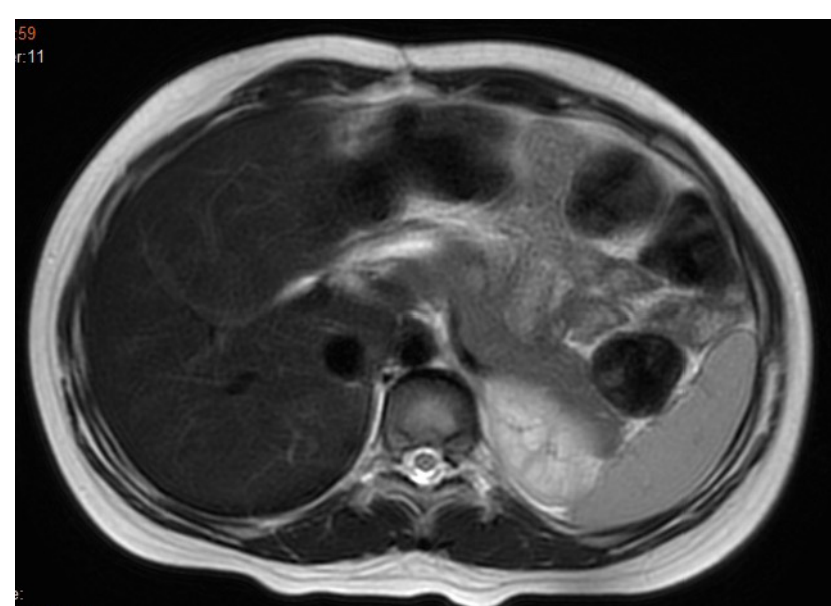


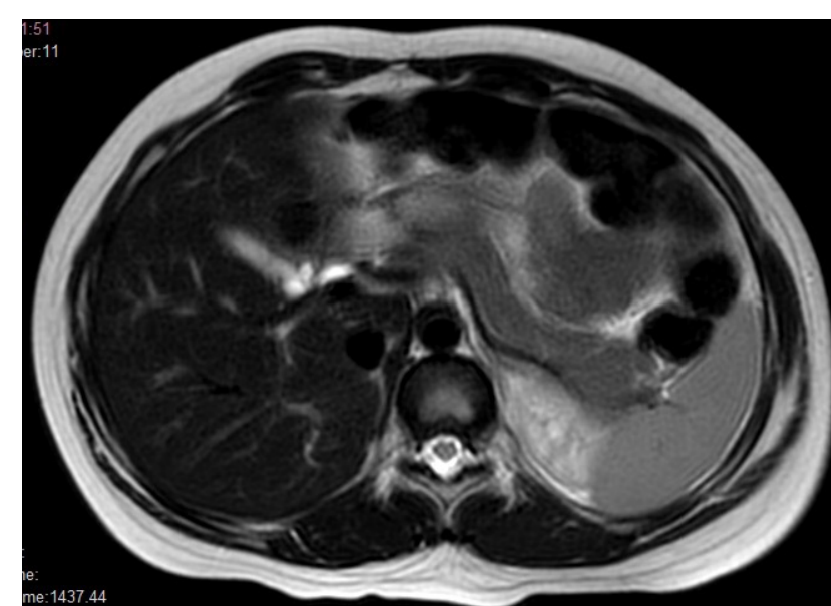
Supplementary Figure 2. Progressive reduction of tumor size in a patient with metastatic alveolar rhabdomyosarcoma treated with regorafenib 82 mg/m² plus VI (sequential) following a fourth disseminated relapse.



Baseline (March 2019)



PR (April 2019)



CR (July 2020)

CR, complete response; PR, partial response; VI, vincristine and irinotecan.