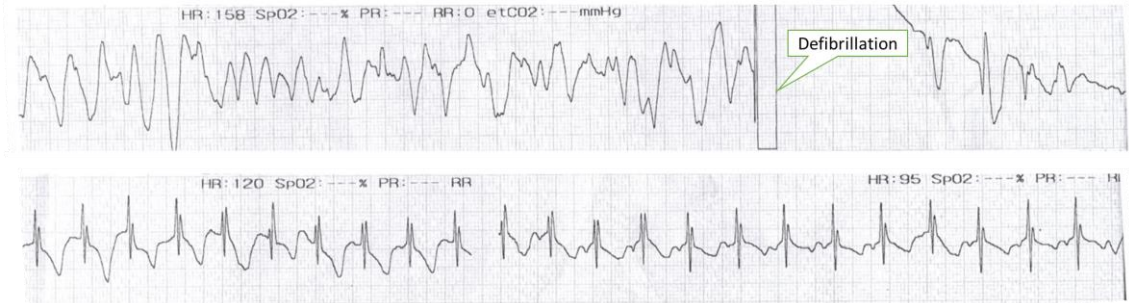


1 **Supplemental Fig. S1**

2 Ventricular fibrillation detected on the electrocardiogram monitor.



3

4