

Short Notes and Clinical Cases.

A CASE OF TORSION-DYSTONIA, OR TORSION-SPASM.

BY M. A. BLANDY, LONDON.

It is only in the last ten or twelve years that the disease known as torsion-spasm or torsion-dystonia (*dystonia musculorum deformans*) has been differentiated. Some forty cases are already on record, most of which have been reported either in Germany or in America. Of the total number, only five have occurred in non-Jewish families. As far as I am aware, the following case is the first of this curious condition to be observed in England. For that reason, and because of the desirability of directing attention to a little-known disease of somewhat serious import, it appears worthy of being recorded.

Clinical History.—H. R., male, age 8, was an in-patient at the National Hospital, Queen Square, London, under the care of Dr. James Collier, from February to June, 1920.

The mother was healthy, with no history of miscarriages, or of a similar complaint in her family; the father had 'bronchial asthma and a wasted lung', and his sister had chorea after rheumatic fever. His grandmother, mother, aunt, and two uncles all had enlarged thyroids, though they were London-bred. The aunt eventually died of Graves' disease, of which none of the others had symptoms. No Jewish or Polish descent could be traced on either side of the family.

The patient, the eldest of three, of whom the third, a boy of four, was said to have a weak heart, was a full-term child by normal labour. He was breast-fed for nine months, and began to walk and talk at eleven months. Shortly before his fourth birthday he suffered from diphtheria, and when about five years old he stopped growing.

He was a bright and normal child until six months after the attack of diphtheria, when his mother noticed he used to throw out his right arm away from his side, as though, she thought, he were trying to urge his jersey up his arm to make it comfortable. A week or two later 'the use went out of his hands', while the involuntary movements ceased. Electrical treatment was given them for six months without much improvement. Twelve months later involun-

tary movements of the tongue and head started, described by his mother as 'throwing his tongue out and his head about'.

In May, 1918, he had an attack of measles; he was treated at home and was noticed to use his hands again for a week after he got up, but 'lost the use' once more, i.e., did not use them properly. In June, 1918, he was admitted to the National Hospital, but was discharged two days later with a rash erroneously supposed at that time to be measles. However, it was subsequently learned that the boy had had a rash on his back at intervals since the age of four or five, which still continued. Jerking movements of the trunk on the legs were first observed in February, 1919, and led to his admission to St. George's Hospital under the care of Dr. James Collier. The notes then taken specify the perverse movements of the hands, the protrusion of the tongue, rotation and extension of the head, and, when he lay on his back, the involvement of the trunk muscles. During and after meals the movements were worse. While in the hospital he developed a follicular rash, culminating in pustule-formation and attended by slight rise of temperature and increase in pulse-rate, of four days' duration. The hand and face movements were said to have improved, whereas the trunk movements became more severe.

Three weeks after his discharge his mother said he began to jerk his tongue in and out, so that food was thrown out of his mouth, while the movements of his hands made it impossible for him to feed himself. This state of affairs obtained until five weeks before admission to the National Hospital, when he was knocked down by a bicycle. On being picked up he was quite stiff, with legs extended, arms stretched down, and back arched; he was not unconscious, as he spoke to his mother, yet each time he was set on his feet to walk he fell down, and he remained off his feet for three days. During this time the movements became very violent, and they continued so up to the date of admission. Feeding became extremely difficult; his food was placed in the right side of his mouth, since it thus appeared to be more easily swallowed, but solids had to be cut up into small portions, and only a few drops of fluid could be taken, the rest being spilled out of his mouth.

For three weeks before admission there had been great difficulty in starting the act of defæcation; he would stand up for some time before passing anything, and, when asked why, replied, "I can't help it". The bowels were usually constipated.

Attention and excitement aggravated the involuntary movements, which were always worse in bed, preventing him from getting to sleep. To accomplish this he commonly turned on his face and put his right hand behind him. When on his feet he often tucked his left hand behind his back.

The child had never been to school, but he knew his A B C, could count, and was mentally quick and alert. Naturally of a happy disposition, he had shown occasional bad temper since the accident, shrieking and stamping his feet.

State on Admission.—The boy was distinctly small for his age, with a dolichocephalic head (circumference 21 in.), which appeared large in proportion to the smallness and thinness of his body. The joints were normal, and no lordosis was seen in the position of rest. A pale and sallow child, with adenoid facies, towards the end of his stay in hospital he became slightly yellowed as with cachexia, but no jaundice was ever present, nor was pigmentation of the corneo-scleral junction found. His skin was subject to frequent crops of punctate erythema and papillitis, and in addition there were occasional pustules on the upper trunk. The cervical lymph-nodes were enlarged, and those of the axillæ and groins palpable but not enlarged. His teeth were bad and the gums unhealthy. A high-arched palate and small cryptic tonsils were accessory to the presence of adenoids, though the boy was a nose-breather.

The area of hepatic dullness was slightly diminished and the liver edge impalpable; nor was the spleen enlarged, though complaint was occasionally made of pain in that region. Cardiac and respiratory systems were normal. The boy ate largely, and frequently complained of thirst. It was always an effort for him to evacuate the bowels, in spite of regular aperients for the constipation; it took sometimes as long as twenty minutes to accomplish the act, the child standing throughout. With micturition he appeared to have no difficulty. The urine was normal, but concentrated owing to the loss of fluids from his system by way of the skin, as he sweated profusely during the intense muscular exertions of his malady. No rise of temperature occurred during his stay in hospital.

Mentally the patient was intelligent, perhaps rather in keeping with his size than his years, but this was attributable to his lack of school education and to his home environment. At times obviously dazed by physical exhaustion, he was otherwise bright, amiable, obedient, emotionally normal, and an excellent witness.

In his speech, which was normal except for the pronunciation of 'th' and 'm', he paid no attention to his convulsed condition, but carried on a conversation in a detached manner, despite the fact of his words and phrases being punctuated with deep silences due to involvement of the muscles of respiration in the spasms.

The cranial nerves were normal, the optic discs clear; sensibility was unimpaired. Tendon-reflexes were normal, or possibly slightly diminished; the abdominals were active and the plantars invariably flexor.

The muscular system was of normal development on admission, but some hypertrophy of those muscles most in action appeared before discharge. During the intervals of relaxation a considerable degree of hypotonia was present, especially in the upper limbs; the wrists, e.g., could be bent into almost any position; tonelessness of the abdominal wall showed itself in a rather prominent abdomen, and of the legs in a mild degree of genu recurvatum. Tremor and ataxia were conspicuous by their absence. Power was fair and equal on the two sides; the finer movements of the hands were awkward and slow. He would pick up a penny, either between the backs of the proximal phalanges of the first two fingers of either hand, or awkwardly between thumb and middle finger; as a general rule his hands maintained the attitude of flattened fists, out of which he would cautiously protrude the middle finger to execute any little act.

Any voluntary movement he was asked to perform he would cleverly insert in the brief intervals between his contortions, and he would obviously wait for the moment of relief and deftly snatch it when it came. For varying intervals of time, generally when interested in something, he would assume an almost natural posture, whereas at his worst he could not carry out any act requiring more than a moment of time, being wrested remorselessly from it as though impelled by an invisible power.

In general, the involuntary movements were of a clonico-tonic, tic-like character; they were clown-like, grotesque, bizarre, the most remarkable feature being the extreme lordosis and twisting of the spine. With the course of the disease the tonic element became more, and the clonic element less, pronounced. At first they were comparatively slight (*Fig. 1*), but they steadily became more severe. The full maturity of the spasm, attained during the last three weeks of his stay in hospital, was as follows (*Figs. 2, 3*). A sudden violent extension of the head pulled it back and to the left, so that the occiput touched the back of the left shoulder, at the same time as the tongue was hyperprotruded a little to the left of the mid-line and the eyes conjugately deviated to the right and down, the patient as far as




FIG. 1.—February, 1920. Mild stage. Note extension and pronation (torsion), especially of left arm.

possible still looking forwards; the lids closed towards the end of this movement, the forehead wrinkled, and the left jaw and left facial muscles contracted. The head then described a rotatory course across the shoulders to the right, maintained this attitude for a few seconds, then as it returned to the mid-position the shoulders were thrown back, the whole trunk taking on an acute lordosis, with scoliosis to the left in its upper part, the right arm extended at shoulder and elbow, overpronated at wrist, with fingers and thumb flexed into a flattened fist, or occasionally extended. The left arm

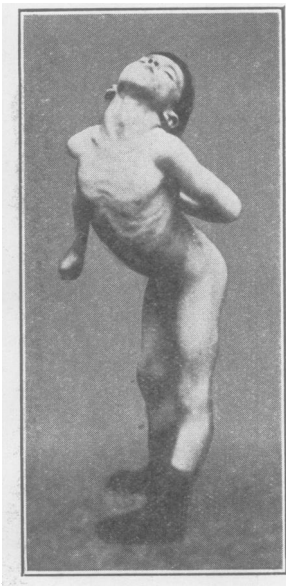


FIG. 2.—June, 1920. Moderately severe stage. Note how arm is thrown behind back.




FIG. 3.—June, 1920. Note torsion of right arm.

was almost invariably carried behind the child's back, i.e., extended at shoulder, flexed at elbow, pronated and partly extended at wrist, with fingers in a fist as on the opposite side. During the intermissions he habitually walked about with his left arm in this attitude.

The respiratory muscles were implicated in the spasm intermittently, without dissociation, and the abdominals were affected simultaneously with the overacting erector spinæ, against which they were powerless; the contraction, nevertheless, was visible, and frequently affected one quadrant more than another.

Occasionally the flexors of the hip acted synchronously with the

lordosis-producing group, the whole effect, as may be imagined, being grotesque. If the child were seated with feet off the ground, his lower limbs took part in the general spasm, being abducted and extended, the left more than the right, the toes pointing down and the feet a little inverted. When he stood the legs were not involved, and he admitted he always felt easier thus.

With observation or any attempt at passive restraint, even as slight as that of putting him to bed, the movements increased; once he was off to sleep they stopped. His gait was normal, and if occasionally interrupted by a spasm it never threw him down.

If allowed to try to feed himself he spent time and effort with poor success; he filthied himself and everything around him, as a spasm would overcome him when he had a spoonful in his hand, and it would be flung freely in any direction. He was fed with difficulty between the spasms, with minced food or slops, since he was unable to masticate.

The cerebrospinal fluid was in all respects normal, and the Wassermann tests were negative.

Remarks.—There is no doubt that this is a case of torsion-dystonia. The extreme lordotic, spine-twisting, clownish contortions are identical with those described by Mendel in his monograph (see this Journal, No. 1, p. 86). The variations in muscle tone, the absence of pyramidal involvement and of intellectual impairment, the progressive nature of the affection, are typical of the disease in question. That the face has not escaped does not refute the diagnosis, since in several of the recorded cases 'grimacing' has been observed. Five cases have been noted in Gentiles, although the condition is, like Tay-Sachs' disease, ordinarily confined to Polish Jews, and the case now reported constitutes a sixth.

The attitudes of the trunk and head in extension, and the extremely frequent, though transient, postural fixation of the arms in extension and hyperpronation (*see Figs. 1, 3*), are, it is interesting to note, the same as those described by Dr. Kinnier Wilson, in his paper on decerebrate rigidity in man, as obtaining when the cortex is in functional abeyance and cerebello-mesencephalo-spinal centres come into involuntary action.

One glance at the patient is sufficient to dispose of a diagnosis of hysteria or of convulsive tic. That there is some causal toxic agent at work, probably of alimentary origin, may be inferred by the fact that very shortly after the onset of the first symptoms the child stopped growing, and developed an intermittent rash of toxic character, enlarged lymph-nodes, and sallow appearance.

The only autopsy as yet described in the literature was made

by Thomalla (see this Journal, No. 1, p. 87), who found cirrhosis of the liver and bilateral softening of the putamen. Mendel considers Thomalla's case to belong definitely to progressive lenticular degeneration or to pseudosclerosis, and not to torsion-spasm. From physiological considerations, however, it seems clear that the pathogenesis of the involuntary movements in the latter is to be ascribed to release of non-cortical motor activity whose anatomical seat is in the mesencephalo-spinal centres already alluded to.

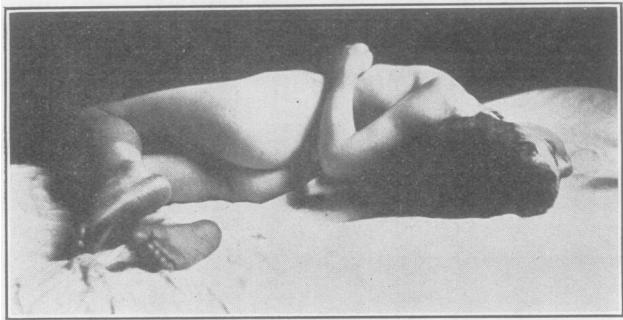


FIG. 4.—August, 1920. Severe stage.

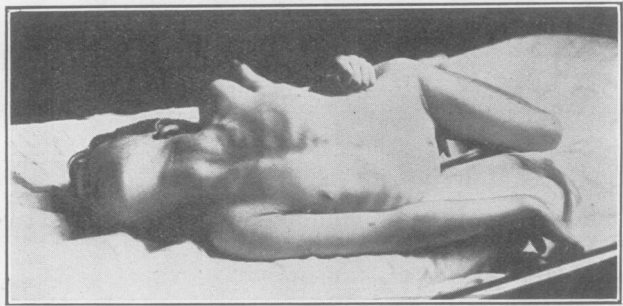


FIG. 5.—August, 1920. Severe stage. Note extreme extension of right leg on trunk. The right foot is visible beyond thorax.

My thanks are due to Dr. James Collier for his kindness in allowing me to publish the case, which is under his care, and for giving me access to all notes in his possession. I also wish to thank Dr. Kinnier Wilson for acquainting me with the disease, and for his unfailing help and inspiration.

ADDENDUM (*July 30, 1920*).

The patient has to-day been re-admitted. His mother reports that he has become much worse. He is unable to rest in bed, and

for the last week has tried without success to sleep standing upright, as this attitude is the only one that stabilizes the movements.

On examination the child is seen to be utterly exhausted physically, but is still intelligent and obedient. While the face movements are now scarcely in evidence, lordosis is too mild a term to apply to the violent opisthotonic convulsions that rack his frame. They are infinitely worse when lying down. Photographs of him in bed are appended, and they need no description (*Figs. 4, 5*).

BIBLIOGRAPHY.

- MENDEL, *Monats. f. Psychiat. u. Neurol.*, 1919, xlii, 309 (contains complete résumé of literature to date of publication).
ABRAHAMSON, *Jour. Nerv. and Ment. Dis.*, 1920, li, 451.
KINNIER WILSON, "On Decerebrate Rigidity in Man, and the Occurrence of Tonic Fits", *Proc. Roy. Soc. Med. (Neurol. Sect.)*, 1920.