

#### Appendix 4. ACLOAS Grades on MRI at 3 and 6-month follow-up (complete case analysis)

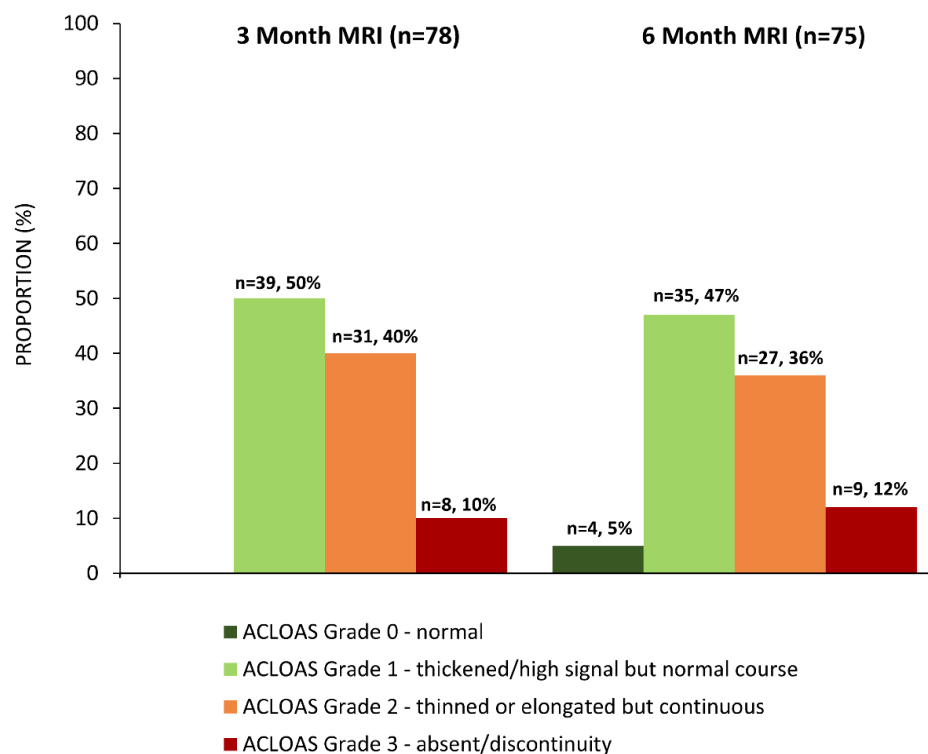


Figure 1: MRI evidence of ACL healing at 3- and 6-month follow-up

There is missing data from n=2 at 3 months (decided not to undergo MRI, n=2), and n=6 at 6 months (due to ACL re-rupture (n=3), pregnancy (n=1), or decided not to undergo MRI (n=2))