

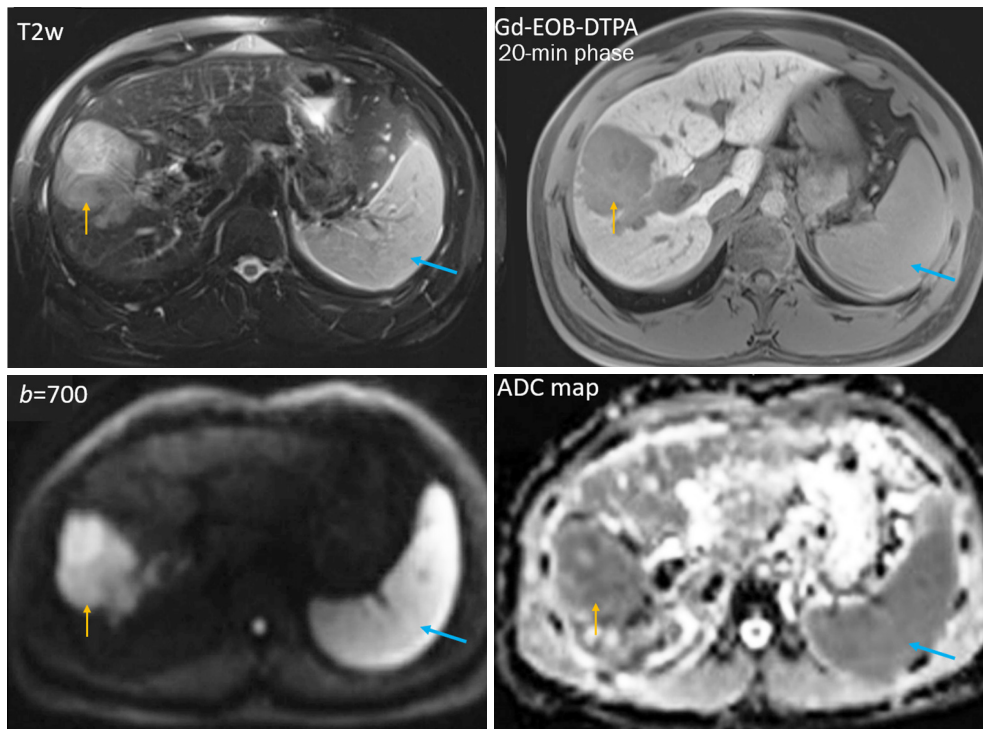Figure S1 T2w, T1-weighted Gd-EOB-DTPA enhanced 20-minute hepatobiliary phase, diffusion weighted ($b=700 \text{ s/mm}^2$) MR images, and ADC map of the liver, a hepatocellular carcinoma (orange arrow) and the spleen (blue arrow). Though the tumor has heterogeneous structures, it appears that the tumor and the spleen show many signal similarities on these four images, with lower ADC value for the spleen and the tumor than for the liver. The lower spleen ADC value than the liver ADC value is likely due to a quantification error as described in this letter. Reproduced from Cao *et al.* (17). T2w, T2-weighted; Gd-EOB-DTPA, gadolinium ethoxybenzyl diethylenetriamine pentaacetic acid; ADC, apparent diffusion coefficient; MR, magnetic resonance.

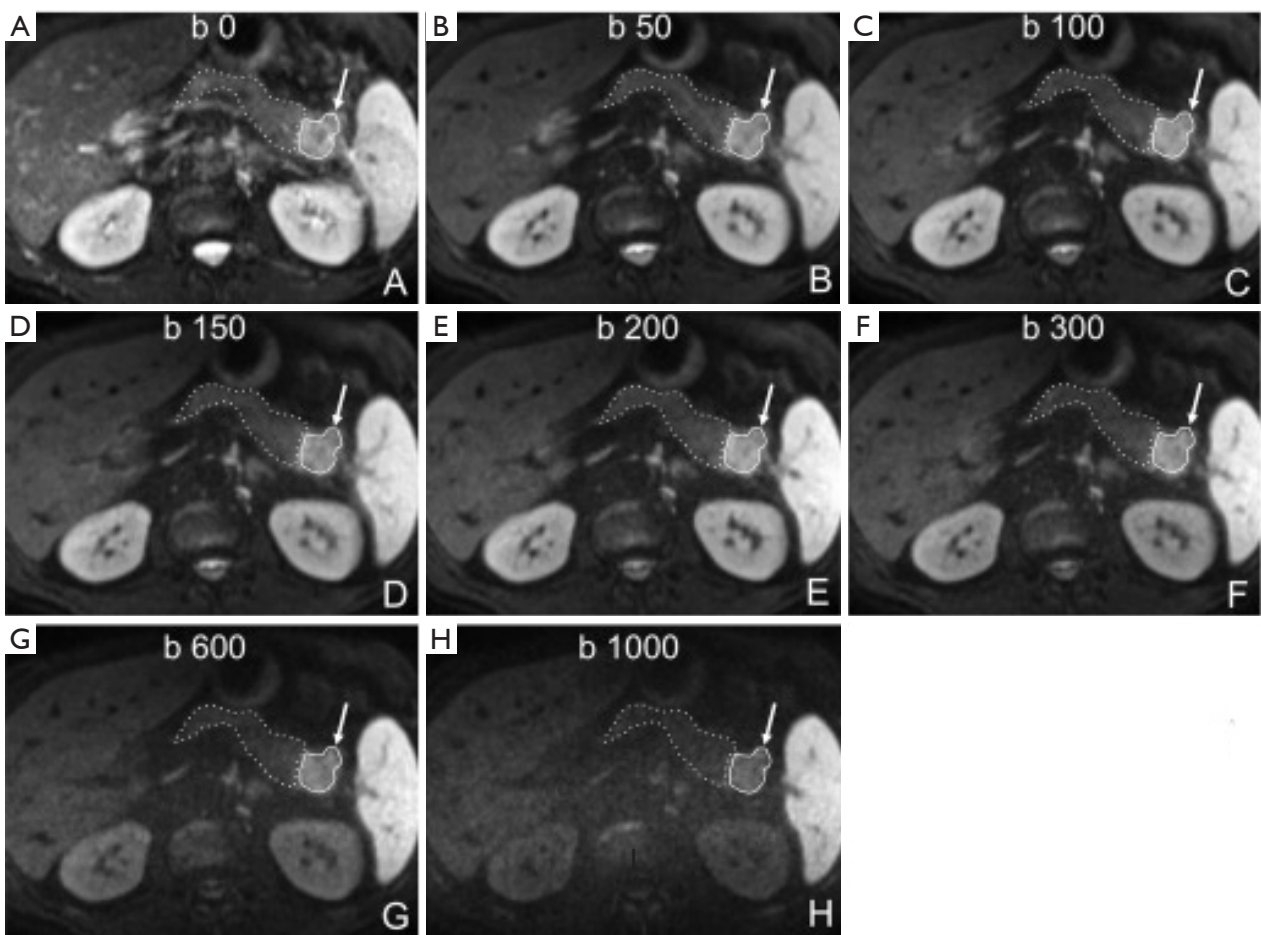


Figure S2 Pancreas ductal adenocarcinoma is associated with increased T2 time and decreased ADC. A 65-year-old male patient with a ductal adenocarcinoma at the pancreatic tail. (A-H) Axial DWI images with increasing b -values from 0 to 1,000 s/mm^2 . Restricted diffusion of the tumour (arrow, continuous line) compared to the adjacent parenchyma (dashed line). The tumor shows relative high signal as compared to adjacent pancreas parenchyma on $b=0$ image (when diffusion gradient was not on), suggesting its increased T2 time. The signal change of the pancreas is close to that of the liver, while the tumor shows signal more closer to that of the spleen. At 3T, the T2 time is estimated to be 34, 43, and 61 ms for liver, pancreas, and spleen, respectively (4). Reproduced from Kartalis *et al.* (18). ADC, apparent diffusion coefficient; DWI, diffusion-weighted imaging; ms, millisecond.