

The neck-tongue syndrome

Richard W Orrell, C David Marsden

Abstract

The neck-tongue syndrome, consisting of pain in the neck and altered sensation in the ipsilateral half of the tongue aggravated by neck movement, has been attributed to damage to lingual afferent fibres travelling in the hypoglossal nerve to the C2 spinal roots. The lingual afferents in the hypoglossal nerve are thought to be proprioceptive. Two further cases of the neck-tongue syndrome are described, the spectrum of its clinical manifestations is explored, and the phenomenon of lingual pseudoathetosis is illustrated as a result of the presumed lingual deafferentation.

(*J Neurol Neurosurg Psychiatry* 1994;57:348-352)

Lance and Anthony¹ described four patients, aged 8 to 14 years at onset, with a brief (seconds to a minute) sharp pain on one side of the upper neck or occiput on sudden rotation of the neck, followed immediately by transient (seconds to minutes) ipsilateral numbness of the tongue. Two of these cases had congenital anomalies of the upper cervical spine on radiography. Cyriax² had previously noted a similar syndrome in two patients, one of whom was a 45-year-old woman with attacks of severe pain at the occiput and left side of the neck and numbness of the tongue and back of the palate, precipitated by turning her head sharply to the right. The other patient had a cervical disc lesion and a sensation of pins and needles felt in the tongue only.

Lance and Anthony¹ concluded that the pain was due to irritation of the second (and third) cervical root, which is vulnerable to compression in its course between the atlas and axis during neck rotation. They explained the unilateral numbness of the tongue on the basis of afferent impulses (notably, proprioceptive) travelling from the lingual nerve via the hypoglossal nerve to the second cervical root.

Bogduk³ clarified the anatomical basis for the syndrome by cadaveric dissection, demonstrating that the C2 ganglion and spinal nerve lie dorsal to the lateral atlantoaxial joint; the joint is innervated by the C2 ventral ramus. He proposed that the pain was due to temporary abnormal subluxation of the lateral atlantoaxial joint on rotation of the head. This strains the joint capsule, and thereby causes pain in the suboccipital

region. He attributed the unilateral numbness of the tongue (and of the skin behind the ear) to compression of the C2 ventral ramus by movement or subluxation of the lateral atlantoaxial joint. He suggested that the abnormal sensation on compression of proprioceptive afferents from the tongue is similar to the altered sensation or numbness recognised in Bell's palsy, despite intact trigeminal sensation, due to compression of proprioceptive fibres in the facial nerve.

Since these original descriptions of the neck-tongue syndrome, a few other cases have been described. Lance⁴ briefly mentions a further four patients in whom the syndrome started in late childhood or adolescence. Elisevich *et al*⁵ reported a 53-year-old woman with assimilation of the atlas to the occiput presenting with neck pain and ipsilateral paraesthesiae of the tongue on head turning, in whom the symptoms became persistent and incapacitating. At operation, the C2 spinal nerves were found to be compressed by a protuberant atlantoaxial joint. Resection of the superficial parts of the C2 spinal nerves led to partial relief.

Webb *et al*⁶ described three cases with ipsilateral neck pain and tongue numbness precipitated by neck movement, first developing symptoms at ages of 10 to 61 years. Degenerative changes of the anterior atlantoaxial joint were present in two of the cases. Restriction of neck movement, including use of a surgical collar in two of the cases, controlled the symptoms.

Fortin and Biller⁷ described a 57-year-old woman with repeated episodes of numbness of the posterior right half of the tongue and right posterolateral oropharynx, an ipsilateral "ear pressure", and a sharp aching pain radiating along the border of the trapezius to the acromioclavicular joint. At the same time she noticed a pressure sensation in the occiput and paraesthesiae in the fourth and fifth fingers of the right hand. The episodes lasted one minute, and she herself noted no clear precipitant, but they were precipitated by extreme lateral rotation of the neck. The region of the atlantoaxial joint was normal radiologically. They also described a 29-year-old man, with previous head injury and lower thoracic vertebral compression fracture after a motorcycle accident, who complained of mainly right, but sometimes left sided (never both sides simultaneously), hemiglossal and facial paraesthesiae, sharp occipital pain shooting to the periorbital area, dysarthria, nasal

University
Department of
Clinical Neurology,
The National
Hospital, Queen
Square, London
WC1N 3BG, UK
R W Orrell
C D Marsden

Correspondence to:
Dr R W Orrell.

Received 14 April 1993
and in final revised form
14 June 1993.
Accepted 21 June 1993

congestion, sialorrhoea, and paraesthesiae in the ulnar distribution of the upper limb. The symptoms in both patients were relieved by use of a surgical collar.

Bertoft and Westerberg⁸ reported a further six patients with a complete syndrome, and three with an incomplete syndrome, which they define as having characteristic attacks, but lacking the paroxysmal numbness of the tongue. We have not included these cases of an incomplete syndrome in the present discussion, but two of the patients with a complete syndrome had radiological evidence of arthritis of the lateral atlantoaxial joints, and in one the symptoms were abolished after surgical atlantoaxial fusion.

Cassidy *et al*⁹ described three patients with the neck-tongue syndrome, who were successfully treated with rotational manipulation of the cervical spine. Terrett *et al*¹⁰ described eight cases of the neck-tongue syndrome, which were treated with spinal manipulative therapy. They also referred to an additional 54-year-old woman with headaches, who, after cervical manipulation, developed left sided tongue numbness, persisting for two years, together with an intermittent dysarthria. Hankey¹¹ described a more classical neck-tongue syndrome in a 14-year-old girl with recurrent episodes of unilateral upper nuchal pain radiating to the ipsilateral side of the tongue on ipsilateral rotation of the neck.

Noda and Umezaki¹² described a 35-year-old woman with paroxysmal episodes, lasting up to one minute, of numbness of the left neck and occiput, with simultaneous numbness of the left half of the tongue, preceded by tonic spasm of the left arm. They suggest this is a component of a spinal tonic seizure related to an upper cervical inflammatory myelopathy involving the dorsal funiculus, proximal to the C2 and C3 dorsal root ganglia, and hence a spinal neck-tongue syndrome.

In total, 36 cases of this syndrome have been previously described in the literature, some very briefly,^{4,8} although Bogduk¹³ comments that on discussion with other neurologists and neurosurgeons it seems that the syndrome is not rare. Accordingly we describe two further cases of the syndrome, due in one case to atlantoaxial osteoarthritis, and in the other to a traumatic fracture and displacement of the occipital condyle. A striking feature was dysarthria and, in the second case, pseudoathetosis of the tongue.

Patients

CASE 1

A 51-year-old woman complained of a progressive stiffness and pain in the neck for six years. Three years previously she had noticed that the pain was exacerbated by movement of the neck to a critical position, with the chin down and to the right. She was aware of a grating sensation in the neck, and the pain appeared to be deep to the angle of the jaw on the left, radiating to the occiput. These

exacerbations were associated with a tingling sensation of the left side of the tongue, and a sensation of the tongue being pulled into the back of the throat on the left, causing a feeling of choking, with difficulty speaking.

Neurological examination was normal, and in particular touch and pin prick sensation on both sides of the tongue was preserved. The tongue and palate appeared normal, with normal movement. Cervical spine movement was severely limited due to pain.

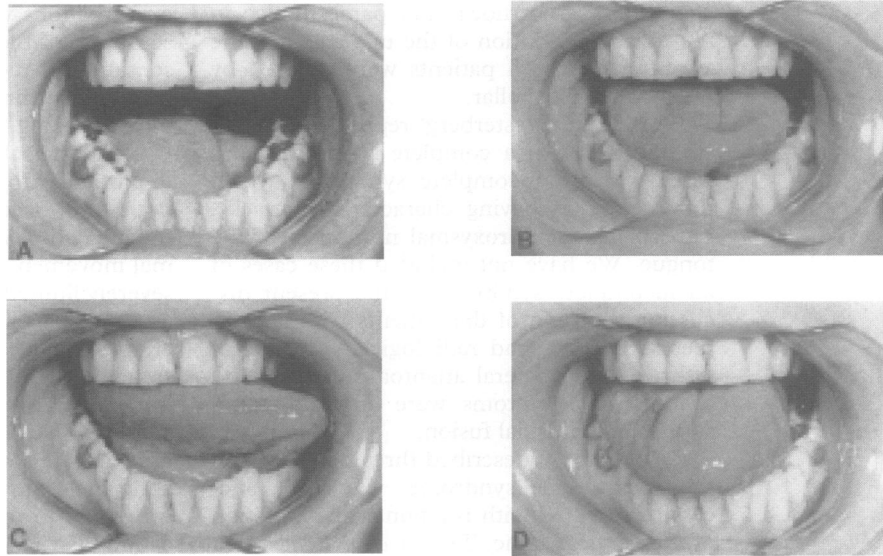
A cervical spine radiograph showed degenerative changes in the mid and lower cervical spine, with rotation at the atlantoaxial joint, but no horizontal subluxation. A cervical spine CT scan with the head turned to the right and left showed no structural lesion or abnormal movement. Rotatory movement was equal to the right and left, with no dislocation of the lateral atlantoaxial joint. The rotation was about 40 degrees on each side, a little more than usually seen, but probably not pathological. A radioisotope bone scan, however, revealed increased uptake in the left atlantoaxial joint, attributed to osteoarthritis. Injection of a local anaesthetic and steroid into this joint led to brief relief of the pain.

CASE 2

A 32-year-old woman accidentally fell down a flight of 12 stairs at night, hitting the right frontoparietal region of her head against a table. This caused a scalp laceration but no loss of consciousness or immediately apparent neurological deficit. The next day she awoke with a continuous right sided occipital headache and neck pain exacerbated by attempts at neck movement. She had slurring of speech, continuous altered sensation of the tongue and pharynx on the right with a feeling of the tongue moving to the left, and difficulty manipulating food in the mouth.

On examination she had tenderness over the upper cervical spine, and neck movements were severely restricted by pain. The tongue was rotated anticlockwise in the mouth, with consequent appearance of decreased bulk of the left side of the tongue (fig A). On forward protrusion of the tongue there was equal bulk of the two sides, but great difficulty in maintaining a sustained steady forward position, the tongue moving involuntarily to right and left (fig B). There were no visible fasciculations. There was full movement of the tongue to the left (fig C) despite partial denervation of the right half of the tongue demonstrated by EMG. Tongue protrusion to the right was incomplete and poorly sustained although no weakness of the left half of the tongue could be detected (fig D). On fiberoptic endoscopy the base of the tongue was more posterior than usual, and partially obstructing the larynx. She had a mild lingual dysarthria. Sensation of the tongue and pharynx to touch, taste, and pin prick was normal. Neurological examination was otherwise normal.

Cervical spine radiography was normal. An upper cervical CT scan was normal, but a CT scan of the skull base showed a fracture of the



Movement of the tongue in case 2; postures A,B,C, and D as described in the text.

right occipital condyle, with slight medial displacement of the fragment just distal to the right hypoglossal canal.

Discussion

The clinical spectrum of the neck-tongue syndrome, including age at presentation, chronicity, and disablement, has broadened since the original description. The two patients we describe had a feeling of abnormal posturing or movement of the tongue as a significant feature of their symptomatology. In case 2 the positioning of the tongue was clearly abnormal and she was unable to maintain a sustained normal posture of the tongue in the absence of any specific weakness. In particular there was no weakness of tongue movement to the left, which would be affected by motor denervation of the right side of the tongue. We propose that this is a result of proprioceptive deafferentation of the tongue, with the clinical sign of lingual pseudoathetosis. This is similar to pseudoathetosis as previously described in the limbs.¹⁴ Pseudoathetoid movements of the tongue seem particularly complex in the absence of any restriction of direction of movement imposed by a joint. The associated dysarthria has features of both impaired lingual control and pharyngeal obstruction as manifestations of lingual pseudoathetosis predominantly of the tip and base respectively.

Proprioception in the tongue has been studied in animals and humans,¹⁵ with controversy initially concerning whether the tongue musculature has proprioception. As a generalisation, it seems that muscle spindles are not found in the tongue of mammals, except in moles, primates, and humans.¹⁶ Muscle spindles have been demonstrated histologically in the human tongue.^{17,18} The afferent pathways seem to be in the hypoglossal nerve,^{16,19} which is otherwise thought of as being a purely motor nerve.

Lingual pseudoathetosis is suggested in

previous descriptions of neck-tongue syndrome. A 15-year-old boy had a right occipital pain and numbness of the right side of the tongue on sudden neck rotation, and a feeling that the tongue was twisted sideways in his mouth.¹ The symptoms lasted a few seconds only. A 29-year-old man had ipsilateral occipital pain and tingling in his tongue, with dysarthria and nasal congestion, precipitated by neck movement.⁷ A 60-year-old man, with symptoms since the age of 10 years, had experienced a sensation of his tongue being twisted sideways in the mouth during an attack, "as though the whole tongue is cleaving to the roof of the mouth".⁴ A 19-year-old woman with pain in the left side of the neck on sudden head turning also noticed deviation of her tongue to the right for 10 seconds, with anarthria.⁴ A 33-year-old woman described paralysis of her tongue for about five seconds on sharp rotation of the neck.¹⁰ A 19-year-old woman described her tongue as seeming to take up all the room in her mouth, having a mind of its own, being uncontrollable, and resulting in dysarthria.¹⁰ A 46-year-old man experienced the symptoms of the neck-tongue syndrome, his tongue being numb and rigid, with dysarthria.¹⁰ A 26-year-old woman experienced the neck-tongue syndrome, with an inability to move her tongue.¹⁰ In these cases the dysarthria, as in case 2, may be related to proprioceptive deafferentation rather than a primary motor deficit.

A 53-year-old woman had pain in the right side of her neck and tingling of the ipsilateral side of her tongue, initially intermittent but then constant. This was aggravated by head turning and talking, and when severe the pain radiated to the back of her head or right arm and caused mild dysphagia related to a feeling of muscle spasm in the throat.⁵ A 34-year-old man complained of intermittent left sided neck pain radiating to the occiput, with ipsilateral aching and numbness of the tongue. The symptoms were precipitated by rapid

neck flexion and rotation to either side when breathing during competitive free-style swimming. Occasionally the symptoms were so intense and associated with a choking sensation that he had to stop swimming during a race. (He had experienced the same symptoms while swimming between the ages of 10 and 22 years).⁶

Most reported cases have had transient symptoms and signs, but in case 2 these were constant, enabling the tongue posture and movement to be observed. The tongue seemed to be drawn back in the mouth, compatible with the symptom described in case 1, and possibly explaining the muscle spasm in the throat of the 53-year-old woman⁵ and 34-year-old swimmer.⁶

Of the cases of the neck-tongue syndrome previously described, four involved abnormalities at the atlantoaxial joints, two fusion of the atlas to the occiput, and another a minor abnormality of the occipital condylar processes. A cervical disc lesion was noted in another. In the other cases no clear pathology of the upper cervical joints was noted (although in one an intrinsic myelopathy was suggested). In case 1 the structural abnormality was osteoarthritis at the left atlantoaxial joint demonstrated by radioisotope bone scan. Irregular loss of the left lateral atlantoaxial joint space with reactive sclerosis and osteophytic lipping was noted in a 36-year-old man,⁶ and moderate degenerative changes at the anterior atlantoaxial joint in a 65-year-old woman.⁶

Another possible example of the condition was described by Lees *et al*²⁰ as "paroxysmal hemiglossal twisting". These authors reported two patients, and tentatively suggested dystonia or tonic seizure as the cause. The first case was a 61-year-old woman who, on review of the original records, described a tingling sensation at the back of the tongue on the left, the tongue then deviated to the right, and she was unable to move her tongue to the left, associated with dysarthria. On other occasions the tongue twisted from side to side, and she had bitten the left side of her tongue several times. Touch sensation of the tongue was normal during an episode. She had repeated episodes, lasting for about one minute, which were infrequent, with no clear precipitating neck movement, but appeared to be related to exercise. The attacks could be associated with discomfort down the left side of the neck and behind the left ear. A cervical spine radiograph showed no abnormality of the upper cervical region, and CT scan of the atlantoaxial joint was normal. Except for the absence of precipitation by neck movement, this case has features in common with the neck-tongue syndrome, and the abnormal twisting of the tongue may be a lingual pseudoathetosis due to lingual proprioceptive deafferentation, with associated C2 pain. (The second patient had brief spontaneous attacks of tongue twisting and dysarthria without pain or paraesthesiae).

In case 1, the site of deafferentation is assumed to be in the neck, related to the

atlantoaxial joint. In case 2, the site of deafferentation is uncertain, and could be at the atlantoaxial joint related to the fall and twisting of the neck, related to the displaced occipital condyle and abnormal atlanto-occipital joint, or in the hypoglossal nerve after exit from the hypoglossal canal related to the displaced bone fragment. Previous abnormalities of the atlanto-occipital joint were described in a 26-year-old man with anteromedial bosses of bone on the condylar processes of the occiput representing a minor anomaly of the occipital assimilation.¹ The spinous processes of the atlas were fused to the adjoining occipital bones in a 15-year-old girl,¹ and assimilation of the atlas to the occiput was noted in a 53-year-old woman.⁵

Thus of the 38 cases now described, pathology of the occipitoatlantoaxial joints has been noted in 10.

The onset of symptoms in case 2 was clearly related to trauma, as were 10 previous cases. A 29-year-old man had a motorcycle accident, with head and thoracic spine injury, two years before developing the neck-tongue syndrome.⁷ A 26-year-old man was hit in the midfrontal region by a child's swing, with laceration of the forehead. Shortly afterwards he developed numbness and weakness of the right hand lasting for several days. Ever since he has had transient symptoms of numbness of the right side of the tongue and right fourth and fifth fingers, and right sided neck pain, lasting a few seconds only, on sudden rotation of the neck.¹ A 36-year-old man accidentally jarred his neck, and subsequently, whenever jolted unexpectedly, experienced high cervical pain radiating to the left side of his tongue "like the aftermath of a dental anaesthetic".⁶ A 28-year-old woman developed the neck-tongue syndrome the day after a whiplash injury, which persisted for one year, but resolved with spinal manipulation.⁹ Other cases associated with trauma include four after a motor vehicle collision, and one developing eight years after a water skiing accident.¹⁰

The transient relief of the symptoms in case 1 by injection of local anaesthetic and steroid into the lateral atlantoaxial joint is supportive of the symptoms being related to this joint, and raises the possibility of treatment by permanent cervical fusion. Previously reported surgery with bilateral resection of C2 spinal nerves with their dorsal and ventral rami, initially relieved the symptoms, but after one week there was a recurrence of mild tingling sensations in the tongue when the patient was tired. The neck pain also recurred, but less severely than before the operation. The authors suggested that the recurrence of tongue symptoms could be explained by facilitation of residual proprioceptive fibres in the adjacent uninjured spinal roots. In another patient, surgical atlantoaxial fusion abolished the symptoms.⁸ Other patients have had their symptoms relieved by spinal manipulation.^{9 10} Symptoms have been improved by preventing the precipitative neck movement with a surgical collar,

but the benefit is not necessarily permanent, and with no long term follow up of this syndrome the natural history is unclear.

Since the initial description by Lance and Anthony¹ of patients aged 15 to 26 years, with an onset age of eight to 15 years, it has become apparent that the same syndrome may present up to at least the age of 61 years, and may present as transient symptoms which may persist, may resolve and relapse, or may become permanent and present as a permanent deficit. In a significant proportion there is pathology at the atlantoaxial and atlanto-occipital joints, and in some cases the syndrome may result from trauma.

We thank Professor A E Harding for permission to include details of the patient under her care.

- 1 Lance JW, Anthony M. Neck-tongue syndrome on sudden turning of the head. *J Neurol Neurosurg Psychiatry* 1980;43:97-101.
- 2 Cyriax J. *Textbook of orthopaedic medicine*. 4th ed. Vol 1. London: Cassell, 1962:158.
- 3 Bogduk N. An anatomical basis for the neck-tongue syndrome. *J Neurol Neurosurg Psychiatry* 1981;44:202-8.
- 4 Lance JW. Unusual syndromes in neurological practice. *Med J Aust* 1984;140:409-16.
- 5 Elisevich K, Stratford J, Bray G, Finlayson M. Neck-tongue syndrome: operative management. *J Neurol Neurosurg Psychiatry* 1984;47:407-9.
- 6 Webb J, March L, Tyndall A. The neck-tongue syndrome: occurrence with cervical arthritis as well as normals. *J Rheumatol* 1984;11:530-3.
- 7 Fortin CJ, Biller J. Neck-tongue syndrome. *Headache* 1985;25:255-8.
- 8 Bertoft ES, Westerberg CE. Further observations on the neck-tongue syndrome. *Cephalgia* 1985;5(suppl 3):312-3.
- 9 Cassidy JD, Diakow PRP, De Korompay VL, Munkacsi I, Yong-Hing K. Treatment of neck-tongue syndrome by spinal manipulation: a report of three cases. *The Pain Clinic* 1986;1:41-6.
- 10 Terrett AGJ. Neck-tongue syndrome and spinal manipulative therapy. In: Vernon H, ed. *Upper cervical syndrome: chiropractic diagnosis and treatment*. Baltimore: Williams and Wilkins, 1988:223-9.
- 11 Hankey GJ. "Neck-tongue" syndrome on sudden neck rotation. *Aust N Z J Med* 1988;18:181.
- 12 Noda SN, Umezaki H. Spinal neck-tongue syndrome. *J Neurol Neurosurg Psychiatry* 1984;47:751.
- 13 Bogduk N. Neck-tongue syndrome. *Med J Aust* 1980;2:4.
- 14 Liversedge LA. Involuntary movements. In: Vinken PJ, Bruyn GW, eds. *Handbook of clinical neurology*. Vol 1. Amsterdam: North-Holland, 1969:277-292.
- 15 Tier GA, Rees RT, Rood JP. The sensory nerve supply to the tongue: a clinical reappraisal. *Br Dent J* 1984;157:354-7.
- 16 Kubota K, Narita N, Takada K, et al. Origin of lingual proprioceptive afferents in Japanese monkey, *M fuscata fuscata*. Studied by HRP-labeling technique. *Anat Anz* 1988;166:141-8.
- 17 Cooper S. Muscle spindles in the intrinsic muscles of the human tongue. *J Physiol (Lond)* 1953;122:193-202.
- 18 Kubota K, Negishi T, Masegi T. Topological distribution of muscle spindles in the human tongue and its significance in proprioception. *Bull Tokyo Med Dent Univ* 1975;22:235-42.
- 19 Adatia AK, Gehring EN. Proprioceptive innervation of the tongue. *J Anat* 1971;110:215-20.
- 20 Lees AJ, Blau JN, Schon F. Paroxysmal hemiglossal twisting. *Lancet* 1986;ii:812-3.