

Dynamics of cerebral blood flow and metabolism in patients with cranioplasty as evaluated by ^{133}Xe CT and ^{31}P magnetic resonance spectroscopy

Kazuo Yoshida, Masahiro Furuse, Akira Izawa, Naoto Iizima, Hiroji Kuchiwaki, Suguru Inao

Abstract

Objective—Prolonged improvement in neurological and mental disorders has been seen after only cranioplasty in patients initially treated with external decompression for high intracranial pressure. The objective was to evaluate, using ^{133}Xe CT and ^{31}P magnetic resonance spectroscopy (MRS), how restoring the bone itself can influence cerebral blood flow and cerebral energy metabolism after high intracranial pressure is attenuated.

Methods—Seven patients (45–65 years old) who had undergone external decompression to prevent uncontrollable intracranial hypertension after acute subarachnoid haemorrhage were evaluated. Cerebral blood flow and metabolic changes were evaluated before and after cranioplasty.

Results—The ratio of phosphocreatine to inorganic phosphate (PCr/Pi), which is a sensitive index of cerebral energy depletion, was calculated and β -ATP was measured. The cerebral blood flow value in the thalamus was normalised, from 44 (SD 9) to 56 (SD 8) ml/100 g/min ($P < 0.01$) and the value in the hemisphere increased from 26 (SD 3) to 29 (SD 4) ml/100 g/min on the side with the bone defect. The PCr/Pi ratio improved greatly from 2.53 (SD 0.45) to 3.01 (SD 0.24) ($P < 0.01$). On the normal side, the values of cerebral blood flow and PCr/Pi increased significantly ($P < 0.01$) after cranioplasty, possibly due to transneural suppression. The pH of brain tissue was unchanged bilaterally after cranioplasty.

Conclusion—Cranioplasty should be carried out as soon as oedema has disappeared, because a bone defect itself may decrease cerebral blood flow and disturb energy metabolism.

(*J Neurol Neurosurg Psychiatry* 1996;61:166–171)

Keywords: external decompression; cranioplasty; cerebral blood flow; cerebral metabolism; subarachnoid haemorrhage

Since Cushing first described decompressive craniectomy for the relief of intracranial pressure,¹ surgical decompression has been advocated as a treatment for severe brain oedema associated with brain injury and cerebral infarction.^{2–5} However, the value of decom-

pressive craniotomy remains controversial. Some authors found that morbidity was increased in survivors although decompressive craniectomy reduced the mortality rate, probably because it reduced the adverse effects of severe cerebral oedema and swelling.^{6–12} Many patients with severe head injury or massive cerebral infarction undergo external decompression as a treatment.

However, little is known about how a bone defect itself can influence cerebral blood flow and cerebral energy metabolism after high intracranial pressure is normalised. Prolonged improvement in neurological and mental disorders has been seen only after cranioplasty in patients treated initially with external decompression for high intracranial pressure.^{13–17} The objective of the present study was to measure cerebral blood flow and metabolic changes, using ^{133}Xe CT and ^{31}P magnetic resonance spectroscopy (MRS), before and after cranioplasty to evaluate whether the brain would recover after attenuation of high intracranial pressure, by restoration of the bone itself.

Materials and methods

Seven patients (45–65 years old) were selected who had undergone clipping and external decompression to prevent uncontrollable

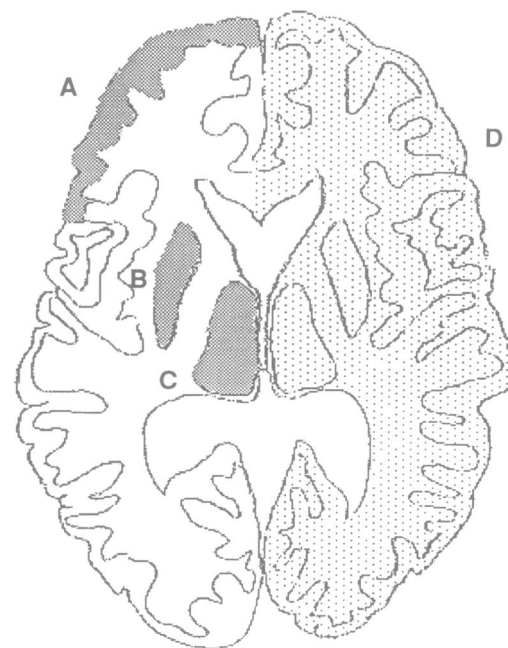


Figure 1 Placement of regions of interest of cerebral blood flow measurement. (A) frontal cortex; (B) putamen; (C) thalamus; (D) whole cerebral hemisphere.

Department of
Neurosurgery, School
of Medicine, Nagoya
University
K Yoshida
H Kuchiwaki
S Inao

Department of
Neurosurgery
M Furuse

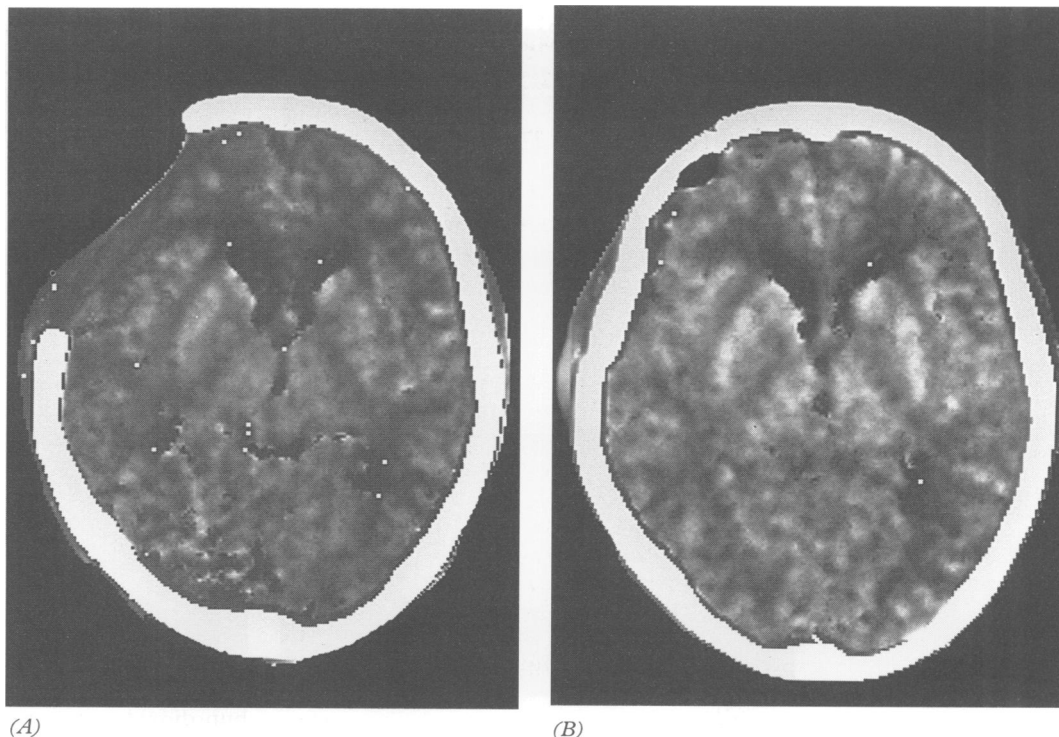
Department of
Radiology,
Nakatsugawa
Municipal General
Hospital
A Izawa

Shimadzu Corporation
Central Research
Laboratory
N Iizima

Correspondence to:
Dr Kazuo Yoshida,
Department of
Neurosurgery, School
of Medicine, Nagoya
University, 65 Tsurumai-
cho, Showa-ku, Nagoya,
466, Japan.

Received 14 November 1994
and in final revised form
27 December 1995
Accepted 3 April 1996

Figure 2 A 52 year old man with an aneurysm of the right posterior communicating artery underwent clipping and external decompression because of severe subarachnoid haemorrhage. He had no neurological deficit before cranioplasty and the skull defect was flat. Cranioplasty was carried out three weeks after the first operation. (A) Cerebral blood flow mapping images before and (B) after cranioplasty. Cerebral blood flow values increased from 21.9 to 25.6 in the hemisphere, and from 35.0 to 58.3 in the thalamus after cranioplasty.



intracranial hypertension after acute subarachnoid haemorrhage. Cerebral blood flow and metabolism were evaluated by ^{133}Xe CT and ^{31}P MRS three weeks after external decompression, or just before cranioplasty, when it was concluded that cerebral swelling and vasospasm had completely disappeared and that high intracranial pressure was attenuated, although we did not actually measure intracranial pressure. Cerebral blood flow and metabolism were measured again one week after cranioplasty with an autologous bone graft. Skull defects were round or flat.

The ^{133}Xe CT study was carried out with a TCT 900s CT scanner (Toshiba Co Ltd), an AZ-723 model closed rebreathing Xe inhaler (Anzai Sogyo Co Ltd), and an AZ-723-XS end tidal Xe monitor (Anzai Sogyo Co Ltd). Mapping of cerebral blood flow was performed by the end tidal chamber method while the patient inhaled 30% Xe gas for six minutes. Regions of interest (ROIs) were placed on the hemisphere, frontal cortex, thalamus, and putamen at the level of the basal ganglia on both sides to delineate them on CT without contrast enhancement (fig 1). ^{31}P MRS was performed on a 1.5 Tesla whole body system (SMT-150; 64 MHz for H-1 and 25.9 MHz for P-31; Shimadzu Co Ltd). T1 weighted H-1 MR images (260/9/1 (TR/TE/excitations), field echo, flip angle = 90°, slice width = 10 mm, pitch = 11, 10 slices, 256 × 256 matrix, 120 seconds) were used to inspect the volume of interest (VOI). Field homogeneity was optimised by autoshimming on the water proton signal. Then the instrument was switched to ^{31}P MRS, and MRS of the VOI was obtained with the ^{31}P MRS head coil. The method used to obtain ^{31}P MRS was 1D/ISIS (image selected in vivo spectroscopy).^{18,19} This method avoids transverse relaxation and therefore allows

short T2 signals to appear on ^{31}P MRS. Spectra were recorded with TR = 2000, sampling delay time (TS) = 0.80 ms, 1024 sampling points, and average = 300–800. The VOI thickness was 30–50 mm and total accumulation time was 13–15 minutes. The VOI was located in almost the whole hemisphere, including grey and white matter, usually at the level of the basal ganglia (fig 3). All spectra obtained contained signals from extracranial structures, such as bone, muscle, and skin. It is possible that these may have influenced PCr/Pi (see below) and tissue pH values. Spectra were quantified by automated area analysis. To remove the broad signals derived from bone and from tissues in the inhomogeneous profiled magnetic field, the convolution difference method was used.²⁰ In this study, we calculated the ratio of phosphocreatine to inorganic phosphate (PCr/Pi). The quantification of the spectra may have been influenced by this signal processing. However, the quantification error for the peaks which have long T2 and narrow line width, such as PCr or Pi, are considered to be small and negligible. Tissue pH was calculated from the chemical shift of inorganic phosphate.^{21,23}

STATISTICAL ANALYSIS

Statistical analysis of any change in PCr/Pi and β -ATP was performed with non-parametric tests. All data are presented as means (SD).

Results

The cerebral blood flow values normalised from 44.1 (9.3) to 55.9 (7.9) ml/100 g/min ($P < 0.01$) in the thalamus and increased from 26.1 (3.4) to 28.7 (3.9) ml/100 g/min after cranioplasty, in the hemisphere with the bone defect (fig 2; fig 4A). Table 1 shows the mean arterial blood pressure (MABP), arterial car-

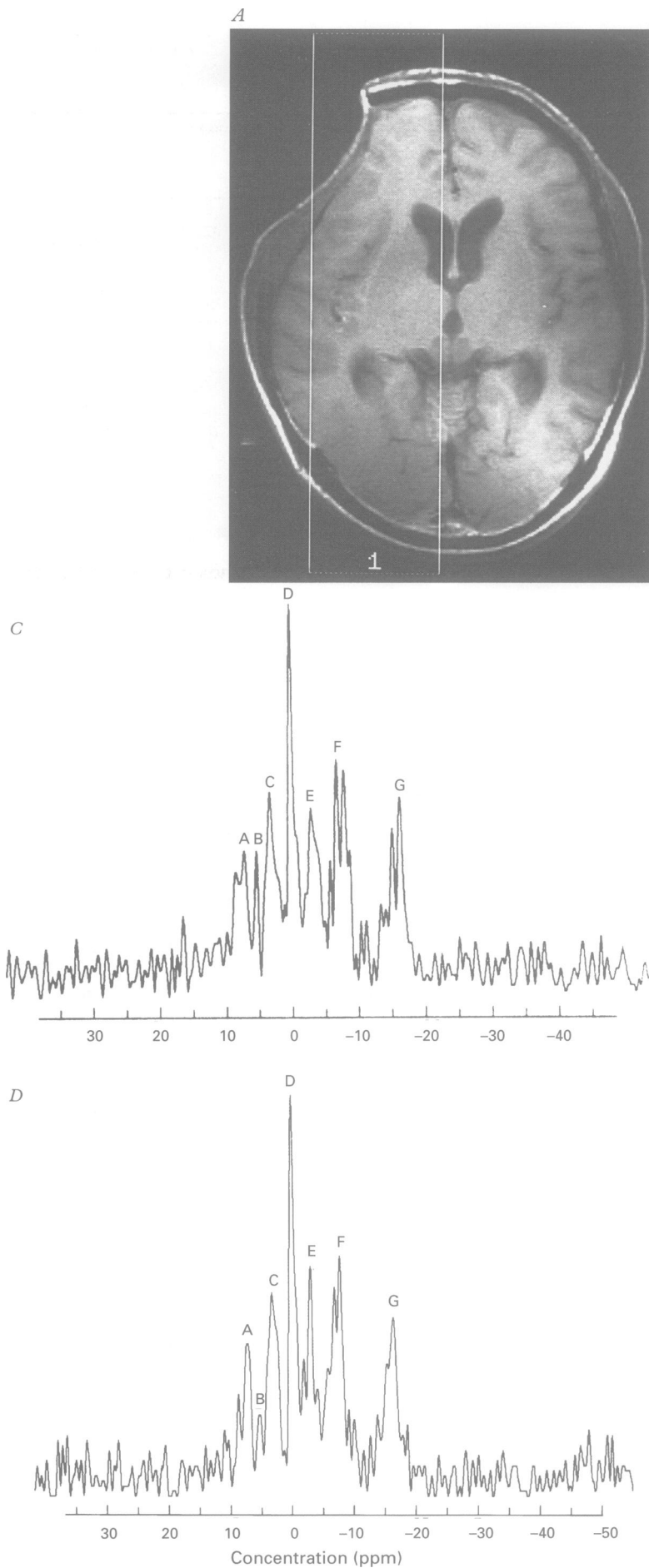
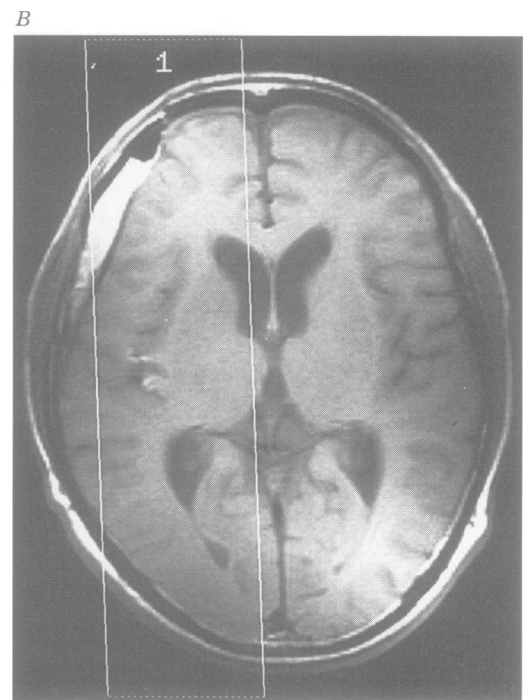


Figure 3 The same case as in fig 2. T1 weighted images (A,B) and spectroscopies (C,D) before and after cranioplasty respectively (C,D). The PCr/Pi ratio increased from 2.78 to 3.45. Peak A = phosphomonoester (PME); B = inorganic phosphate (Pi), C = Phosphodiester (PDE); D = Phosphocreatine (PCr), E = δ -ATP, F = α -ATP, G = β -ATP.



bon dioxide pressure (P_{aCO_2}), and body temperature at the time of cerebral blood flow measurements. These results showed nothing of significance. All patients were alert at the time of cerebral blood flow measurements. The PCr/Pi ratio improved greatly, from 2.54 (0.46) to 3.00 (0.25) ($P < 0.01$) after cranioplasty (fig 3; table 2). On the normal side, the cerebral blood flow and PCr/Pi increased significantly ($P < 0.01$) after cranioplasty (fig 4B;

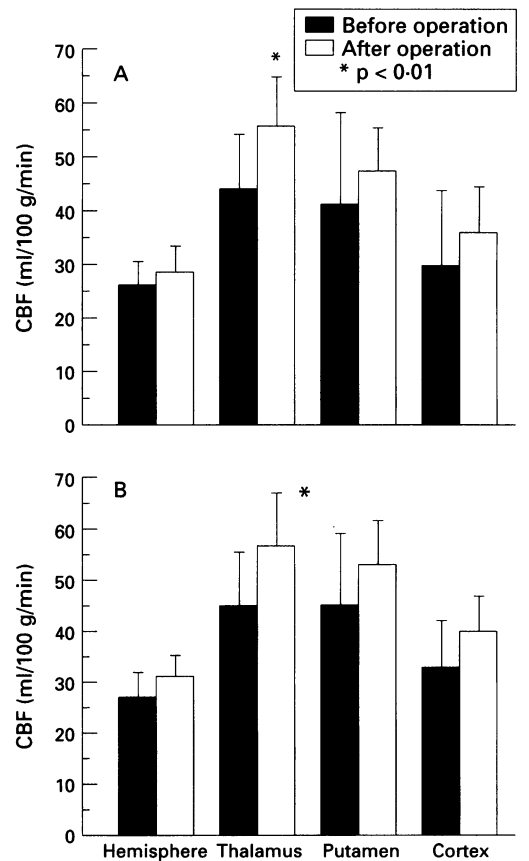


Figure 4 Cerebral blood flow values before and after cranioplasty (A) ipsilateral to the bone defect and (B) on the normal contralateral side.

Table 1 Preoperative and postoperative values of blood pressure, blood gas, and body temperature

	MABP (mm Hg)	PaCO_2 (mm Hg)	Body temperature
Preoperative	101.7 (10.4)	38.0 (2.2)	36.4 (0.4)
Postoperative	99.6 (9.9)	37.4 (2.4)	36.5 (0.4)

Values are means (SD); MABP = mean arterial blood pressure; PaCO_2 = arterial carbon dioxide pressure.

Table 2 Metabolic variables

	Side of bone defect			Normal side		
	PCr/Pi	β -ATP	Brain pH	PCr/Pi	β -ATP	Brain pH
Before cranioplasty (n = 7)	2.54 (0.46)	0.52 (0.06)	7.15 (0.05)	2.75 (0.22)	0.57 (0.03)	7.16 (0.07)
After cranioplasty (n = 7)	3.00 (0.25)*	0.49 (0.04)	7.16 (0.09)	3.18 (0.36)*	0.58 (0.04)	7.15 (0.07)
Normal controls (n = 7)	3.21 (0.21)**	0.54 (0.06)	7.15 (0.13)	3.21 (0.21)**	0.54 (0.06)	7.15 (0.13)

Values are means (SD).

* $P < 0.01$; ** $P < 0.01$ v before cranioplasty.

Figure 5 Relations between cerebral blood flow and metabolism in the hemisphere ipsilateral to the bone defect (A) and on the normal contralateral side (B). In every case, both values increased after surgery.

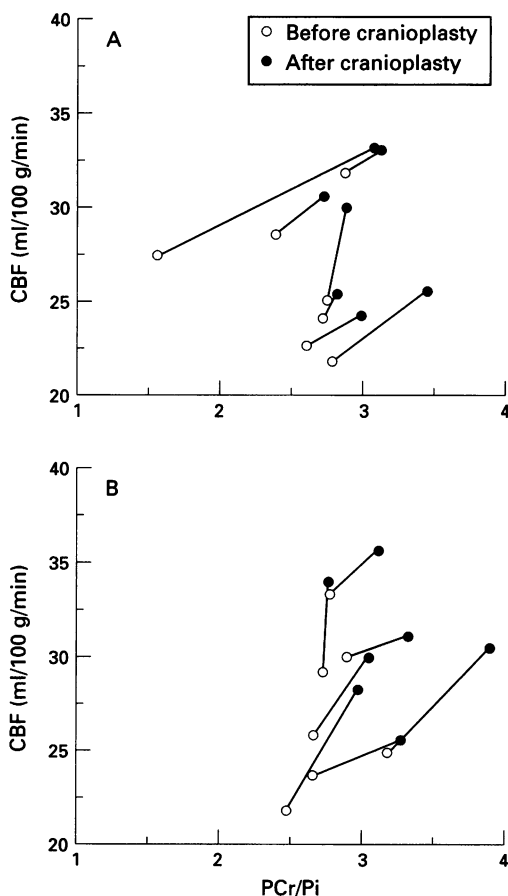


table 2). Table 3 shows cerebral blood flow values for five normal controls (45–65 years old). In the thalamus, cerebral blood flow values decreased significantly ($P < 0.02$, $P < 0.05$) preoperatively compared with normal controls. For PCr/Pi, preoperative ratios were decreased significantly compared with normal controls. Figure 5 shows the relation between cerebral blood flow and metabolism. In every case, values on both sides increased after

surgery. Brain tissue pH and β -ATP were unchanged bilaterally after cranioplasty. The patients had no neurological deficit or any complaint before or after cranioplasty.

Discussion

Many authors have studied the influence of a craniotomy on the brain at high intracranial pressure.^{1–8} However, measurements of cerebral blood flow and metabolism dynamics have not been reported for patients who have undergone external decompression after normalisation of their intracranial hypertension.

Some patients who undergo external decompression due to an acute increase in intracranial pressure show improvement in their neurological and mental disorders only after cranioplasty.¹⁷ Further, changes in EEG coincided well with the clinical course. Tabaddor and LaMorgese¹⁵ described a patient who developed a contralateral weakness four months after surgery and who recovered after cranioplasty. Some authors have proposed that cranioplasty should be performed not only for cosmetic reasons in patients with head injury with a bone defect, but because of post-traumatic syndromes as well as headache, dizziness, fatiguability, and mental depression, could be due to a bone defect.^{23–25} Their results indicated that a bone defect itself could damage the brain by an unknown mechanism. Tabaddor and LaMorgese presumed that a gradient existed between atmospheric and intracranial pressure. Stula¹⁴ suggested that cicatricial changes occurring in the cortex, dura, and skin may exert pressure on the skull contents. Richaud *et al* reported that cerebral blood flow, as evaluated with ^{133}Xe CT, improved after cranioplasty as the neurological condition improved.¹⁶ Also, Suzuki *et al*, using dynamic CT, reported that cerebral blood flow

Table 3 Mean cerebral blood flow values (ml/100g/min)

	Side of bone defect				Normal side			
	Hemisphere	Thalamus	Putamen	Cortex	Hemisphere	Thalamus	Putamen	Cortex
Preoperation (n = 7)	26.1 (3.4)	44.1 (9.3)	41.5 (15.8)	29.9 (13.0)	27.0 (4.0)	45.2 (9.2)	45.1 (13.3)	33.0 (8.0)
Postoperation (n = 7)	28.7 (3.9)	55.9 (7.9)**	47.3 (7.2)	36.0 (7.7)	30.8 (3.4)	56.6 (9.2)**	53.0 (7.9)	40.1 (5.9)
Normal controls (n = 5)	31.5 (3.8)	58.9 (7.6)†	51.7 (3.9)	39.9 (3.5)	31.5 (3.8)	58.9 (7.6)*	51.7 (3.9)	39.9 (3.5)

Values are means (SD).

* $P < 0.05$; † $P < 0.02$; ** $P < 0.01$ v preoperation.

improved after cranioplasty.²⁶ Grantham and Landis reported an almost aphasic patient who became able to use more words after cranioplasty although they gave no reason for this improvement.¹³ Therefore, in the present study, we measured cerebral blood flow and metabolic alterations before and after cranioplasty to assess the effect of craniotomy on the brain. The patients had no neurological deficit, complaint, or abnormal intensity area on MRI before cranioplasty. Cerebral angiography gave normal results in all patients. Therefore, there was no evidence for cerebral oedema, symptomatic vasospasm, or angiographic vasospasm when cerebral blood flow and the ³¹P spectrum were measured.

The three dimensional measurement of regional cerebral blood flow using stable Xe CT is non-invasive, easily repeatable, and provides excellent spatial resolution; thus it has many clinical applications.²⁷⁻²⁹ Tanaka *et al*³⁰ showed that the mean hemispheric cerebral blood flow decreased by about 7% in patients with headache and by about 35% in patients with hemiparesis or a mental disturbance. Further, reduction in cerebral blood flow was always more pronounced in the putamen and thalamus than in the cortex. Therefore, reduction in cerebral blood flow in patients with a chronic subdural haematoma occurs in central cerebral areas as brain compression and displacement progresses. In the present study, cerebral blood flow recovered to normal values from 44.1 (9.3) to 55.9 (7.9) ml/100 g/min ($P < 0.01$) in the thalamus and increased from 26.1 (3.4) to 28.7 (3.9) ml/100 g/min in the hemisphere with the bone defect after cranioplasty. The pattern of cerebral blood flow suppression in the case of a bone defect resembles a chronic subdural haematoma. Inao *et al* investigated brainstem distortion in patients with chronic subdural haematomas and hypothesised that atmospheric compression or brain distortion and displacement are causes of the reduction in cerebral blood flow. Further, cerebral blood flow values improved significantly after surgery. It was speculated that this was due to transneural suppression (diaschisis), because patients had no midline shift on MRI.

Recent advances in MRS allow the non-invasive study of cerebral metabolism *in vivo*. However, quantitative evaluations are difficult to perform, particularly the measurement of absolute concentrations of metabolites. These problems are currently circumvented by calculating the ratio of the metabolites. We emphasise that PCr/Pi is a sensitive marker of cerebral energy depletion. A major role for PCr in the brain is to buffer the ATP/ADP ratio through the creatine kinase reaction. Because a decrease in PCr is most likely accompanied by an increase in Pi, the PCr/Pi ratio amplifies even subtle decreases in PCr.³² Previous ³¹P MRS investigations in animals have stressed a decreased ratio of PCr/Pi in cases of experimental head trauma,³² acute cerebral infarction,³⁴⁻³⁶ hypoxia,^{33 37} and convulsion.^{38 39}

Reduction in PCr/Pi occurred without

changes of brain pH and β -ATP in patients with a bone defect. In the present investigation, the PCr/Pi ratio returned to normal after cranioplasty. This phenomenon indicates a disturbance of energy metabolism, also shown by others.^{32 40 41}

Therefore, it is possible that the cerebral energy metabolism was disturbed by the bone defect. It is also noteworthy that PCr/Pi ratios were reduced contralateral to the bone defect, just as the cerebral blood flow changes.

Signals from extracranial structures, such as bone, muscle, and skin, were sampled simultaneously by 1D/ISIS. Therefore, values which we reported differed from previous investigations. Bottomley *et al*⁴² reported values for brain tissue pH and PCr/Pi values of 7.01 (0.05) and 7.7 (2.3) respectively in healthy adults. The pH values given by Petroff *et al* showed a considerable variation (7.09 to 7.33).²¹ The replacement of the bone flap would have resulted in changing contributions from skin, temporal muscle, and cerebral blood flow. However, the patients had no midline shift and no change of ventricle size before and after cranioplasty. Because the change in cerebral blood flow volume was very small, the signal from decreased cerebral blood flow was considered to be small and disregarded. Temporalis contribution was also considered to be very small because skull defects were not concave but round or flat. So we think that our results are acceptable.

The PCr/Pi ratios and cerebral blood flow values decreased by 15.4% and 9.1% respectively before cranioplasty. Therefore, it is considered that the neural cells experienced a deterioration in energy state because of an imbalance between substrate supply and energy utilisation.

In patients with chronic subdural haematoma the PCr/Pi ratio also improved greatly after surgery.⁴¹ However, in patients with a bone defect, not only the same mechanism as for a chronic subdural haematoma but also more complicated causes must be considered. We speculate that brain distortion, and unusual conditions such as a low intracranial pressure due to a bone defect and fluctuation of intracranial pressure with change in head position, may also reduce cerebral blood flow and produce energy disturbance. In animal experiments, craniectomy, in normal animals decreased intracranial pressure and increased brain compliance,^{9 12} but tended to facilitate brain oedema formation.^{10 11}

In conclusion, our results suggest that cranioplasty should be performed as soon as intracranial hypertension has disappeared, as a bone defect itself can decrease cerebral blood flow and suppress cerebral metabolism even when intracranial pressure is normal. Further, prophylactic external decompression should be avoided.

We thank Ms Hiromi Koida of the department of Radiology in Nakatsugawa Municipal General Hospital for her technical assistance.

1 Cushing H. The establishment of cerebral hernia as a decompressive measure for inaccessible brain tumors; with the description of intermuscular methods of making

- the bone defect in temporal and occipital regions. *Surg Gynecol Obstet* 1905;1:297-314.
- 2 Britt RH, Hamilton RD. Large decompressive craniotomy in the treatment of acute subdural hematoma. *Neurosurgery* 1978;2:195-200.
 - 3 Ransohoff J, Benjamin V, Gage L, Epatein F. Hemispheric craniectomy in the management of acute subdural hematoma. *J Neurosurg* 1971;34:70-6.
 - 4 Kjellberg RN, Prieto A. Bifrontal decompressive craniotomy for massive cerebral edema. *J Neurosurg* 1971;34:488-93.
 - 5 Kondziolka D, Fazl M. Functional recovery after decompressive craniectomy for cerebral infarction. *Neurosurgery* 1988;23:143-7.
 - 6 Cooper PR, Rovit RL, Ransohoff J. Hemispheric craniectomy in the treatment of acute subdural hematoma: a re-appraisal. *Surg Neurol* 1976;5:25-8.
 - 7 Venes JL, Collins WF. Bifrontal decompressive craniectomy in the management of head trauma. *J Neurosurg* 1975;42:429-33.
 - 8 Cooper PR, Hagler H, Clark K, Barnett P. Enhancement of experimental cerebral edema after decompressive craniectomy: implications for the management of severe head injuries. *Neurosurgery* 1979;4:296-300.
 - 9 Shapiro K, Fried A, Takei F, Kohn I. Effect of the skull and dura on neural axis pressure—volume relationships and CSF hydrodynamics. *J Neurosurg* 1985;63:76-81.
 - 10 Hatashita S, Koike J, Sonokawa T, Ishii S. Cerebral edema associated with craniectomy and arterial hypertension. *Stroke* 1985;16:661-8.
 - 11 Schutta HS, Kassell NF, Langfitt TW. Brain swelling produced by injury and aggravated by arterial hypertension. *Brain* 1967;91:281-94.
 - 12 Hatashita S, Hoff JT. The effect of craniectomy on the biomechanics of normal brain. *J Neurosurg* 1987;67:573-8.
 - 13 Grantham EG, Landis HP. Cranioplasty and the post-traumatic syndrome. *J Neurosurg* 1947;5:19-22.
 - 14 Stula D. Intrakranielle druckmessung bei grob schadelkallottendefekten. *Neurochirurgia (Stuttg)* 1985;28:164-9.
 - 15 Tabaddor K, LaMorgese J. Complication of a large cranial defect: case report. *J Neurosurg* 1976;44:506-8.
 - 16 Richaud J, Boetto S, Guell A, Lazorthes Y. Incidence des craniopsties sur la fonction neurologique et le debit sanguin cerebral. *Neurochirurgie* 1985;31:183-8.
 - 17 Yamaura A, Makino H. Neurological deficits in the presence of the sinking skin flap following decompressive craniectomy. *Neurol Med Chir (Tokyo)* 1977;17:43-53.
 - 18 Ordidge RJ, Connolly A, Lohman LAB. Image-selected in vivo spectroscopy (ISIS). A new technique for spatially selective NMR spectroscopy. *J Magn Reson* 1986;66:283-94.
 - 19 Ordidge RJ, Bowley RM, Mchale G. A general approach to selection of multiple cubic volume elements using the ISIS technique. *Magn Reson Med* 1988;8:323-31.
 - 20 Gonzalez-Mendez R, Litt L, Koretsky AP, Colditz J, Weiner MW, James TL. Comparison of ³¹P NMR spectra of in vivo rat brain using convolution difference and saturation with a surface coil. Source of the broad component in the brain spectrum. *J Magn Reson Imaging* 1984;57:526-33.
 - 21 Petroff OAC, Prichard JW, Behar KL, Alger JR, Hollander JA, Shulman RG. Cerebral intracellular pH by ³¹P nuclear magnetic resonance spectroscopy. *Neurology* 1985;35:781-8.
 - 22 Thulborn KR, Boulay GH, Duchon LW, Radda G. A ³¹P nuclear magnetic resonance in vivo study of cerebral ischemia in the gerbil. *J Cereb Blood Flow Metab* 1982;2:299-306.
 - 23 Gardner WJ. Closure of defects of the skull with tantalum. *Surg Gynecol Obstet* 1945;80:303-12.
 - 24 Grant FC, Norcross NC. Repair of cranial defects by cranioplasty. *Ann Surg* 1939;110:488-512.
 - 25 Woodhall MB. Tantalum cranioplasty for war wounds of the skull. *Ann Surg* 1945;121:649-68.
 - 26 Suzuki N, Suzuki S, Iwabuchi T. Neurological improvement after cranioplasty. Analysis by dynamic CT scan. *Acta Neurochir (Wien)* 1993;122:49-53.
 - 27 Yonas H, Wolfson SK, Gur D, et al. Clinical experience with the use of xenon-enhanced CT blood flow mapping in cerebral vascular disease. *Stroke* 1984;15:443-50.
 - 28 Yonas H, Gur D, Good BC, et al. Xenon CT blood flow mapping for evaluation of patients with extracranial-intracranial bypass surgery. *J Neurosurg* 1985;62:324-33.
 - 29 Yonas H, Good WF, Gur D, et al. Mapping cerebral blood flow by xenon-enhanced computed tomography: clinical experience. *Radiology* 1984;152:435-42.
 - 30 Tanaka A, Yoshinaga S, Kimura M. Xenon-enhanced computed tomographic measurement of cerebral blood flow in patients with chronic subdural hematomas. *Neurosurgery* 1990;27:554-61.
 - 31 Inao S, Kuchiwaki H, Kanaiwa H, Sugita K, Banno M, Furuse M. Magnetic resonance imaging assessment of brainstem distortion associated with a supratentorial mass. *J Neurol Neurosurg Psychiatry* 1993;56:280-5.
 - 32 Yoshida K, Marmarou A. Effects of tromethamine and hyperventilation on brain injury in the cat. *J Neurosurg* 1991;74:87-96.
 - 33 Prichard JW, Alger JR, Behar KL, Petroff OAC, Shulman RG. Cerebral metabolic studies in vivo by ³¹P NMR. *Proc Natl Acad Sci USA* 1983;80:2748-51.
 - 34 Naruse S, Horikawa Y, Tanaka C, Hirakawa K, Nishikawa H, Watari H. In vivo measurement of energy metabolism and the concomitant monitoring of electroencephalogram in experimental cerebral ischemia. *Brain Res* 1984;296:370-2.
 - 35 Germano IM, Pitts LH, Berry I, Armond SJD. High energy phosphate metabolism in experimental permanent focal cerebral ischemia: an in vivo ³¹P magnetic resonance spectroscopy study. *J Cereb Blood Flow Metab* 1988;8:24-31.
 - 36 Btech DTD, Gordon RE, Hope PL, et al. Noninvasive investigation of cerebral ischemia by phosphorus nuclear magnetic resonance. *Pediatrics* 1982;70:310-3.
 - 37 Hilberman M, Subramanian VH, Haselgrove J, et al. In vivo time-resolved brain phosphorus nuclear magnetic resonance. *J Cereb Blood Flow Metab* 1984;4:334-42.
 - 38 Petroff OAC, Prichard JW, Behar KL, Alger JR, Shulman RG. In vivo phosphorus nuclear magnetic resonance spectroscopy in status epilepticus. *Ann Neurol* 1984;16:169-77.
 - 39 Schnall MD, Yoshizaki K, Chance B, Leigh JS. Triple nuclear NMR studies of cerebral metabolism during generalized seizure. *Magn Reson Med* 1988;6:15-23.
 - 40 Ishige N, Pitts LH, Pogliani L, Hashimoto T, Nishimura MC, Bartkowsky HM, James TL. Effects of hypoxia on traumatic brain injury in rats: part 2 Changes in high energy phosphate metabolism. *Neurosurgery* 1987;20:854-8.
 - 41 Yoshida K, Furuse M, Izawa A, et al. Dynamics of the cerebral metabolism in patients with chronic subdural hematoma before and after operation evaluated by P-31 magnetic resonance spectroscopy. *AJNR Am J Neuroradiol* 1994;15:1681-6.
 - 42 Bottomley PA, Drayer BP, Smith LS. Chronic adult cerebral infarction studied by phosphorus NMR spectroscopy. *Radiology* 1986;160:763-6.