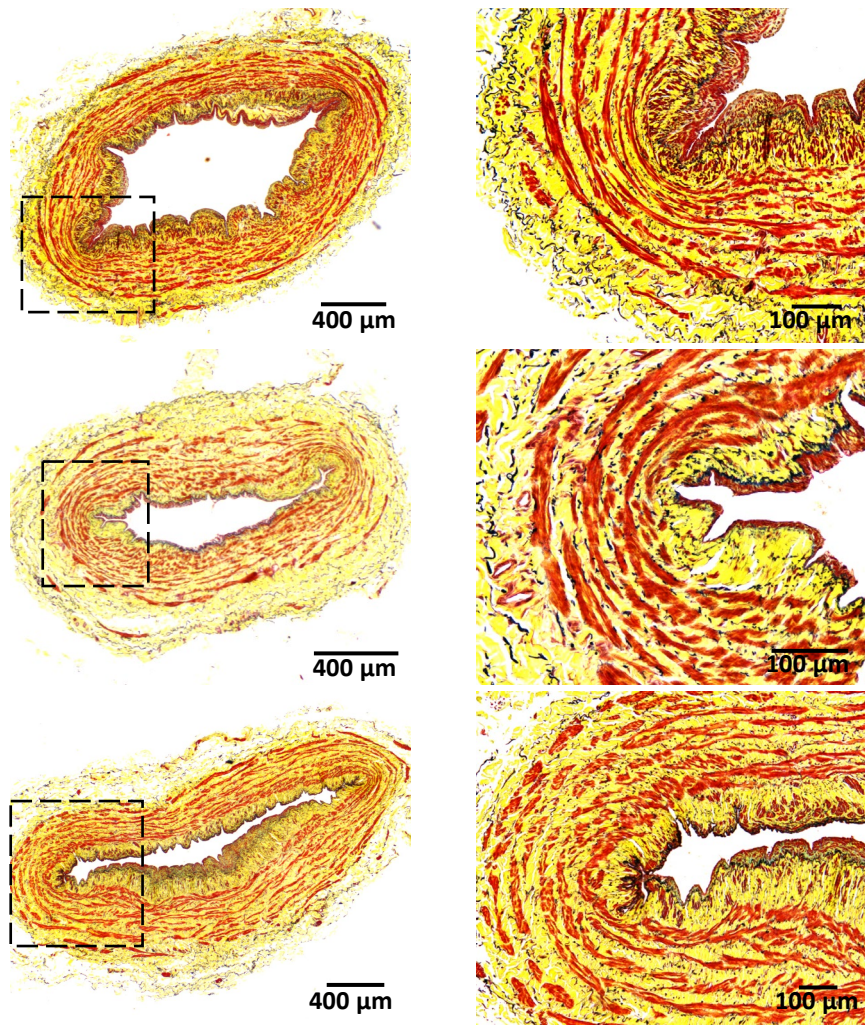
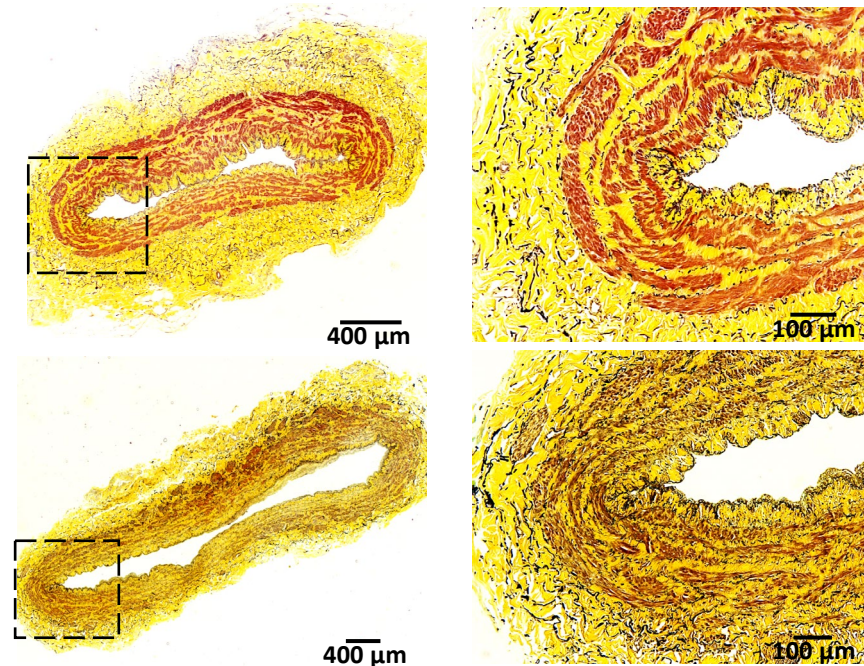
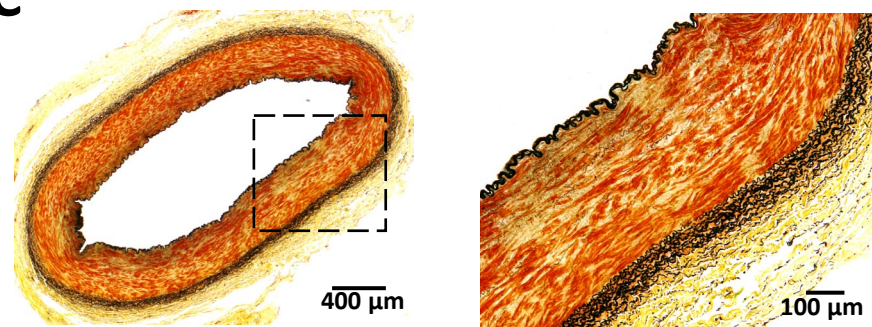


A**B****C**

S1 Fig. Histology of upper arm vessels. Representative Movat pentachrome stained sections of vascular tissues used for validation studies. Images include three basilic veins (A), two cephalic veins (B), and a brachial artery as reference (C). Dashed boxes are magnified to the right.