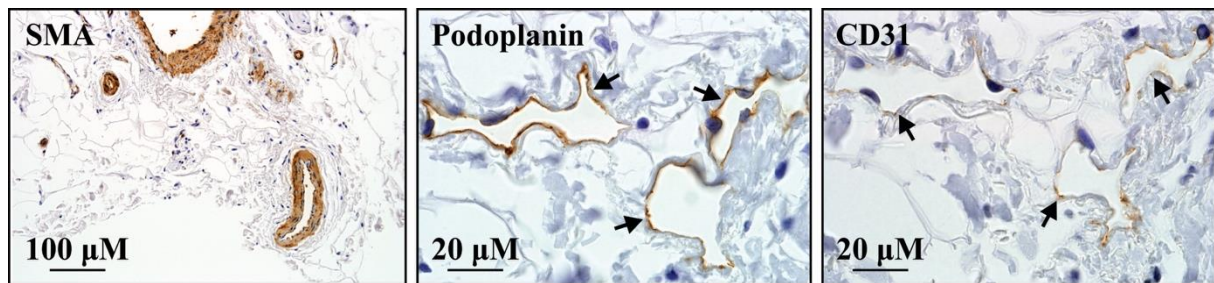


SDC 5



Light microscopy images of transverse serial sections through a perforating vascular bundle from the groin of a female without lymphedema.

Smooth muscle actin positive (brown) staining of the smooth muscle media of arteries and veins. Lymphatic structures were not detected by smooth muscle actin immunostaining (*left*). D2-40 staining (100x magnification; arrows and label) indicating expression of the lymphatic-specific marker podoplanin by lymphatic vessels (*middle*). CD31 immunostaining of the serial section demonstrating weak staining of the thin-walled lymphatics, including the lymphatic micro perforators that connect the collecting lymphatics to the more superficial dermal lymphatic vessels (arrows and label) (*right*).