

# Effect of natural allergen exposure during the grass pollen season on airways inflammatory cells and asthma symptoms

Ratko Djukanović, Iain Feather, Christina Gratzou, Andrew Walls, Diego Peroni, Peter Bradding, Mary Judd, Peter H Howarth, Stephen T Holgate

## Abstract

**Background** – Bronchial challenge with allergen causes a specific form of airways inflammation consisting of an influx of neutrophils, eosinophils, and T cells. Because the relevance of the challenge model to clinical asthma is uncertain, the cellular changes that occur in the lungs of asthmatic subjects during natural seasonal allergen exposure were investigated.

**Methods** – Seventeen grass pollen sensitive asthmatic subjects with previously reported seasonal exacerbations of asthma kept records of symptoms and underwent fiberoptic bronchoscopy with bronchoalveolar lavage (BAL) and endobronchial biopsy before and during the peak of the grass pollen season. The BAL cells were analysed for differential cell counts and by flow cytometry for T cell subsets and surface activation markers. The biopsy samples were processed into glycol methacrylate resin and immunohistochemical analysis was performed for mast cells, activated eosinophils, T cells and interleukin 4 (IL-4), a cytokine with a pivotal role in allergen-induced inflammation.

**Results** – In the pollen season there was an increase in T lymphocyte activation in the BAL fluid as identified by increased expression of interleukin 2 receptor (IL-2R). In the submucosa these changes were paralleled by an increase in CD4<sup>+</sup> T cells. By contrast, the numbers of metachromatic cells in BAL fluid staining with toluidine blue were reduced, possibly because of degranulation following allergen stimulation. In keeping with mast cell activation, the number of mucosal mast cells staining for secreted IL-4 increased during the season. In comparison with the period shortly before the onset of the season, all but two subjects experienced an asthma exacerbation which followed the rise in pollen counts but, compared with the period preceding the first bronchoscopic examination, asthma symptoms were not increased during the pollen season.

**Conclusions** – The data suggest that natural allergen exposure, leading to a clinical exacerbation of asthma, may induce an inflammatory response involving T cells, mast cells and eosinophils. The relationship between allergen exposure, cellular

infiltration and activation, and clinical symptoms appears to be complex, with factors other than allergen also contributing to asthmatic activity.

(Thorax 1996;51:575-581)

Keywords: asthma, inflammation, pollen.

Several studies have used fiberoptic bronchoscopy with bronchoalveolar lavage (BAL) and endobronchial biopsy to demonstrate an influx of inflammatory cells into the airways after allergen challenge consisting of eosinophils<sup>1-5</sup> and, to a lesser extent, neutrophils,<sup>1,4</sup> monocytes,<sup>5</sup> and T lymphocytes.<sup>4-7</sup> It remains, however, unclear how relevant the physiological and pathological observations made under conditions of laboratory challenge with large quantities of allergen are to the natural course of asthma. Deterioration of asthma seen after allergen challenge is associated with enhanced airways responsiveness lasting days or even weeks, thus mimicking clinical exacerbations of asthma.<sup>8-10</sup> Seasonal changes in airways responsiveness in pollen-sensitive asthmatic subjects<sup>11</sup> and cellular changes in the nose in patients with seasonal rhinitis, notably increases in eosinophils,<sup>12</sup> suggest that the allergen challenge model may indeed reflect events developing as a consequence of natural inhalation of allergen particles. However, except for one study which showed increased eosinophil counts and mediator levels in BAL fluid in patients with seasonal asthma,<sup>13</sup> convincing pathological evidence linking natural allergen exposure to bronchial mucosal inflammation has been lacking.

To study the course of airways inflammation in relation to a common environmental allergen, a group of grass pollen-sensitive asthmatic subjects with a history of seasonal deterioration of asthma and hay fever were studied. BAL and endobronchial biopsies were performed before and during the season to assess the degree of airways inflammation, as indicated by the extent of infiltration of the bronchi with inflammatory cells and their state of activation. To study the cytokine mechanisms which may explain the inflammatory changes and the seasonal rise in serum IgE levels in atopic subjects sensitive to pollen, the presence of cellular IL-4, a cytokine which is central to IgE production,<sup>14</sup> was determined by immunohistochemistry using specific anti-IL4 monoclonal antibodies.<sup>15</sup> To provide clinical

Immunopharmacology  
Group, University  
Medicine,  
Southampton General  
Hospital,  
Southampton  
SO16 6YD, UK  
R Djukanović  
I Feather  
C Gratzou  
A Walls  
D Peroni  
P Bradding  
M Judd  
P H Howarth  
S T Holgate

Correspondence to:  
Dr R Djukanović.

Received 21 August 1995  
Returned to authors  
18 October 1995  
Revised version received  
22 December 1995  
Accepted for publication  
20 January 1996

correlates for the cellular observations, indices of asthma activity consisting of symptoms, peak expiratory flow (PEF) measurements, and  $\beta_2$  agonist requirements were recorded and measurements of methacholine airways responsiveness were performed.

## Methods

### STUDY DESIGN

Following a run in period during which all the subjects recorded their asthma symptoms on diary cards, the first fiberoptic bronchoscopy with BAL and endobronchial biopsy was performed between mid February and end of April, during which period the asthmatics had stable although mildly symptomatic disease. The subjects continued to record their symptoms until the second bronchoscopy was performed in July. The decision about the timing of the second bronchoscopy was based on the subjects' reports of increased asthma symptoms and the pollen count being  $>50/m^3$ . Five days before each bronchoscopic examination methacholine responsiveness was measured. Throughout the study the subjects were allowed to inhale salbutamol from metered dose inhalers to control asthma symptoms and to apply local antihistamines and sodium cromoglycate only to relieve symptoms of rhinitis and conjunctivitis, respectively.

The study was approved by the Southampton Hospitals and University ethical subcommittee and subjects gave their written informed consent.

### SUBJECTS

Seventeen atopic asthmatics (10 women) of mean age 28 (range 20–49) years, with a history of onset or deterioration of asthma and upper respiratory symptoms during the previous pollen season, were studied. All the subjects underwent skin prick testing with mixed grass pollens, mixed tree pollens, *Dermatophagoides pteronyssinus*, *Dermatophagoides farinae*, cat fur, dog hair, feathers, and a mixture of moulds (Bencard, Brentford, UK). The skin tests were accepted as being positive if they resulted in a weal reaction which was at least 3 mm greater in diameter than that produced by physiological saline.

Most subjects had raised total serum IgE levels as measured by ELISA (geometric mean 217 IU, range 35–1980, normal range  $<81$  IU) and were shown to be highly skin test positive to grass pollen, although most (13 out of 17) were also sensitive to *Dermatophagoides pteronyssinus*. In addition, seven subjects were also mildly sensitive to tree pollens. Outside the pollen season, most of the subjects had mild to moderate airways hyperresponsiveness as assessed by low PEF variability (mean 7%, range 1–49%) and the provocative concentration of methacholine causing a 20% fall in forced expiratory volume in one second ( $PC_{20}$ ), although in two subjects  $PC_{20}$  methacholine was less than 0.1 mg/ml (geometric mean cumulative  $PC_{20}$  1.8 mg/ml, range 0.03–38.1 mg/ml). All were mildly symp-

tomatic but stable before the pollen season, and none were suffering from nocturnal symptoms and morning chest tightness. Ten subjects required salbutamol to relieve asthma symptoms brought on mainly by exercise or cold weather (median usage 0.3 puffs per day, range 0–10). None had been treated with inhaled or oral corticosteroids for several years, and none had suffered from respiratory infections for at least two months before and during the study.

### ASSESSMENT OF DISEASE ACTIVITY

Throughout the study the subjects recorded the following asthma symptoms: nocturnal wheeze, nocturnal cough, morning chest tightness, daytime wheeze, and subjective worsening of asthma due to exercise, cold air or fumes. The symptoms were scored on a 0–3 scale (0 = absent, 1 = mild, 2 = moderate, 3 = severe) and mean daily scores were calculated. The subjects were also asked to record their salbutamol usage (number of 100  $\mu$ g puffs per day) and PEF as the best of three pretreatment measurements taken twice daily using a mini-Wright peak flow meter (Airmed, London, UK). PEF variation was calculated as the amplitude % mean (evening minus morning values divided by the mean of the morning plus evening values).

Forced expiratory volume in one second ( $FEV_1$ ) was measured on the day when airways responsiveness was assessed and after refraining from bronchodilator treatment for eight hours. Airway responsiveness was measured by methacholine challenge five days before fiberoptic bronchoscopy according to a method modified from Chai and coworkers.<sup>16,17</sup>

### BRONCHOSCOPY

Fiberoptic bronchoscopy was performed under local anaesthesia according to the National Institutes of Health guidelines<sup>18</sup> as previously described.<sup>19</sup> BAL fluid and biopsy samples were taken from the same lung, the side being determined by randomisation. BAL was performed in the anterior segments of the upper lobes with six 20 ml aliquots of physiological saline. Two biopsy samples of subcarinae were then taken with alligator forceps (Olympus FB 15C, Tokyo, Japan) in the lower and middle (or lingula) lobes. On the second occasion BAL fluid and biopsy samples were taken from the opposite lung.

### ASSESSMENT OF AIRWAYS INFLAMMATION

Both BAL and endobronchial biopsy samples were taken as these provide complementary information about the extent of cellular infiltration and activation.

### PROCESSING OF BAL CELLS

The number of leucocytes in the BAL fluid was counted using a haemocytometer. Cyto-centrifuge preparations were made and stained with Giemsa stain for differential cell counts on at least 800 cells. Metachromatic cells were

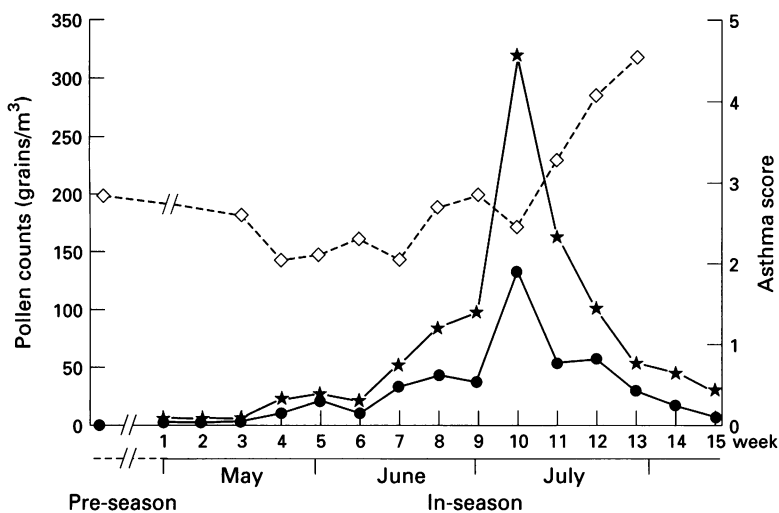


Figure 1 Mean weekly pollen counts (●), peak weekly pollen counts (★) and mean weekly asthma score (◇) during the study. The weeks in May through to August are labelled as 1–15, and the week preceding the first bronchoscopy before the pollen season is labelled as 0.

identified by toluidine blue staining as the use of immunocytochemistry on mast cells in BAL fluid is not possible because of poor penetration of the monoclonal antibody into the cytoplasm of intact cells. Distinction between basophils and mast cells – otherwise possible on the basis of tryptase positivity (tryptase is found only in mast cells<sup>20</sup>) – was therefore not made. Because the numbers of metachromatic cells in BAL fluid are low, between 10 000 and 30 000 cells were examined.

The remainder of the cells were passed through a 0.9 mm gauge sieve and centrifuged at 400 *g* for 10 minutes at 4°C. The cells were resuspended in physiological saline containing added autologous serum and analysed by flow cytometry. Dual colour flow cytometry was used on the BAL fluid as described previously<sup>21</sup> to study CD3+ T cells, their CD4+ and CD8+ subsets, and the state of T lymphocyte activation as assessed by the percentage of CD3+ cells expressing interleukin 2 receptor (IL-2R) (CD25) and the type II major histocompatibility antigen HLA-DR (using monoclonal antibodies from Becton Dickinson, Abingdon, UK).

#### IMMUNOHISTOCHEMISTRY OF ENDOBRONCHIAL BIOPSY SAMPLES

Both biopsy samples were processed into glycol methacrylate resin for immunohistochemical analysis as reported previously.<sup>22</sup> Cells staining positively by immunohistochemistry were counted by a blinded observer. The mouse monoclonal antibodies used were antitryptase monoclonal antibody AA1 for mast cells,<sup>17,23</sup> EG2 (Pharmacia, Milton Keynes, UK), an antibody against cleaved cationic protein (ECP) for "activated" eosinophils,<sup>17,24</sup> and anti-CD4 and CD8 (Dako, High Wycombe, UK for CD8; Becton Dickinson for CD4) for T cells. For the T cell surface markers only those cells whose nucleus:cytoplasm ratio was clearly indicative of lymphocytes rather than eosinophils, macrophages, or dendritic cells were

counted. Cell associated IL-4 in the mucosa was identified by immunohistochemical analysis using two IgG<sub>1</sub> monoclonal antibodies directed against different epitopes of the IL-4 molecules, 3H4 and 4D9 (Ciba Geigy, Basle, Switzerland). To localise IL-4 to mast cells or CD3+ T cells, adjacent sections were stained with anti-IL-4 and anti-CD3 or AA1, and immunostaining was superimposed using the camera lucida (Leica UK Ltd, Milton Keynes, UK).<sup>21</sup> We have previously shown that staining with 3H4 results in a peripheral ring pattern, whereas that with 4D9 results in granular staining.<sup>25</sup> The observation that asthmatic subjects display a mainly peripheral ring staining pattern suggests that 3H4 identifies IL-4 secretion.

To control for non-specific staining we have used subclass matched monoclonal antibody at corresponding titres.

#### DATA ANALYSIS

Clinical data were analysed in one week periods and expressed as mean weekly values. To document any increase in disease activity associated with pollen exposure baseline data of the week preceding the first bronchoscopic examination were compared with the week before the second bronchoscopic examination, and to document any exacerbations the weeks immediately preceding the pollen season were compared with the peak of the season.

The cell populations in BAL fluid were analysed as absolute numbers per ml BAL fluid derived from their relative numbers counted in cytopins. The CD4+, CD8+, CD25+, and HLA-DR+ cells were shown as a percentage of CD3+ lymphocytes. The cells in the biopsy samples were counted separately in the epithelium and submucosa by a blinded observer and shown as numbers of cells/mm<sup>2</sup> of basement membrane and mm<sup>2</sup> of submucosa.<sup>17</sup>

Differences between logarithmically transformed PC<sub>20</sub> methacholine and IgE values and the FEV<sub>1</sub> (% predicted) in and out of season were sought by the two tailed paired Student's *t* test. All the other analyses were performed using the Wilcoxon's test for paired data.

#### Results

Pollen counts reached the desired level of more than 50/mm<sup>3</sup> by 18 June (fig 1) and, to enable at least one week of consistent exposure to higher concentrations of pollen, the second bronchoscopic examinations were deferred until July. The in season pollen counts were relatively low by comparison with previous years, with a peak of 318 grains/m<sup>3</sup> counted during July.

#### CLINICAL DATA

Before the first bronchoscopic examination all the subjects were mildly symptomatic but had been stable for at least six weeks. In parallel with the rise in pollen counts all the subjects reported an increase in asthma symptoms. Analysis of symptom scores confirmed a clinical deterioration from mid June to the beginning of

Median (range) cell numbers ( $\times 10^3/\text{ml}$  bronchoalveolar fluid) recovered before and during the pollen season

	Total leucocytes	Macrophages	Neutrophils	Eosinophils	Lymphocytes	Mast cells
Pre-season	90.0 (37.2–205.0)	77.3 (21.1–189.4)	0.4 (0.0–5.3)	1.3 (0.1–12.1)	14.2 (4.0–61.7)	0.13 (0.03–0.83)
In-season	88.8 (22.4–225.0)	78.3 (15.9–194.5)	0.5 (0.1–6.3)	1.2 (0.0–9.1)	5.6 (2.3–47.7)*	0.02 (0.0–0.93)*

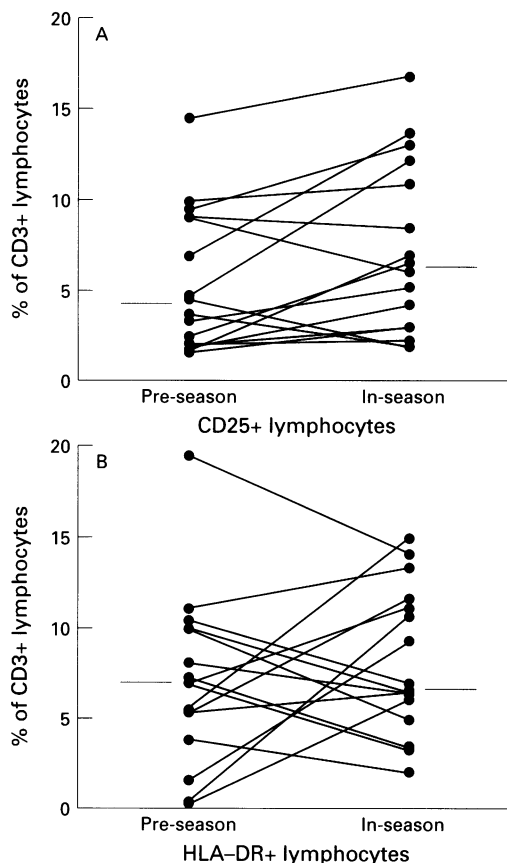
\*  $p < 0.05$ .

Figure 2 Changes in the percentage of (A) activated CD3+ T lymphocytes bearing surface IL-2R ( $p < 0.05$ ) and (B) HLA-DR ( $p = \text{NS}$ ) in bronchoalveolar fluid during the pollen season.

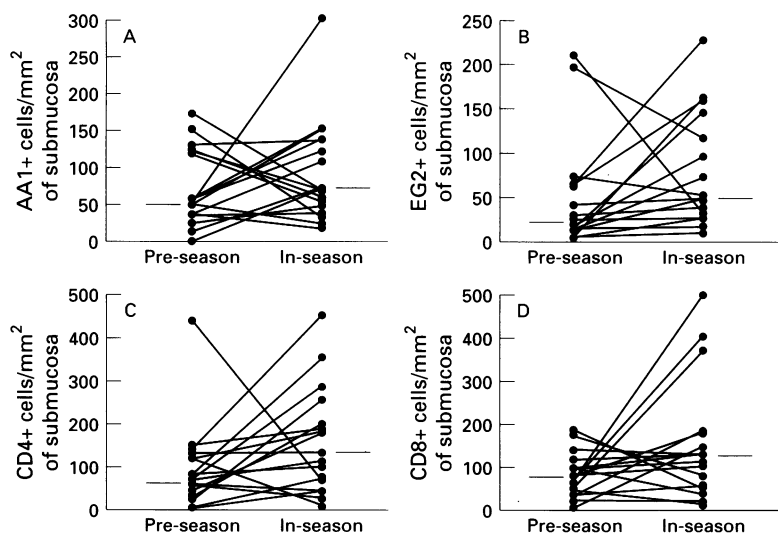


Figure 3 Changes in the counts of (A) submucosal mast cells ( $p = \text{NS}$ ), (B) eosinophils ( $p = \text{NS}$ ), (C) CD4+ ( $p < 0.05$ ), and (D) CD8+ cells ( $p = \text{NS}$ ) during the pollen season.

August in all but two subjects which followed, rather than paralleled, the peak of the pollen count (fig 1). For clarity, in fig 1 the weeks in May to August are labelled 1–15 and the baseline symptoms as week 0. Consistent with a significant seasonal exacerbation of asthma, comparison between weeks 5 and 6 in May, at a time immediately preceding the pollen season, and week 13 in July when bronchoscopic examination was performed and when the pollen counts peaked, showed a significant ( $p < 0.05$ ) increase in asthma symptoms (fig 1). However, comparison of the weeks before the first and second bronchoscopic examinations showed no significant increase in asthma symptoms and no increased demand for salbutamol. Only nine subjects had a decrease in  $\text{PC}_{20}$  methacholine and only five had an increase in PEF variation, neither of which were significant.

Total serum levels of IgE increased from geometric mean (range) 216 IU (35–1980 IU) to 241 IU (16–3980 IU), but this change was not significant.

#### CELLS IN BAL FLUID

The median amount of BAL fluid recovered during the first bronchoscopic examination (66 ml) was not significantly different from that during the second (56 ml). There were no significant changes in the numbers of total inflammatory cells, neutrophils, eosinophils, or macrophages (table), but there was a significant ( $p < 0.02$ ) sixfold decrease in metachromatic cells staining with toluidine blue (table). Similarly, there was a significant ( $p < 0.05$ ) decrease of more than twofold in the numbers of lymphocytes (table). Paired flow cytometric analyses were possible in 16 subjects. Although there were no changes in the percentage of CD4+ and CD8+ cells, a small (less than twofold) but significant ( $p < 0.05$ ) increase was seen in the percentage of CD3+ lymphocytes expressing the activation marker IL-2R. There were no significant changes in HLA-DR expression (fig 2).

#### MUCOSAL CELLS

Quantitation of cells in the submucosa was possible in all the subjects, but was not possible in the epithelium in one subject because of complete epithelial denudation.

Comparison of pre-season and in-season biopsy samples showed no significant changes in inflammatory cell numbers in the epithelium (data not shown). The number of mast cells in the submucosa did not change during the season (fig 3), nor were any significant changes seen in the numbers of submucosal CD8+ cells. However, there was a significant ( $p < 0.05$ )

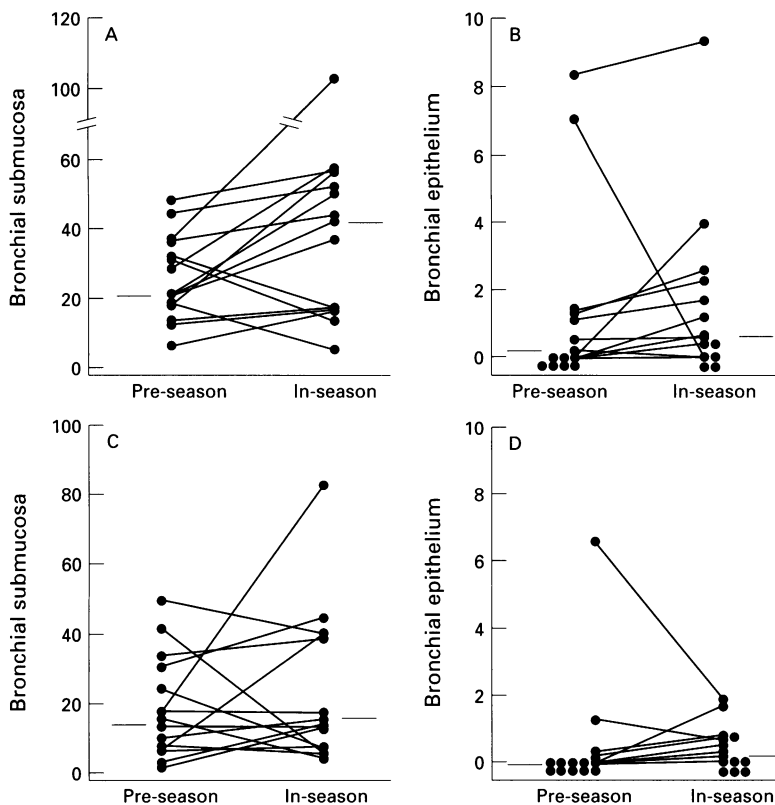


Figure 4 Changes in the numbers of mast cells/mm<sup>2</sup> staining positively with the monoclonal antibody 3H4 detecting secreted IL-4 in (A) the submucosa ( $p < 0.05$ ) and (B) the epithelium ( $p = NS$ ), and with 4D9 detecting IL-4 stored in granules in (C) the submucosa ( $p = NS$ ) and (D) the epithelium ( $p = NS$ ) during the pollen season.

almost twofold increase in submucosal CD4+ cells from a median of 67 cells/mm<sup>2</sup> to 127 cells/mm<sup>2</sup> (fig 3). During the season there was also an increase in the number of EG2+ eosinophils in the submucosa in 13 out of 17 subjects, but the difference was not significant (fig 3).

Immunohistochemical staining with both monoclonal antibodies for IL-4 showed a median of 21.3 cells/mm<sup>2</sup> (range 6.2–47.9) staining with the 3H4 antibody and 15.5 cells/mm<sup>2</sup> (1.5–50.0) staining with the 4D9 antibody (fig 4) in the submucosa before the pollen season. As shown by staining of adjacent sections, all the cells that contained IL-4 also contained tryptase which identified them as mast cells, but no staining for IL-4 was localised to CD3+ cells. During the pollen season there was a significant ( $p < 0.05$ ) twofold increase in the numbers of mast cells staining with the 3H4 antibody (median 41.7, range 5.1–102.8 cells/mm<sup>2</sup> of submucosa) but not in those staining with 4D9 (fig 4). In the epithelium the median (range) number of mast cells staining with 3H4 antibody increased from 0.1 (0–8.4) to 0.7 (0–9.4) but this change was not significant. There was no difference between the epithelial counts of 4D9+ cells before and during the pollen season (median 0 (range 0–6.6) versus 0.3 (1–1.9)).

### Discussion

This study has provided evidence which suggests that natural exposure to grass pollen leads to cellular changes in the airways of grass pol-

len-sensitive atopic asthmatic subjects. The changes were most prominent within the T lymphocyte population and consisted of a significant increase in the numbers of CD4+ cells in the submucosa and an increase in the expression of IL-2R on CD3+ cells in BAL fluid, adding support for an important role of these cells in the mucosal allergic response. The number of metachromatic cells decreased significantly during the season, a finding which we interpret as indicating degranulation. As previously shown, IL-4, a multifunctional cytokine of particular relevance to asthma, was localised to mast cells and not to T cells. The increase in the ring staining pattern with the 3H4 antibody for this cytokine seen during the season was consistent with increased production and secretion of IL-4 by mast cells. This adds further evidence that, in addition to being a source of inflammatory mediators with bronchoactive and vasoactive properties, mast cells may participate in the regulation of allergic responses.

Although most of the subjects experienced significant clinical deterioration over the 2–3 weeks preceding the second bronchoscopic examination which coincided with a period of increasing pollen counts, comparison of asthma activity between the periods immediately before the two bronchoscopies showed no overall difference. This apparent discrepancy could be explained by polysensitisation in most of our subjects and the complex multifactorial nature of asthma which makes it difficult to conduct studies of the effects of any single provoking factor of asthma. In addition, the total allergenic burden, identified in previous studies to be important in demonstrating a seasonal effect,<sup>13,26</sup> was relatively low compared with previous seasons. We assume that the level of exposure to house dust mite during the whole period of the study was constant and are not aware of any studies showing seasonal changes in the way this perennial allergen contributes to mucosal inflammation and asthma symptoms. However, triggers such as cold air and pollution associated with exercise could have contributed more to the symptoms in the winter than in spring and summer when pollen exposure in sensitised individuals may be more important. It is therefore possible that the effects of non-allergenic triggers, which were not controlled for in the study, may have cancelled differences in symptoms attributable to allergen exposure between the two seasons. Nevertheless, the temporal link between the swift increase in asthma symptoms which followed the rise in pollen counts, associated with decreased ability of metachromatic cells to stain with toluidine blue (suggestive of degranulation) and increased expression of IL-2R (an early activation marker of T lymphocytes<sup>27</sup>) support a prompt response to allergenic stimuli.

Our study has also shown that inflammatory cell changes can increase without a parallel change in airways responsiveness that is characteristic of late asthmatic responses. Although airways hyperresponsiveness has been closely linked to inflammation, it is also apparent – both in animal models<sup>28</sup> and in atopic humans<sup>29</sup>

– that mucosal inflammation may develop without an associated increase in airways responsiveness. The cellular changes in the lower airways which occur during natural allergen exposure were, in some respects, in keeping with those seen in the challenge model. The demonstration of increased numbers of CD4+ cells and increased IL-2R expression on T cells in BAL fluid is in keeping with the observations in the allergen challenge model in the lower airways,<sup>7</sup> nose,<sup>30</sup> and skin.<sup>31</sup> Increased expression of IL-2R is indicative of recent activation of T cells.<sup>27</sup> This observation, and the fact that HLA-DR expression, an indicator of chronically activated cells,<sup>32</sup> was not increased, suggests that T cell activation in our study had resulted from current stimulation by pollen allergen to which the subjects were all sensitive. However, whilst most studies show that allergen challenge results in an increase in lymphocytes in BAL fluid,<sup>4-7</sup> we have shown the opposite to occur during natural exposure. One possible explanation for this discrepancy is the difference between natural and experimental allergen exposure in the dose of allergen and the time course of delivery. Whereas a sudden release of lymphocyte chemotactic factors by luminal inflammatory cells that follows allergen challenge may result in a large gradient between the lumen and blood vessels, a more protracted exposure to small quantities of allergen could in fact lead to retention of these cells within the bronchial mucosa. We have not been able to show a statistically significant rise in mucosal eosinophil counts which is seen to occur following allergen challenge; however, in most subjects an increased eosinophilia could be seen. Although we have not been able to follow the dynamics of cellular influx, the more prominent changes in T cell numbers and activation relative to eosinophil infiltration would suggest that T cell changes may possibly precede those of eosinophils.

In contrast to other studies,<sup>33</sup> we have not detected any significant mast cell migration during the pollen season. We have shown a significant sixfold decrease in metachromatic cells in BAL fluid without a parallel decrease in tryptase positive cells in the mucosa. We interpret this apparent discrepancy between the BAL fluid and tissue compartment as possibly being due to differences in methods of detection,<sup>34</sup> states of cell activation, and metachromatic cell populations. The immunohistochemical procedure with antitryptase antibodies is of greater sensitivity than metachromatic staining methods<sup>23</sup> and may allow detection of relatively more cells which have lost their granule contents. In our previous studies we have clearly shown that most of IL-4 is localised to mast cells<sup>15,22</sup> and, because only stored granule associated cytokine can be detected by immunohistochemistry, IL-4 cannot be detected in T cells. The capacity of metachromatic cells to stain with toluidine blue decreases with loss of granular content. This has been substantiated in a study of graft versus host reactions in the skin where degranulated mast cells can be seen by electron microscopy and not by toluidine blue staining.<sup>34</sup> It is also

possible that the metachromatic stains in the lumen may have had greater exposure to allergen and may thus have been in a more degranulated state. Without a reliable way of distinguishing between mast cells and basophils in BAL fluid we could not differentiate between these two metachromatic cells, thus leaving open the question as to the type of metachromatic cell that was affected by pollen exposure.

We have found an increase in staining for secreted IL-4 which was localised to mast cells, a finding which suggests mast cell activation. It is now well established that mast cells produce and secrete a variety of cytokines.<sup>25</sup> Immunohistochemical studies of both the upper and lower respiratory mucosae have shown that the number of mast cells that display a peripheral ring pattern of staining with the 3H9 antibody is increased in atopic asthmatic and rhinitic subjects,<sup>15,25</sup> suggesting ongoing secretion of preformed IL-4. In this study we provide for the first time in vivo evidence to suggest that exposure to natural allergen results in increased IL-4 secretion by these cells. This could provide possible explanations for some of the observations in this study. Through its capacity to upregulate the vascular cell adhesion molecule 1 (VCAM-1) on endothelial cells, IL-4 is involved in the very late antigen (VLA)-4 dependent recruitment of eosinophils and T cells.<sup>35,36</sup> The effects of mast cells would be potentiated by activated IL-2R-bearing T cells which would contribute to both numbers and activation of eosinophils and mast cells.<sup>37</sup> Although IgE levels rose slightly during the season, the increase did not reach statistical significance, but it is possible that further stimulation with allergen and IL-4 would have resulted in a significant rise in IgE. We have not analysed specific IgE which may have increased, nor have we been able to analyse production of IgE in the lungs which may have taken place without leading to a systemic rise.

In conclusion, we have found changes in the inflammatory cell numbers and activity of lower airways mucosal inflammation associated with exposure to natural allergen. We believe that the observed activation of mast cells, and the activation and recruitment of T cells and possibly eosinophils into the airway wall, may have resulted in the observed cellular changes which in turn could have contributed to the exacerbations of asthma. We have not found a simple relationship between allergen exposure and asthma symptoms in these polysensitised asthmatic subjects during a prolonged period of observation. Finally, in the natural setting the production of proinflammatory cytokines, such as IL-4, and an influx and activation of T cells may precede the accumulation of activated eosinophils in the airways mucosa.

The authors would like to acknowledge Dr Christoph Heusser for making available the monoclonal anti-IL-4 antibodies 3H4 and 4D9 and Jane Ducey for technical assistance during bronchoscopy and excellent patient care.

The study was supported by a Programme Grant from the British Medical Research Council. Dr R Djukanović was a recipient of the TV James Fellowship awarded by the British Medical Association.

1 Metzger WJ, Richerson HB, Worden K, Monick H, Hunninghake GW. Bronchoalveolar lavage of allergic asthmatic

- patients following allergen bronchoprovocation. *Chest* 1986;89:477-83.
- 2 De Monchy JGR, Kauffman HK, Venge P, Koeter GH, Jansen HM, Sluiter HJ, *et al.* Bronchoalveolar eosinophilia during allergen-induced late asthmatic reactions. *Am Rev Respir Dis* 1985;131:373-6.
  - 3 Rossi GA, Crimi E, Lantero S, Gianiorio P, Oddera S, Crimi P, *et al.* Late-phase asthmatic reaction to inhaled allergen is associated with early recruitment of eosinophils in the airways. *Am Rev Respir Dis* 1991;144:379-83.
  - 4 Diaz P, Gonzales MC, Galleguillos FR, Ancic P, Cromwell O, Shepherd D, *et al.* Leukocytes and mediators in bronchoalveolar lavage during allergen-induced late-phase asthmatic reactions. *Am Rev Respir Dis* 1989;139:1383-9.
  - 5 Metzger WJ, Zavala D, Richerson HB, Moseley P, Iwamoto P, Monick M, *et al.* Local allergen challenge and bronchoalveolar lavage of allergic asthmatic lungs. Description of the model and local airway inflammation. *Am Rev Respir Dis* 1987;135:433-40.
  - 6 Gonzalez MC, Diaz P, Galleguillos FR, Ancic P, Cromwell O, Kay AB. Allergen-induced recruitment of bronchoalveolar (OKT4) and suppressor (OKT8) T-cells in asthma: relative increases in OKT8 cells in single early responders compared with those in late-phase responders. *Am Rev Respir Dis* 1987;136:600-4.
  - 7 Gerblich AA, Salik H, Schuyler MR. Dynamic T-cell changes in peripheral blood and bronchoalveolar lavage after antigen bronchoprovocation in asthmatics. *Am Rev Respir Dis* 1991;143:533-7.
  - 8 Cartier A, Thomson NC, Frith PA, Roberts R, Hargreave FE. Allergen-induced increases in bronchial responsiveness to histamine; relationship to the late asthmatic response and change in airway caliber. *J Allergy Clin Immunol* 1982;70:170-7.
  - 9 Gleich GJ. The late phase of the immunoglobulin E-mediated reaction: a link between anaphylaxis and common allergic disease. *J Allergy Clin Immunol* 1984;70:160-9.
  - 10 Kaliner M. Hypothesis on the contribution of late-phase allergic responses to the understanding and treatment of allergic diseases. *J Allergy Clin Immunol* 1984;73:311-4.
  - 11 Boulet L-P, Cartier A, Thomson NC, Roberts RS, Dolovich J, Hargreave FE. Asthma and increases in nonallergic bronchial responsiveness from seasonal pollen exposure. *J Allergy Clin Immunol* 1983;71:399-406.
  - 12 Pipkorn U, Karlsson G, Enerback L. The cellular response of the human allergic mucosa to natural allergen exposure. *J Allergy Clin Immunol* 1988;82:1046-54.
  - 13 Rak S, Bjornson A, Hakanson L, Sorenson S, Venge P. The effect of immunotherapy on eosinophil accumulation and production of eosinophil chemotactic activity in the lung of subjects with asthma during natural pollen exposure. *J Allergy Clin Immunol* 1991;88:878-88.
  - 14 Del Prete, Maggi E, Parronchi P, Chretien I, Tiri A, Macchia D, *et al.* IL-4 is an essential co-factor for IgE synthesis induced *in vitro* by human T cell clones and their supernatants. *J Immunol* 1988;140:4193-8.
  - 15 Bradding P, Roberts JA, Britten KM, Montefort S, Djukanovic R, Heusser CH, *et al.* Interleukins (IL)-4, -5, -6, and TNF $\alpha$  in normal and asthmatic airways: evidence for the human mast cell as an important source of these cytokines. *Am J Respir Cell Mol Biol* 1994;10:471-80.
  - 16 Chai H, Fan RS, Frolich LA, Mathison DA, McLean JA, Rosenthal RR, *et al.* Standardization of bronchial inhalation challenge procedures. *J Allergy Clin Immunol* 1975;56:323-7.
  - 17 Djukanovic R, Wilson JW, Britten KM, Wilson SJ, Walls AF, Roche WR, *et al.* Quantitation of mast cells and eosinophils in the bronchial mucosa of symptomatic atopic asthmatics and healthy control subjects using immunohistochemistry. *Am Rev Respir Dis* 1990;142:863-71.
  - 18 Workshop summary and guidelines. Investigative use of bronchoscopy, lavage, and bronchial biopsies in asthma and other airway diseases. *J Allergy Clin Immunol* 1991;88:808-14.
  - 19 Djukanovic R, Wilson JW, Lai CKW, Holgate ST, Howarth PH. The safety aspects of fiberoptic bronchoscopy, bronchoalveolar lavage, and endobronchial biopsy in asthma. *Am Rev Respir Dis* 1991;143:772-7.
  - 20 Walls AF, Bennett AR, McBride HM, Glennie MJ, Holgate ST, Church MK. Human mast cells tryptase: a biochemical marker for mast cell degranulation. *Biochem Soc Trans* 1989;17:728-9.
  - 21 Wilson JW, Djukanovic R, Howarth PH, Holgate ST. Lymphocyte activation in bronchoalveolar lavage and peripheral blood in atopic asthma. *Am Rev Respir Dis* 1992;145:958-60.
  - 22 Bradding P, Feather IH, Howarth PH, Mueller R, Roberts JA, Britten K, *et al.* Interleukin 4 is localised to and released by human mast cells. *J Exp Med* 1992;176:1381-6.
  - 23 Walls AF, Jones DB, Williams JH, Church MK, Holgate ST. Immunohistochemical identification of mast cells in formaldehyde-fixed tissue using monoclonal antibody specific for tryptase. *J Pathol* 1990;162:119-26.
  - 24 Tai P-C, Spry CJF, Peterson C, Venge P, Olsson I. Monoclonal antibodies distinguish between storage and secreted forms of eosinophil cationic protein. *Nature* 1984;309:182-4.
  - 25 Bradding P, Feather IH, Wilson S, Bardin PG, Heusser CH, Holgate ST, *et al.* Immunolocalisation of cytokines in the nasal mucosa of normal and perennial rhinitic subjects: the mast cell as a source of IL-4, IL-5 and IL-6 in human allergic inflammation. *J Immunol* 1993;151:3853-65.
  - 26 Barbato A, Pisetta F, Ragusa A, Marcer G, Zacchello F. Modification of bronchial hyperreactivity during pollen season in children allergic to grass. *Ann Allergy* 1987;58:121-4.
  - 27 Cantrell DA, Smith KS. Transient expression of interleukin 2 receptors. *J Exp Med* 1983;158:1895-911.
  - 28 Chapman ID, Foster A, Morley J. The relationship between inflammation and hyperreactivity of the airways in asthma. *Clin Exp Allergy* 1993;23:168-71.
  - 29 Djukanovic R, Lai CKW, Wilson J, Britten KM, Wilson SJ, Roche WR, *et al.* Bronchial mucosal manifestations of atopy: a comparison of markers of inflammation between atopic asthmatics, atopic nonasthmatics and healthy controls. *Eur Respir J* 1992;5:538-44.
  - 30 Varney VA, Jacobson MR, Sudderick RM, Robinson DS, Irani A-MA, Schwartz LB, *et al.* Immunohistology of the nasal mucosa following allergen-induced rhinitis. *Am Rev Respir Dis* 1992;146:170-6.
  - 31 Frew AJ, Kay AB. The relationship between infiltrating CD4+ lymphocytes, activated eosinophils, and the magnitude of the allergen-induced late-phase cutaneous reaction in man. *J Immunol* 1988;141:4158-64.
  - 32 Cotner T, Williams JM, Christenson L, Shapiro HM, Strom TB, Strominger J. Simultaneous flow cytometric analysis of human T cell activation antigen expression and DNA content. *J Exp Med* 1983;157:461-72.
  - 33 Enerback L, Pipkorn U, Olafsson A. Intraepithelial migration of mucosal mast cells in hay fever: ultrastructural observations. *Int Arch Allergy Appl Immunol* 1986;81:289-97.
  - 34 Claman HN, Choi KL, Sujansky W, Vatter AE. Mast cell disappearance in chronic murine graft-vs-host disease (GVHD)-ultrastructural demonstration of phantom mast cells. *J Immunol* 1986;137:2009-13.
  - 35 Thornhill MH, Wellicome SM, Mahiouz DL, Lanchbury JSS, Kyan-Aung U, Haskard DO. Tumour necrosis factor combines with IL-4 or IFN- $\gamma$  to selectively enhance endothelial cell adhesiveness for T-cells. The contribution of vascular cell adhesion molecule-1-dependent and -independent binding mechanisms. *J Immunol* 1991;146:592-8.
  - 36 Schleimer RP, Sterbinsky SA, Kaiser J, Bickel CA, Klunk DA, Tomioka K, *et al.* IL-4 induces adherence of human eosinophils and basophils but not neutrophils to endothelium. Association with expression of VCAM-1. *J Immunol* 1992;148:1086-92.
  - 37 Bradley BL, Azzawi M, Jacobson M, Assoufi B, Collins JV, Irani A-M A, *et al.* Eosinophils, T-lymphocytes, mast cells, neutrophils, and macrophages in bronchial biopsy specimens from atopic subjects with asthma: comparison with biopsy specimens from atopic subjects without asthma and normal control subjects and relationship to bronchial hyperresponsiveness. *J Allergy Clin Immunol* 1991;88:661-74.