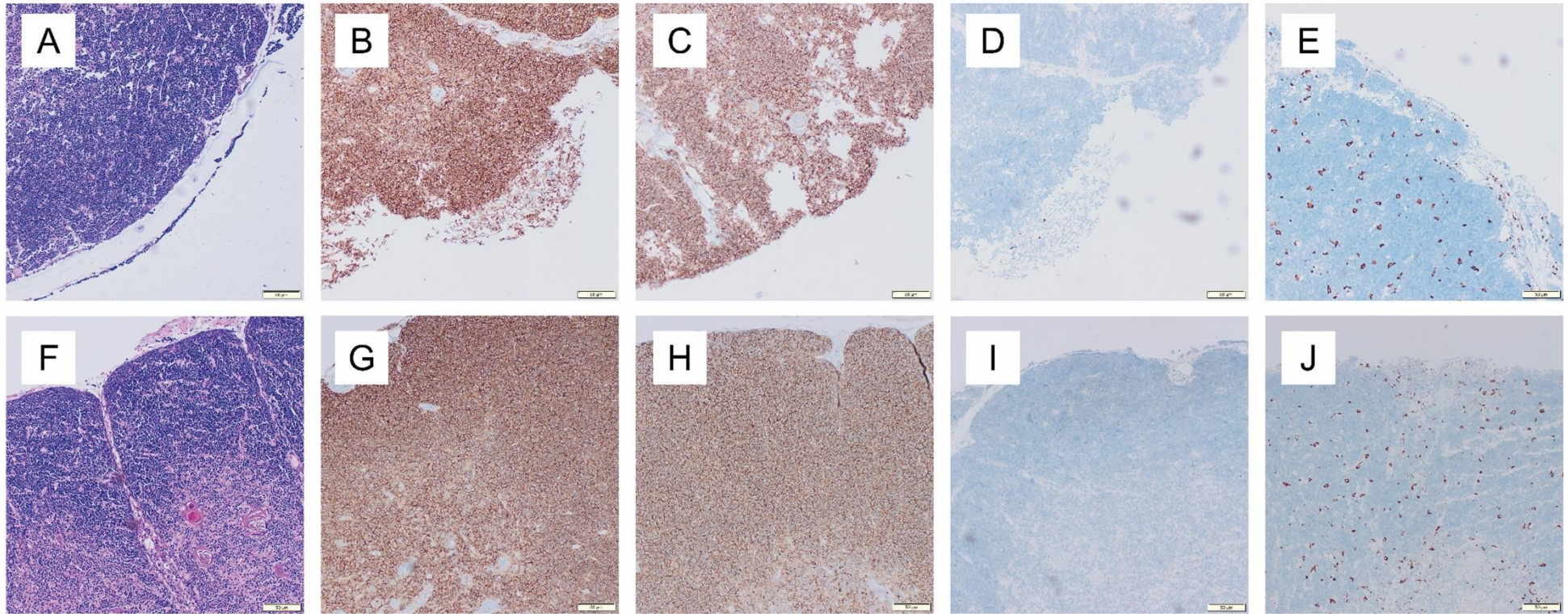


Age-related cytokine imbalance in the thymus in sudden infant death syndrome (SIDS)



Supplemental Figure S1 Histological staining of thymic tissue of a SIDS case (A-E) and a control case (F-J). A, F: HE-staining; B, G: CD4-staining; C, H: CD8-staining; D, I: CD138-staining; E, J: PGM-1-staining.