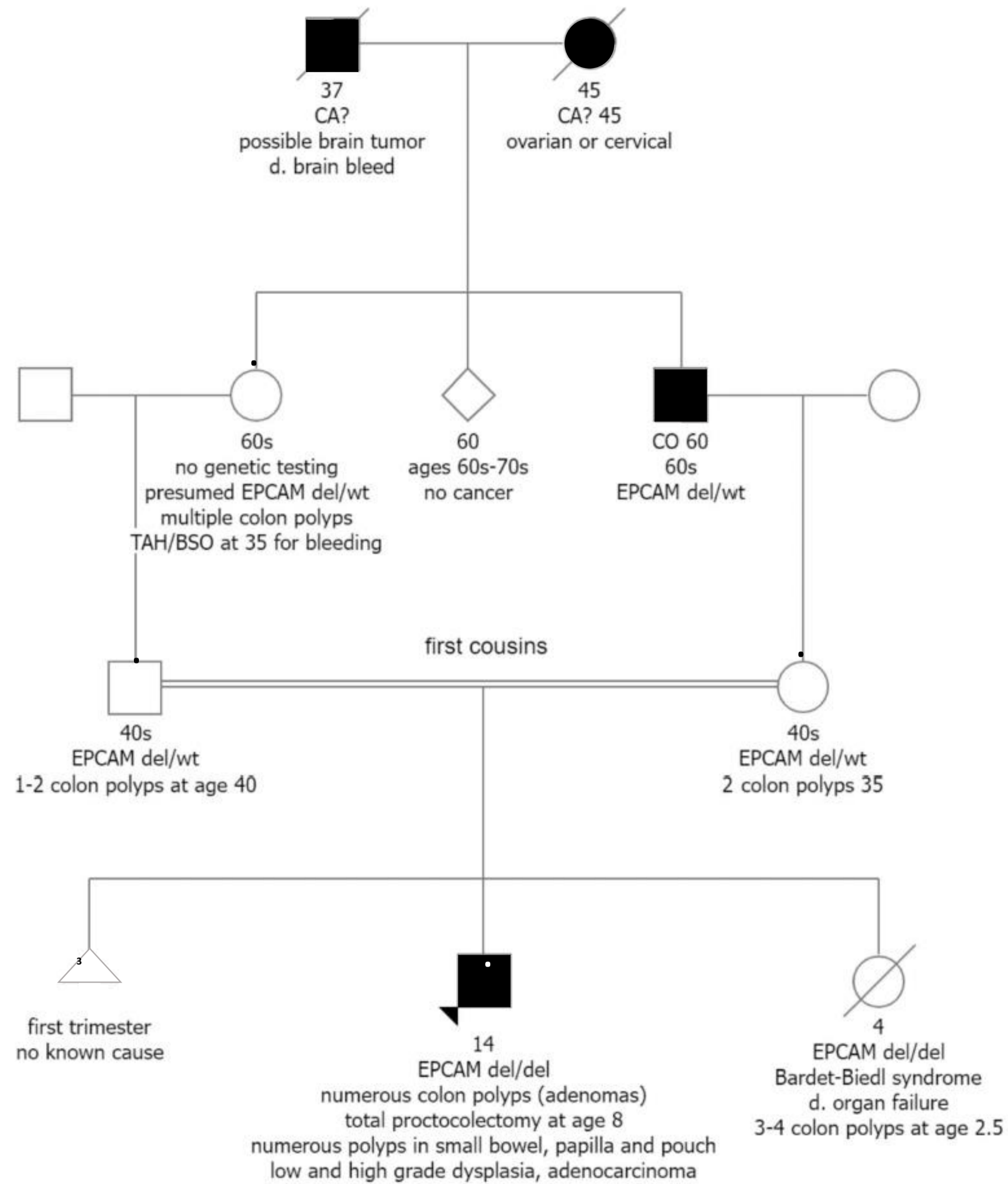
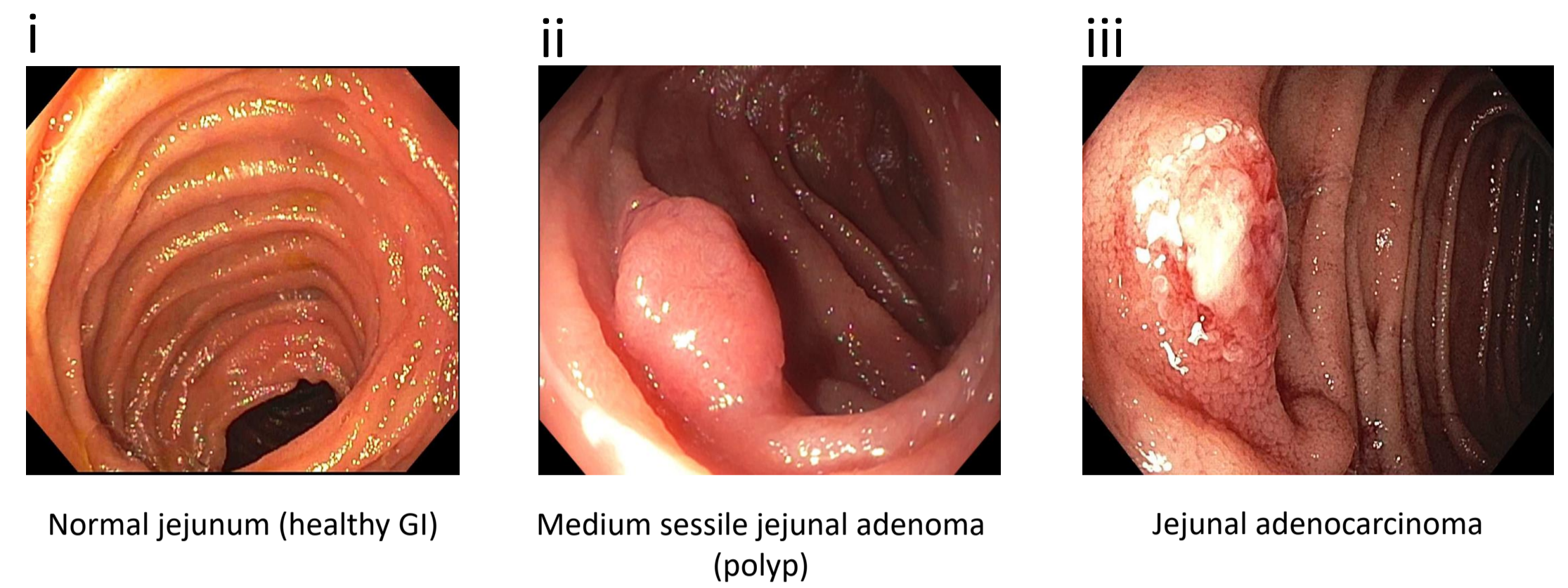

a**b**

Supplementary Figure 1: **a:** Pedigree of the proband and extended family. Proband is marked by an arrow. **b:** Scope pictures showing healthy GI tissue (normal jejunum), polyp (medium sessile jejunal adenoma) and jejunal adenocarcinoma.