

ONLINE ONLY

Supplemental material

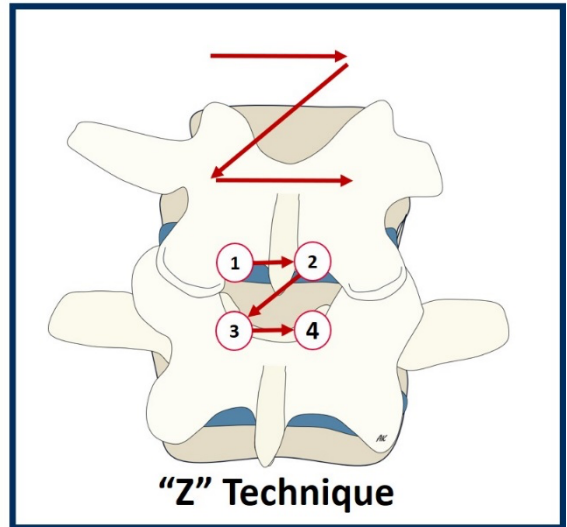
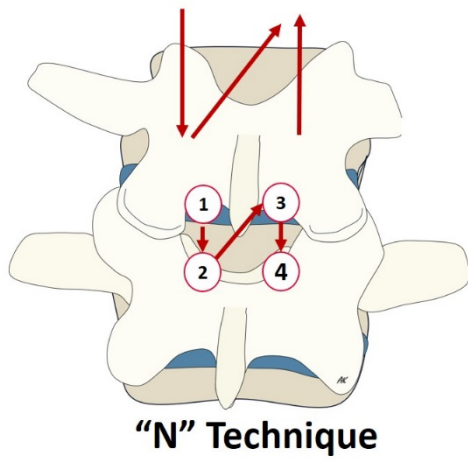
Five-step unilateral biportal endoscopic surgery for central lumbar canal stenosis: “Z” technique nuance

Kaen et al.

<https://thejns.org/doi/abs/10.3171/2024.1.FOCVID23182>

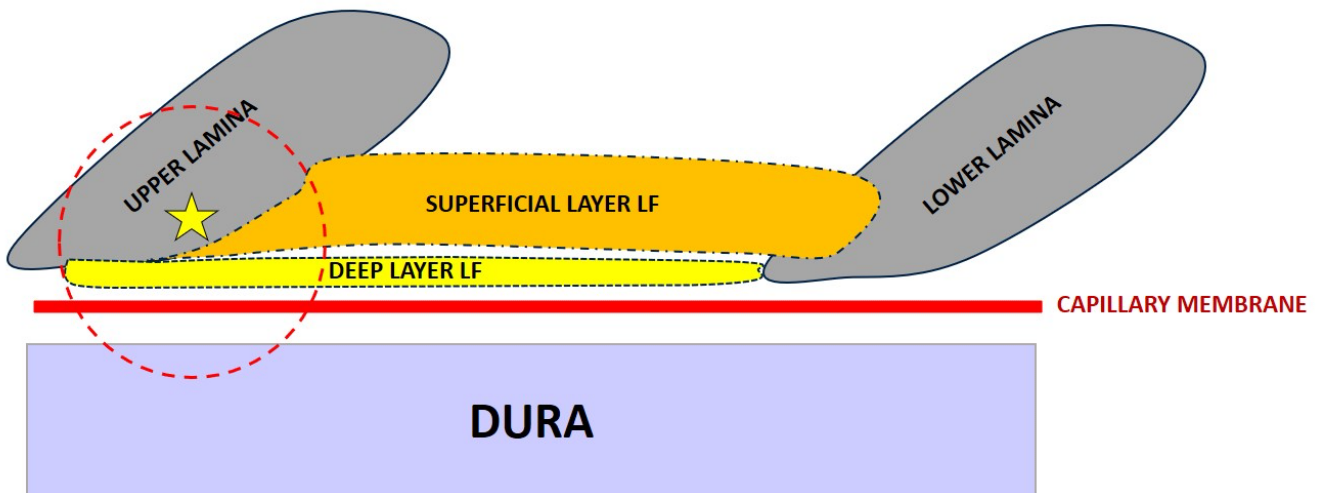
DISCLAIMER The *Journal of Neurosurgery* acknowledges that the following section is published verbatim as submitted by the authors and did not go through either the *Journal's* peer-review or editing process.

SURGICAL PLANNING



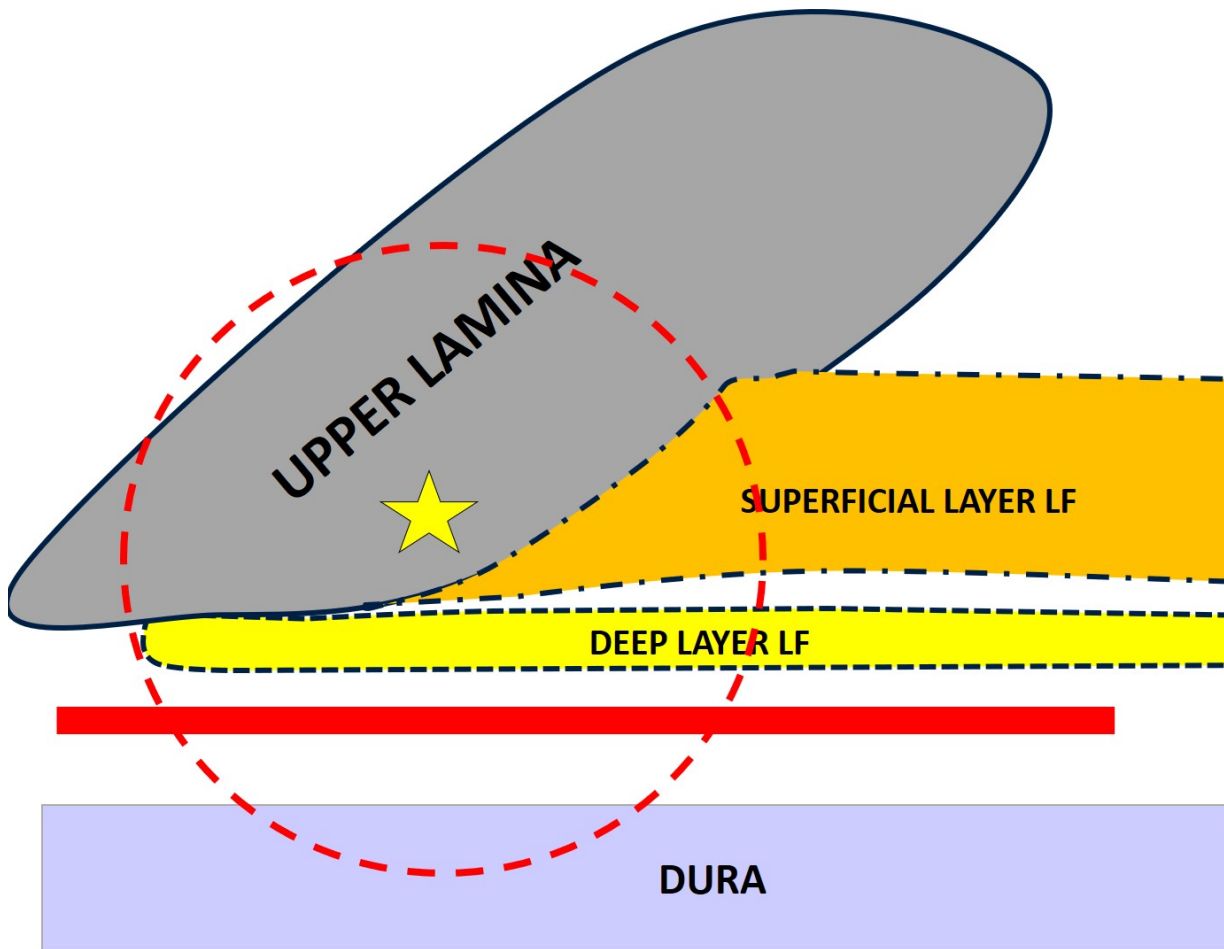
Supplementary Figure 1.

In these illustrations we show the sequential steps and the different between the classical "N" technique (right) and the new one "Z" technique (left).



Supplementary Figure 2.

Illustrations that show the different insertions of the two layers of the flum ligament.



Supplementary Figure 3.

Illustrations that show the "inner" spinous lamina point (star), where is easier to dissect the superficial from the deeper layer of flavum ligament.