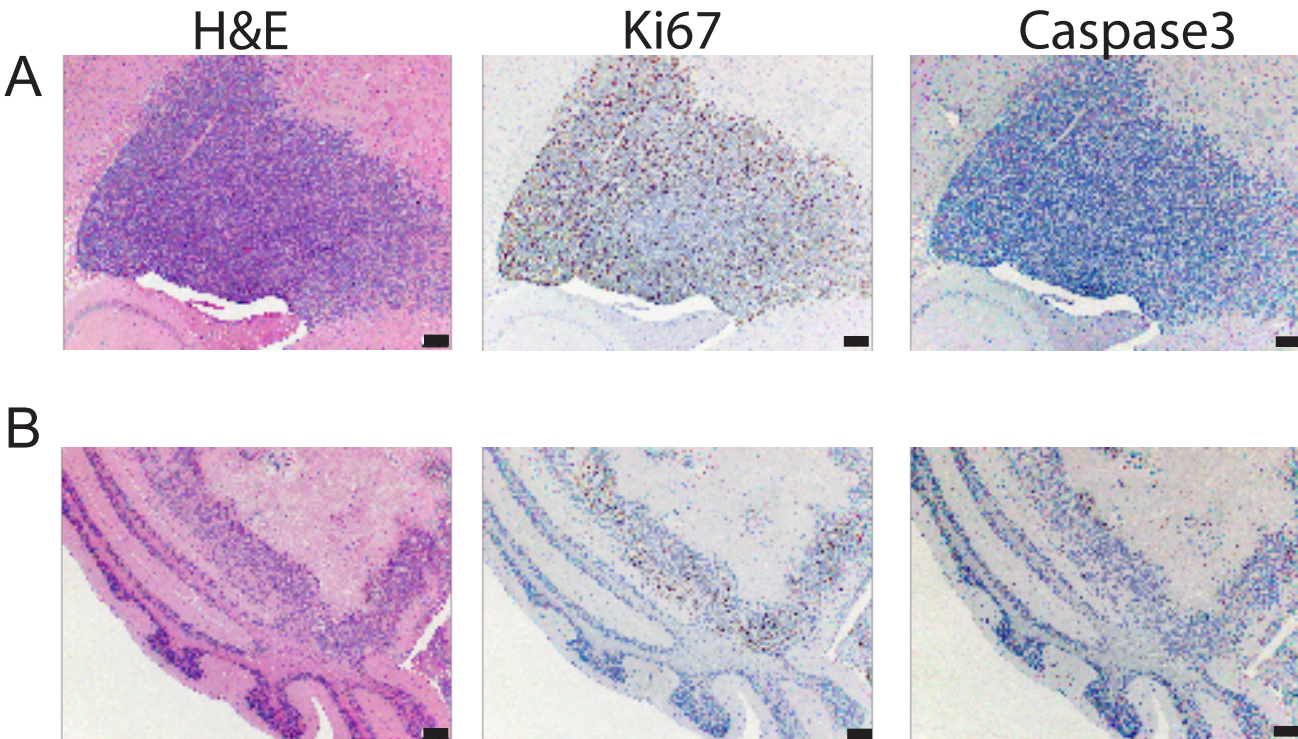


Figure S6



Supplemental Figure 6. MAF-928 in vivo mice had more metastatic lesions with radiation alone. A. H&E, Ki67, Caspase 3 scans of metastatic lesion in the olfactory bulb of mouse treated with radiation alone. Met has almost no necrosis with highly proliferative dense cells. B. H&E, Ki67, Caspase 3 from the same mouse with posterior fossa recurrence following radiation treatment. The posterior fossa recurrence has a larger necrotic core with highly proliferative cells on around the edges. Black bar denotes scale of 200 μm .