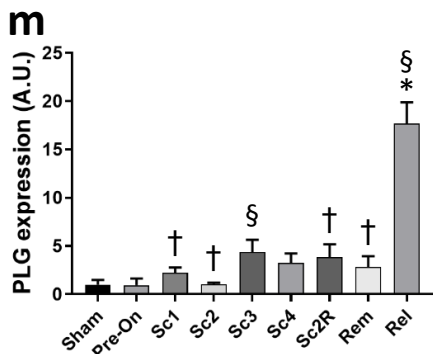
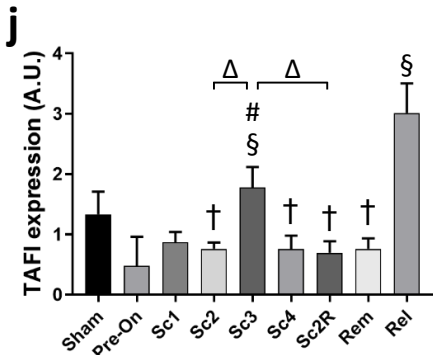
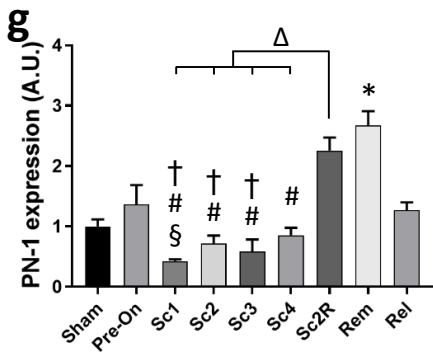
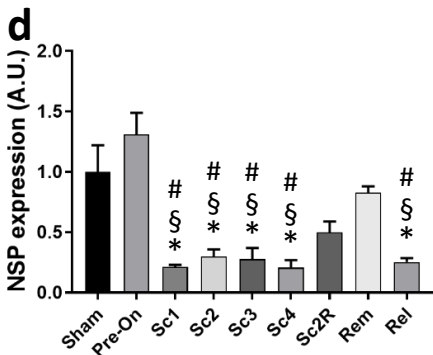
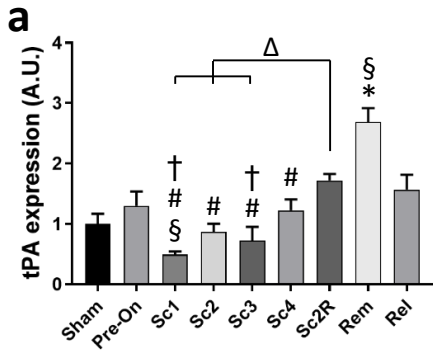
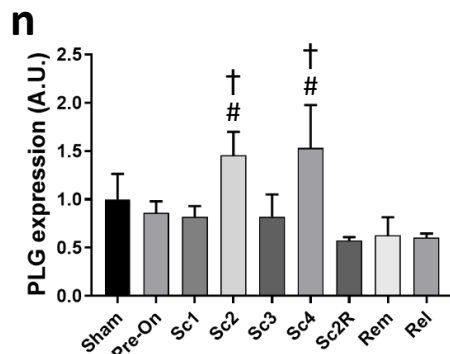
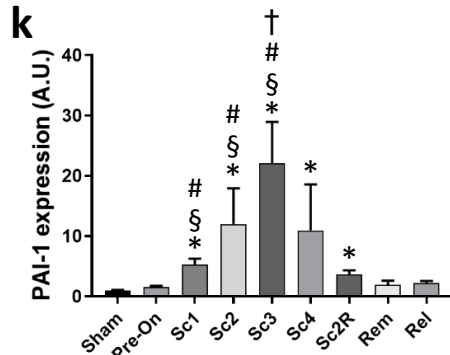
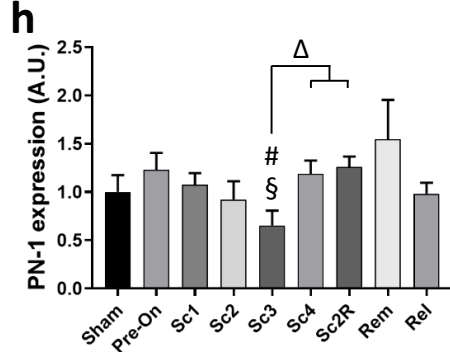
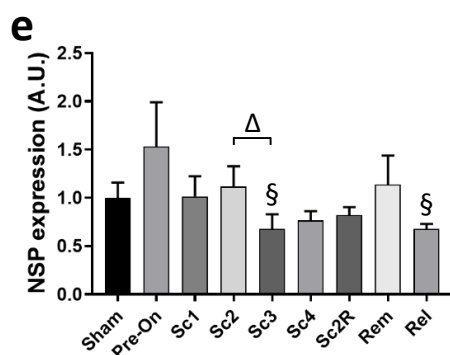
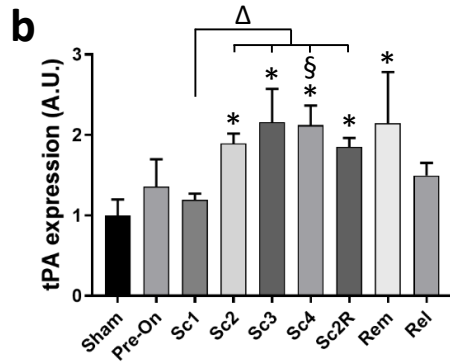


Spinal cord



Cerebellum



Forebrain

