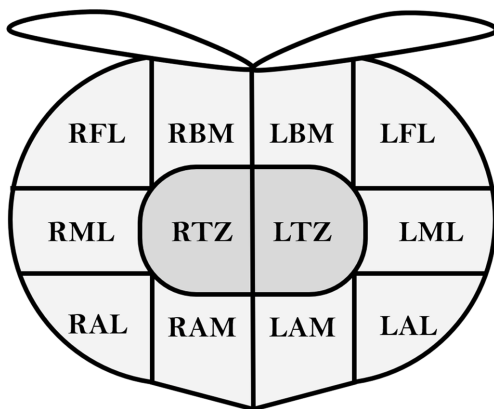


**Table S1** Initial risk stratification of prostate cancer according to 2023 NCCN Guidelines (6)

Risk group	Clinical/pathologic features
Very low	All of the following: cT1c, Gleason score 6, PSA <10 ng/mL, fewer than 3 prostate biopsy fragments/cores positive, ≤50% cancer in each fragment/core, PSA density <0.15 ng/mL/g
Low	All of the following but does not qualify for very low risk: cT1–cT2a, Gleason score 6, PSA <10 ng/mL
Intermediate	All of the following: . No high-risk or very-high-risk group features . One or more intermediate risk factor: cT2b–cT2c, Gleason score 7, PSA 10–20 ng/mL
Favorable	All of the following: . 1 intermediate risk factor . Gleason score 6 or 7 (3+4) . <50% biopsy cores positive
Unfavorable	One or more of the following: . 2 or 3 intermediate risk factors . Gleason score 7 (4+3) . ≥50% biopsy cores positive
High	No very-high risk features, exactly one of following: cT3a, Gleason score 8–10, PSA >20 ng/mL
Very high	At least one of following: cT3b–cT4, Gleason score 9–10, 2 or 3 high risk features, >4 cores with Gleason 8–10

Adapted with permission from the NCCN Clinical Practice Guidelines in Oncology (NCCN Guidelines®) for Prostate Cancer V.1.2024. ©2024 National Comprehensive Cancer Network, Inc. All rights reserved. The NCCN Guidelines® and illustrations herein may not be reproduced in any form for any purpose without the express written permission of NCCN. To view the most recent and complete version of the NCCN Guidelines, go online to <https://nccn.org/>. The NCCN Guidelines are a work in progress that may be refined as often as new significant data becomes available. NCCN, National Comprehensive Cancer Network; PSA, prostate-specific antigen.



**Figure S1** Labeling panel for TRUS-guided 12 core systemic biopsy of the prostate gland. RFL, right far lateral; RBM, right base medial; LBM, left base medial; LFL, left far lateral; RML, right mid lateral; RTZ, right transition zone; LTZ, left transition zone; LML, left mid lateral; RAL, right apex lateral; RAM, right apex medial; LAM, left apex medial; LAL, left apex lateral; TRUS, transrectal ultrasonography.