

# Ultrasound Imaging Modality Evaluation

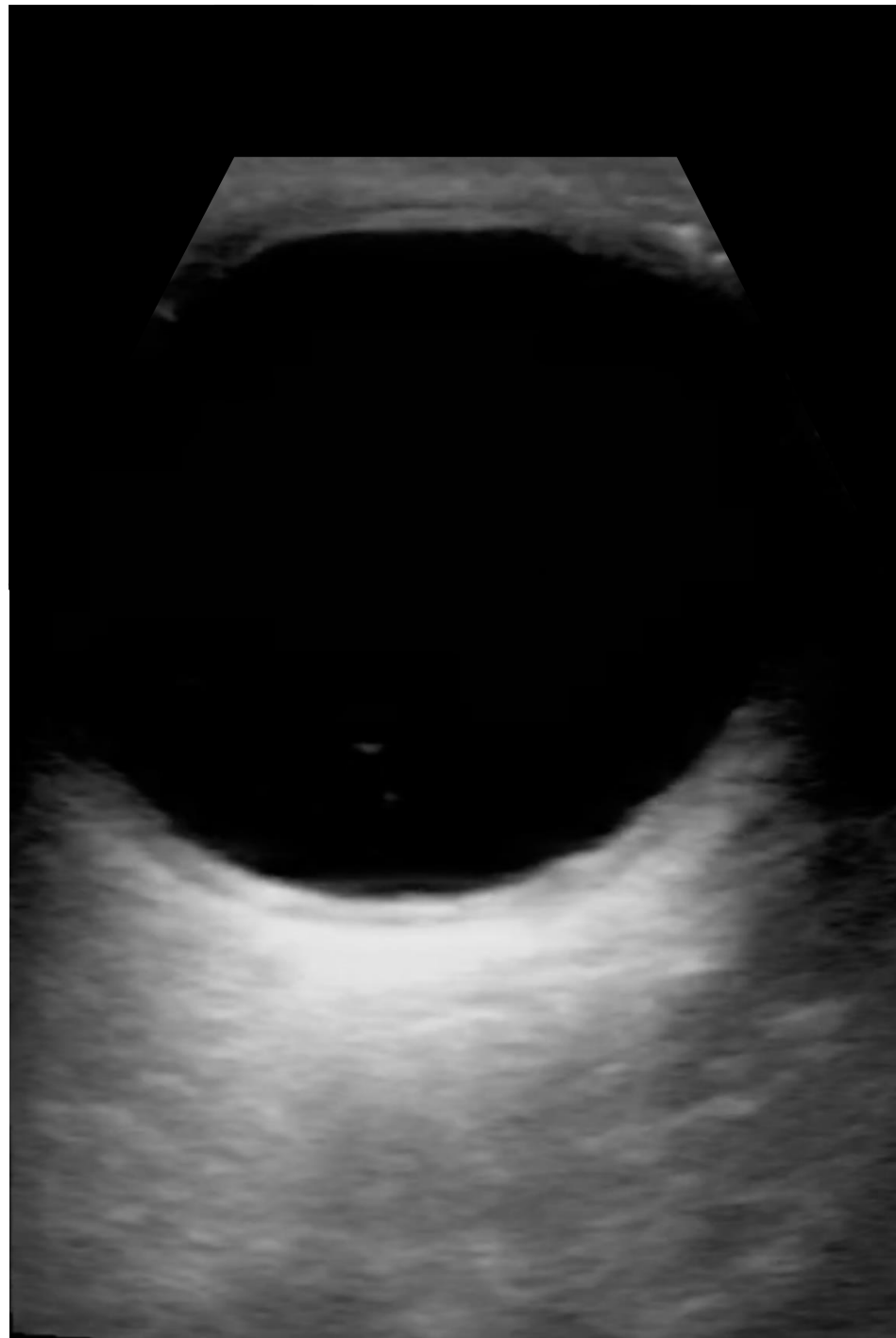
Scan QR Code to Start Questionnaire →

OR go to

<https://tinyurl.com/y3pjs8gl>

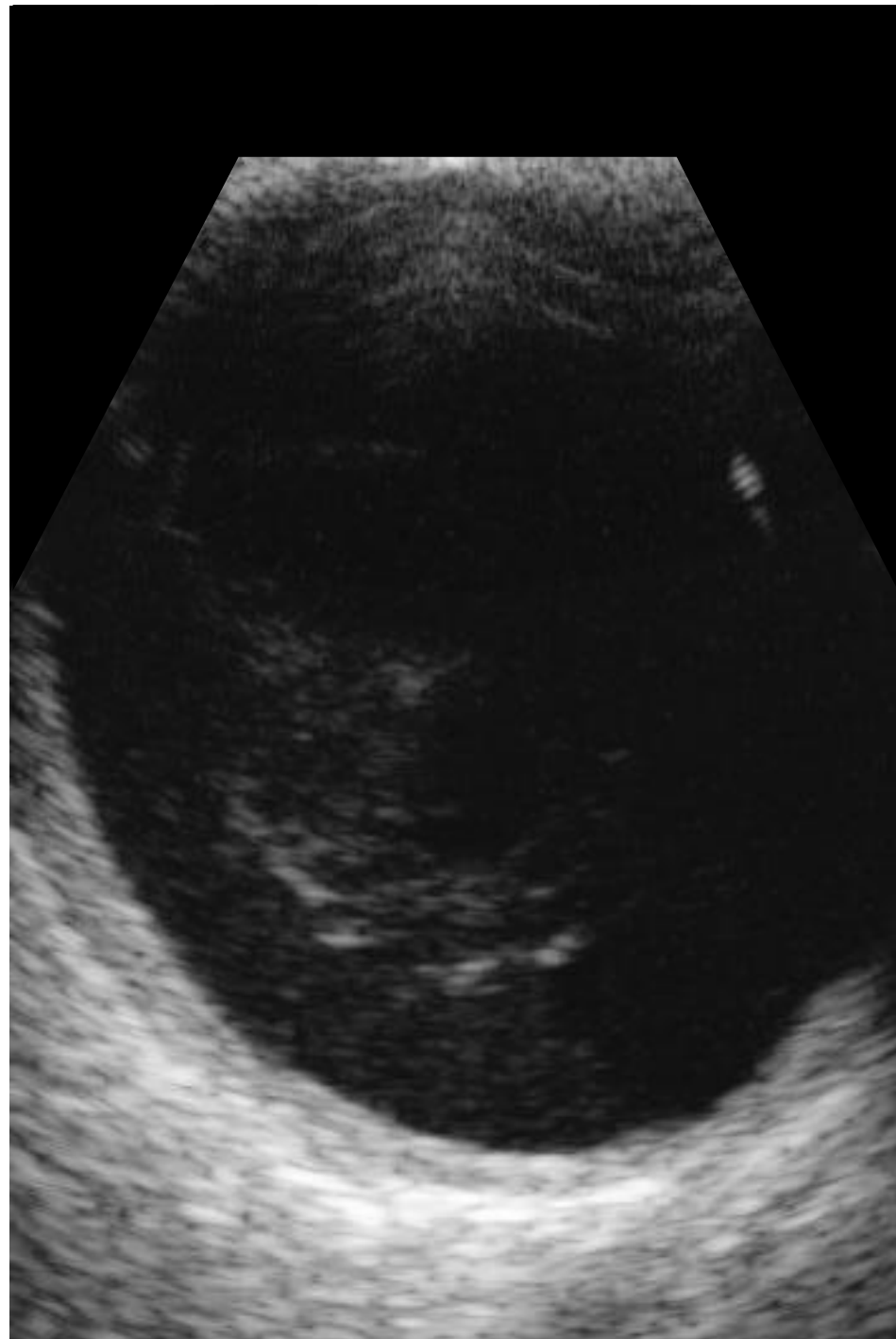


1A



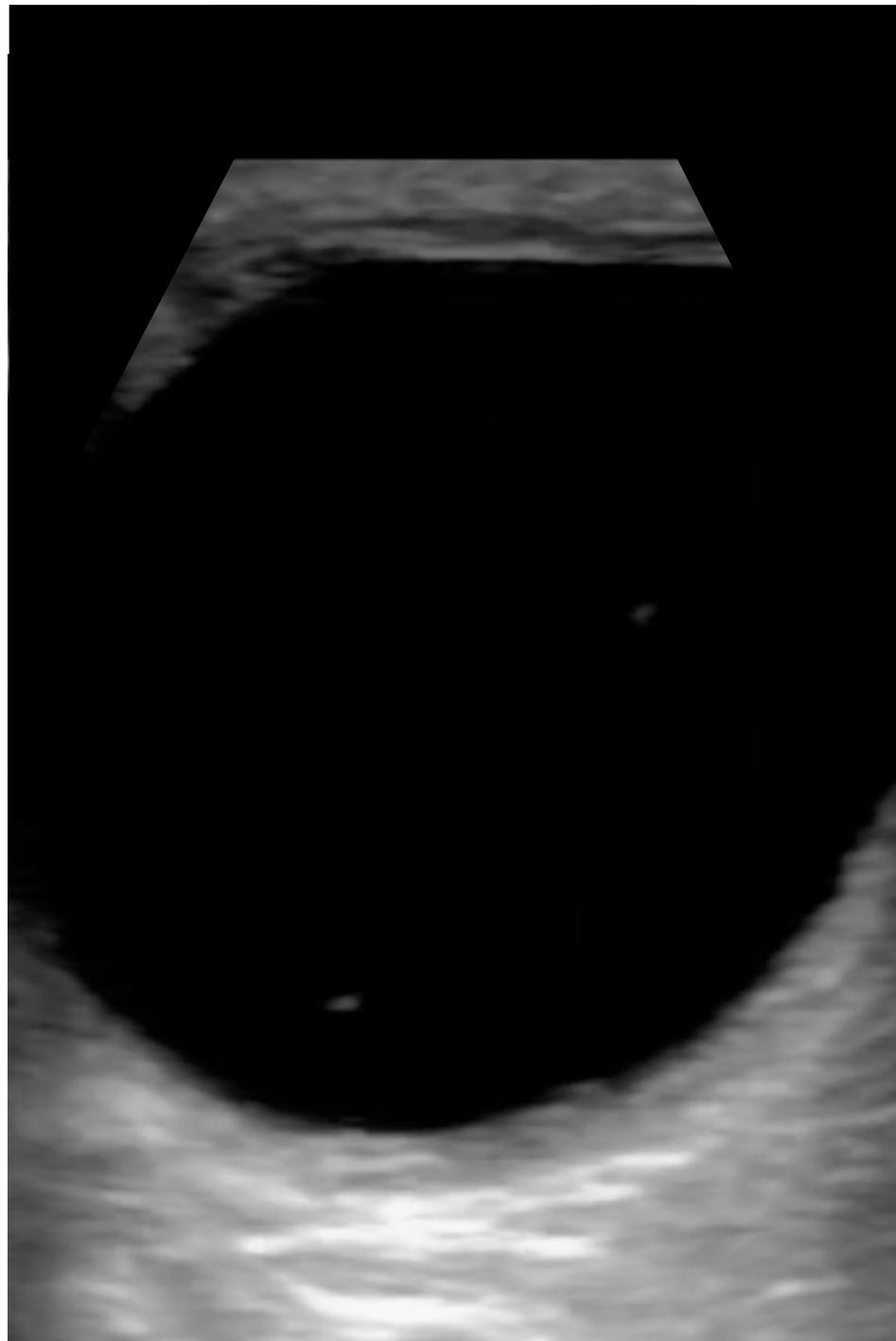
CC: Vitreous Hemorrhage  
51 y/o m, hx DPR, c/o  
heme OD

# 1B



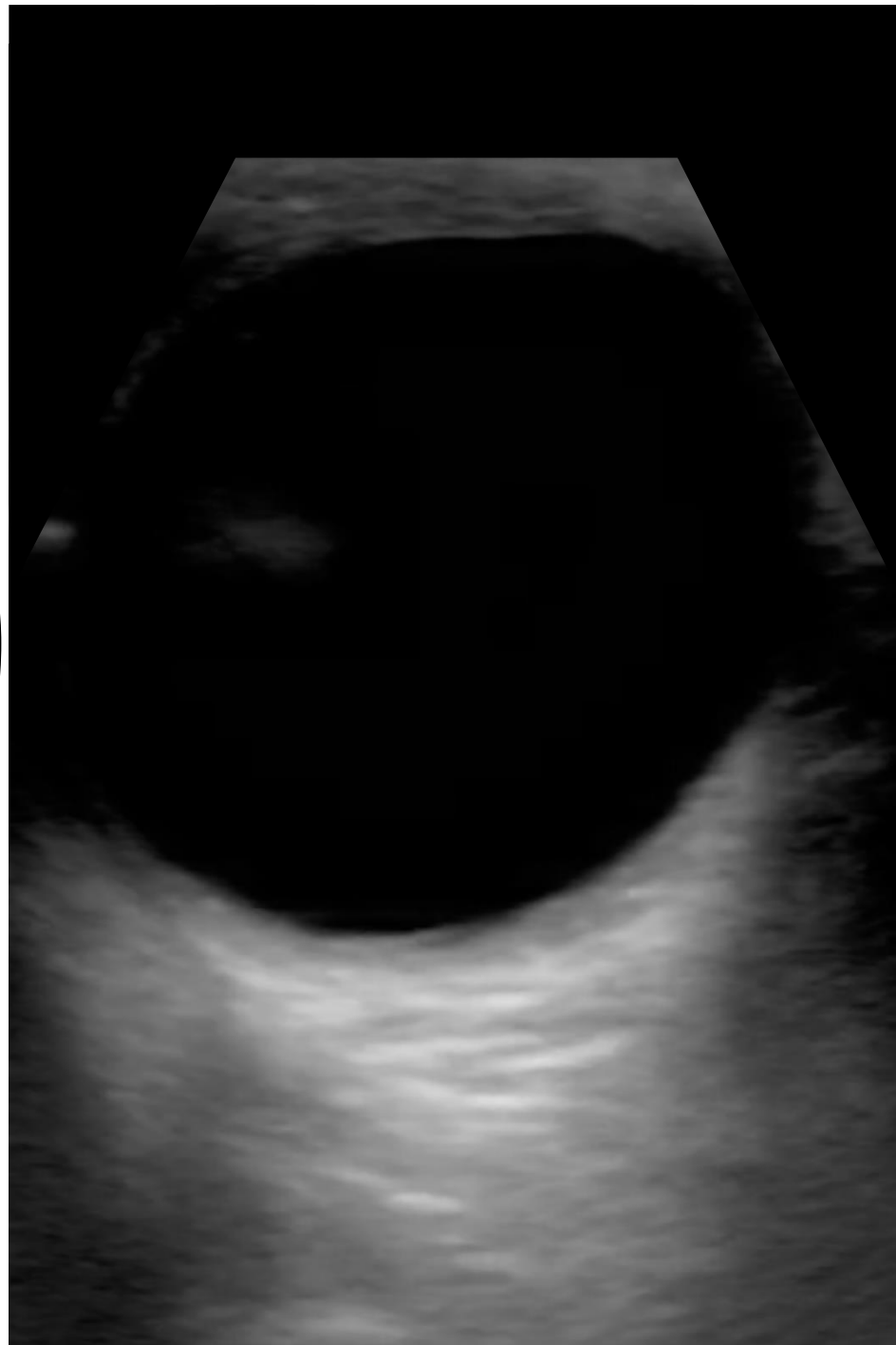
CC: Vitreous Hemorrhage  
51 y/o m, hx DPR, c/o  
heme OD

1C



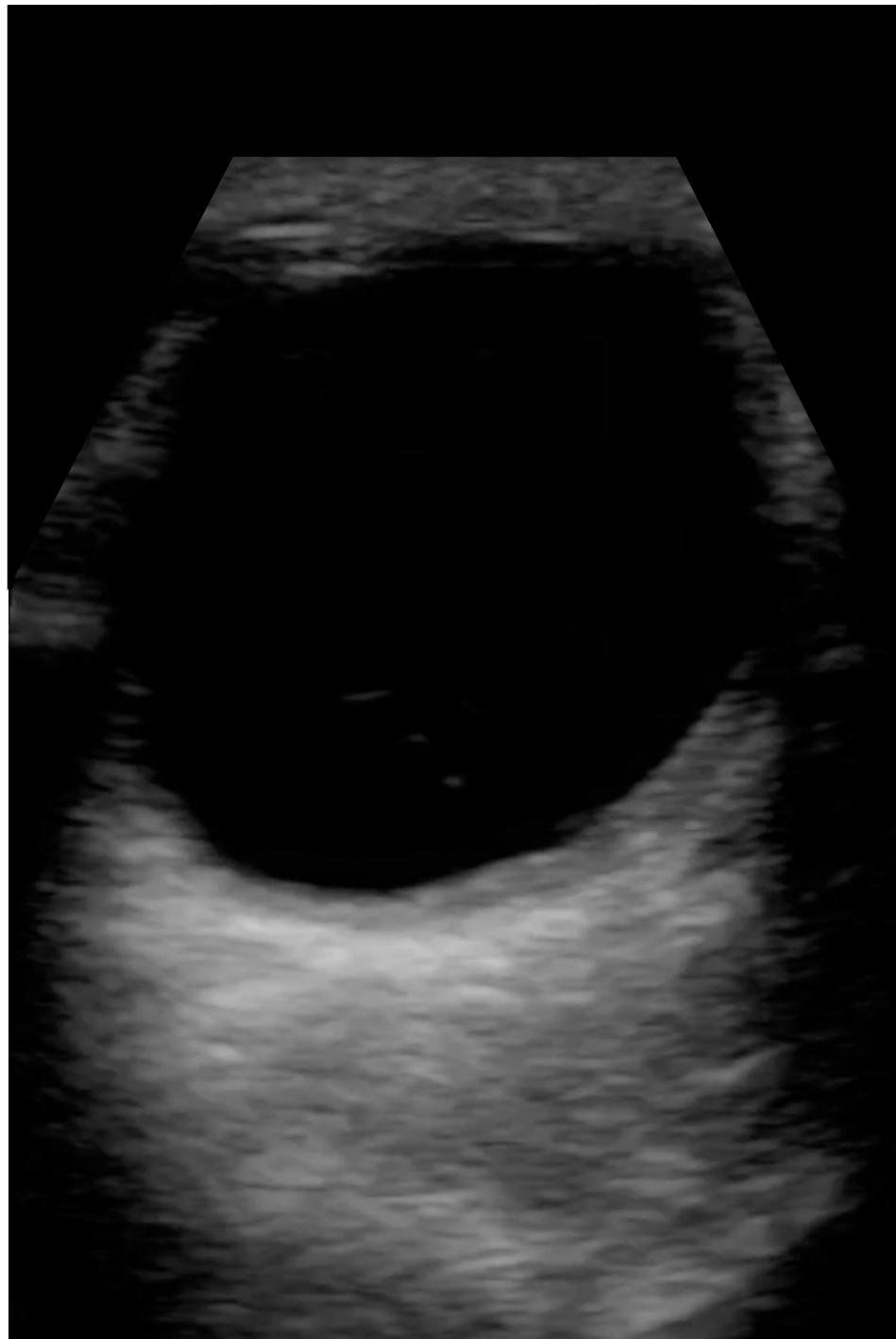CC: Vitreous Hemorrhage  
51 y/o m, hx DPR, c/o  
heme OD

1D



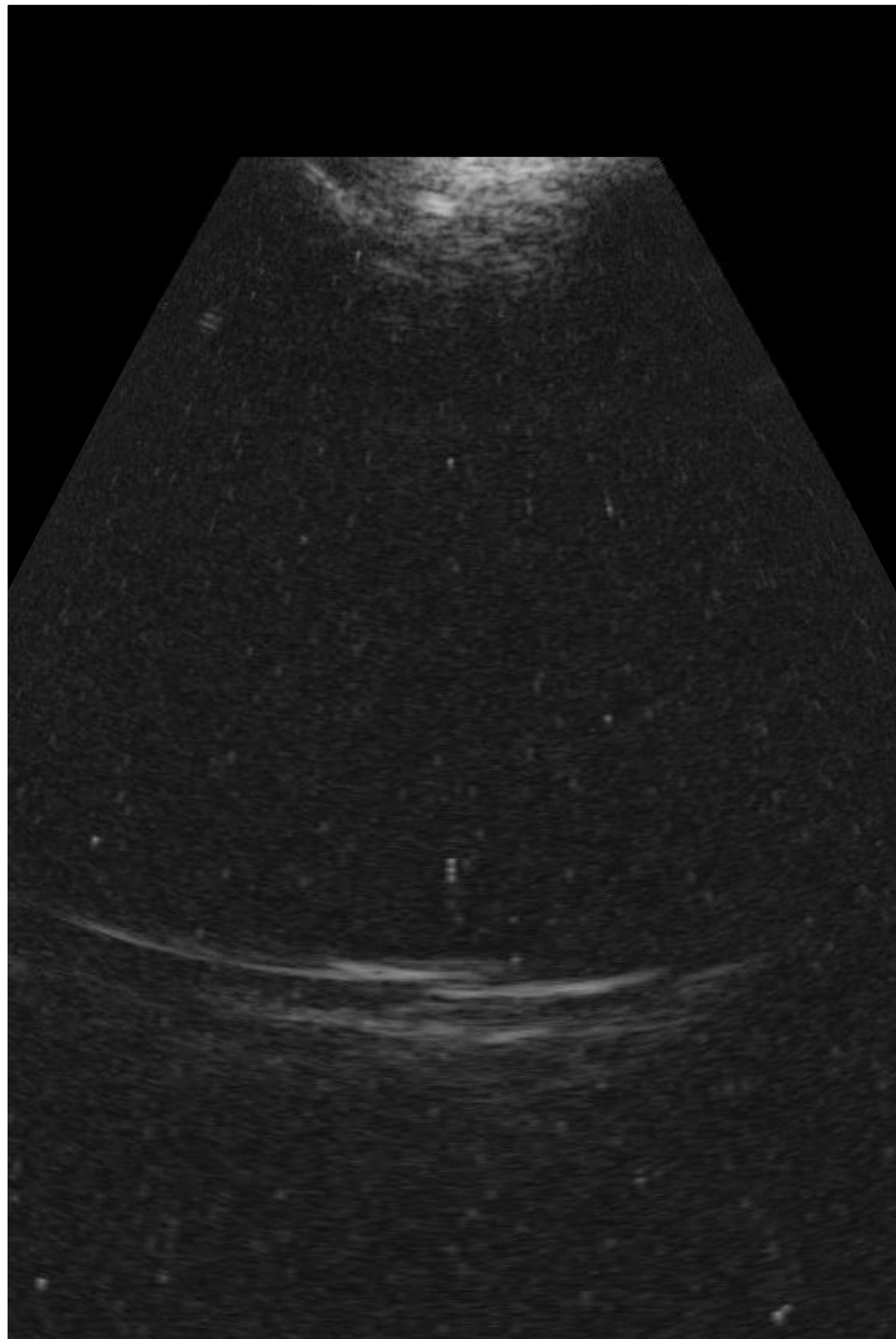
CC: Vitreous Hemorrhage  
51 y/o m, hx DPR, c/o  
heme OD

1E



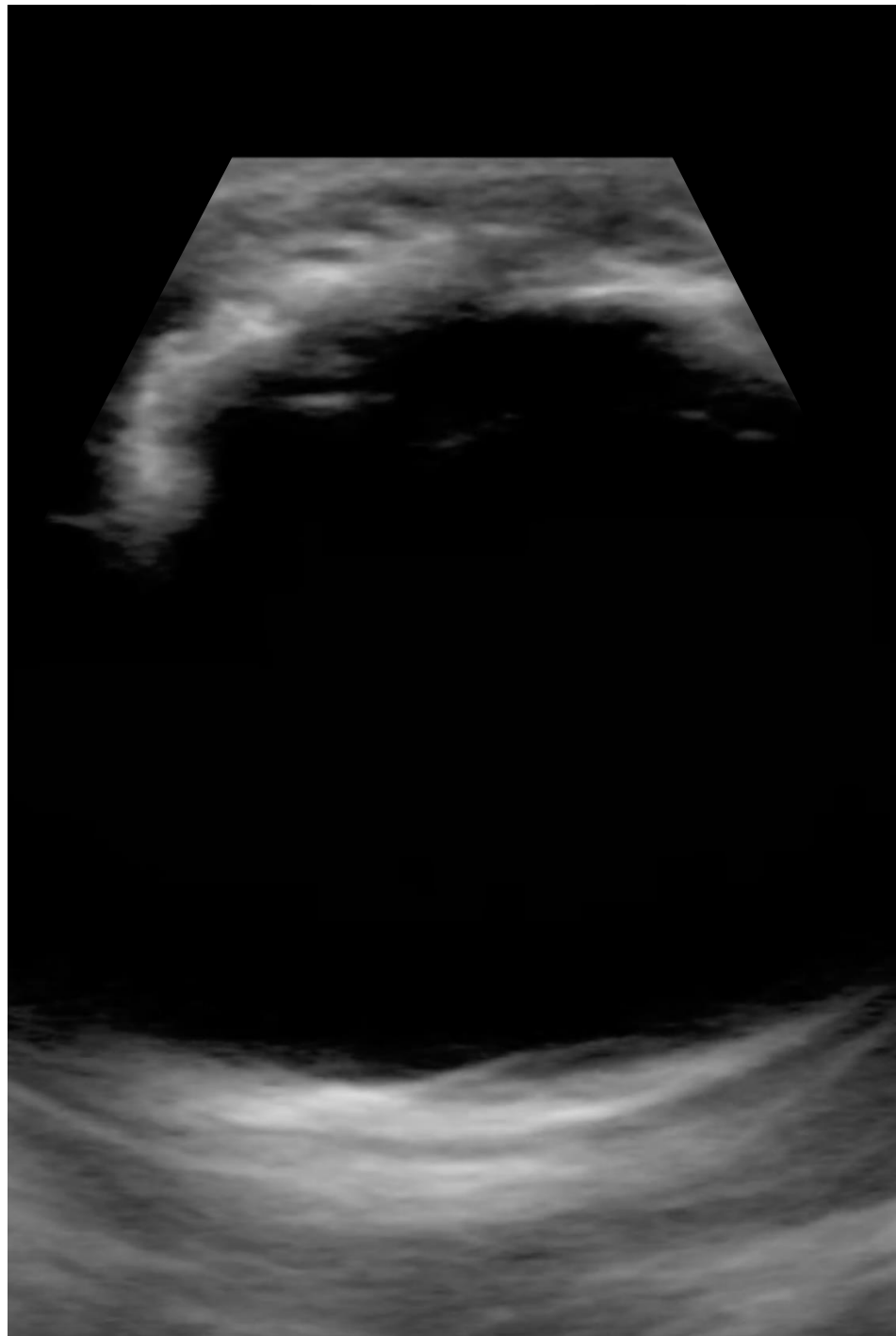
CC: Vitreous Hemorrhage  
51 y/o m, hx DPR, c/o  
heme OD

2A



CC: Silicone Oil F/u  
21 y/o M tractional RD  
OS s/p PPV/SOR/  
phacoemulsification/  
anterior membrane  
dissection/SO

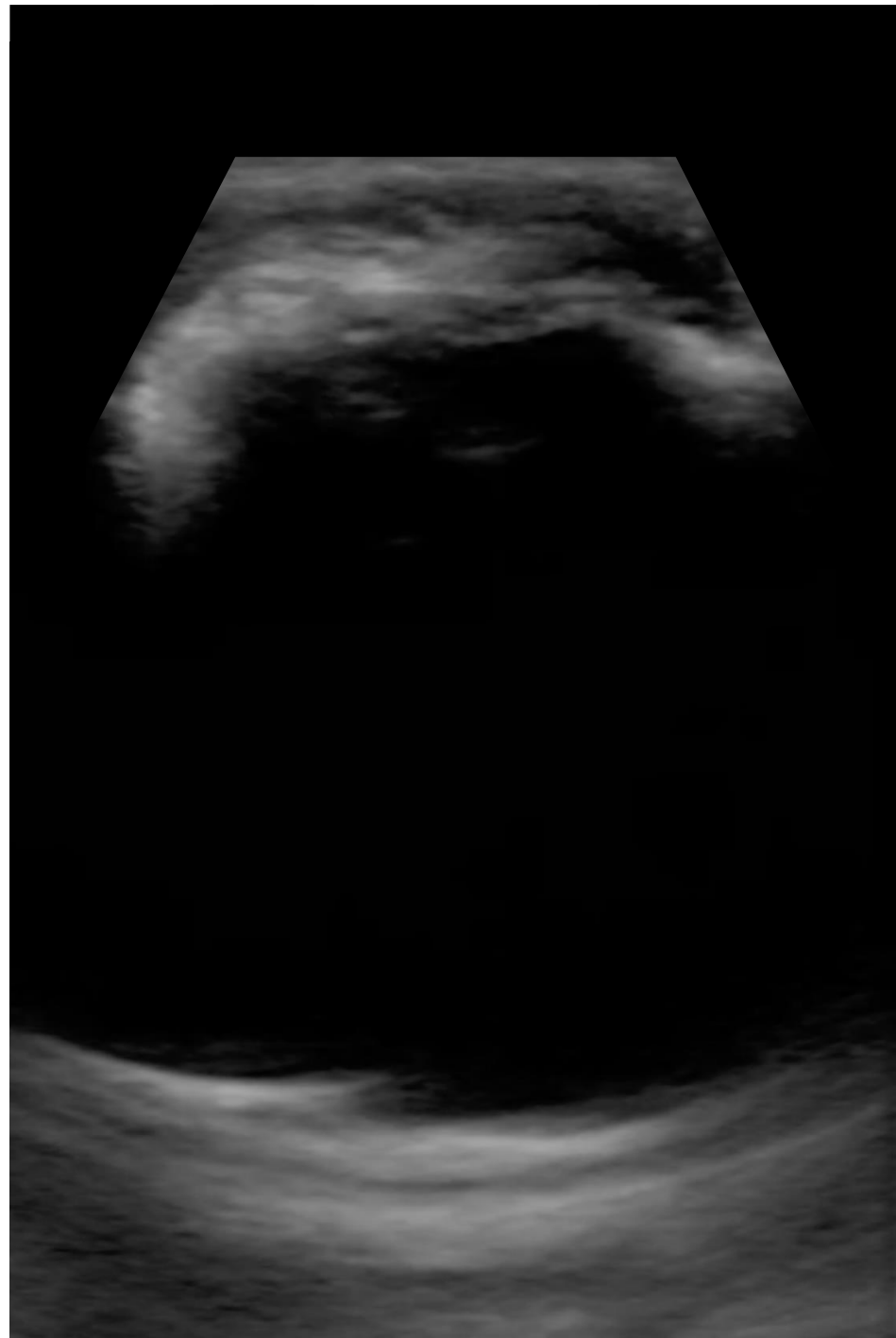
2B



CC: Silicone Oil F/u  
21 y/o M tractional RD  
OS s/p PPV/SOR/  
phacoemulsification/  
anterior membrane  
dissection/SO

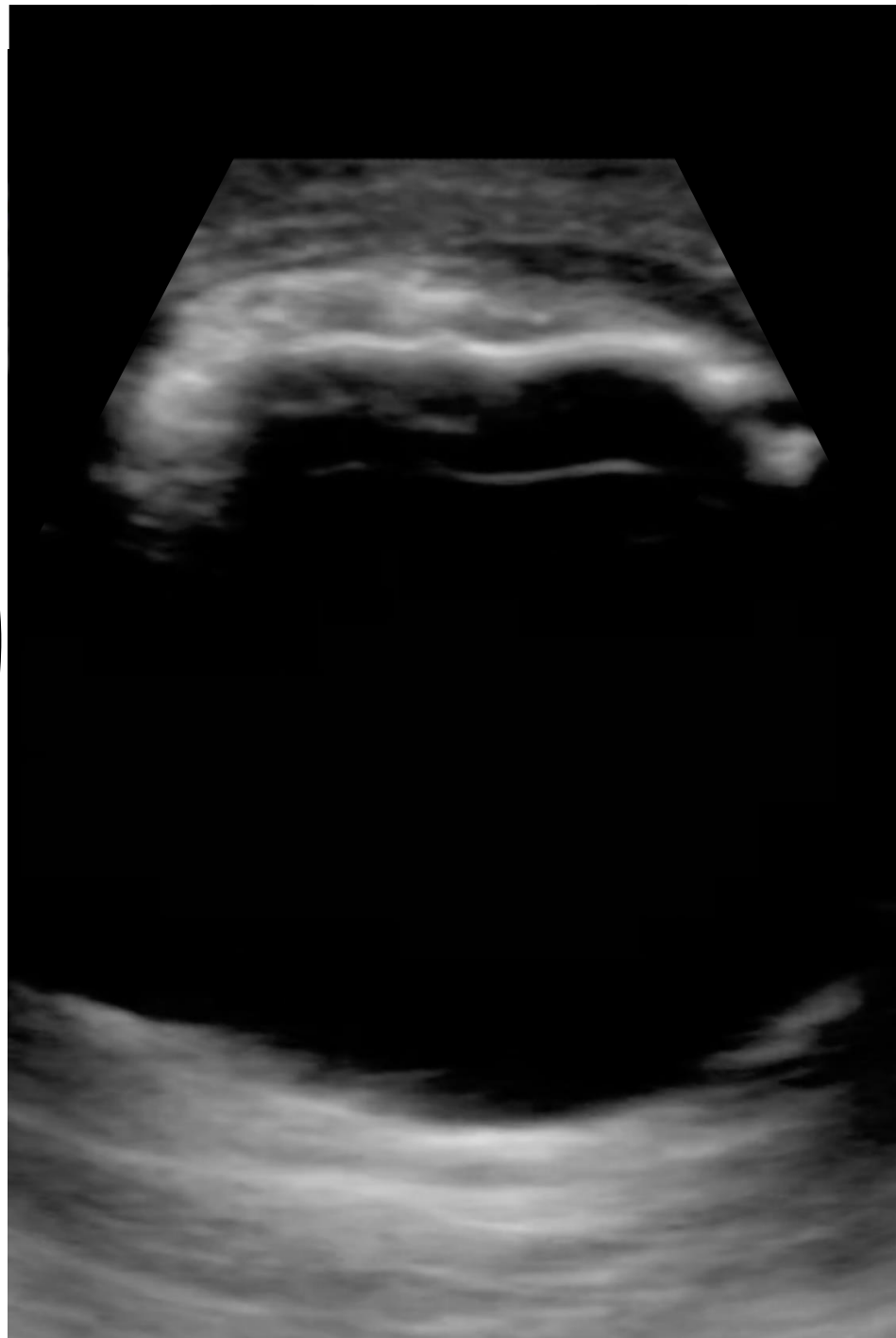


20



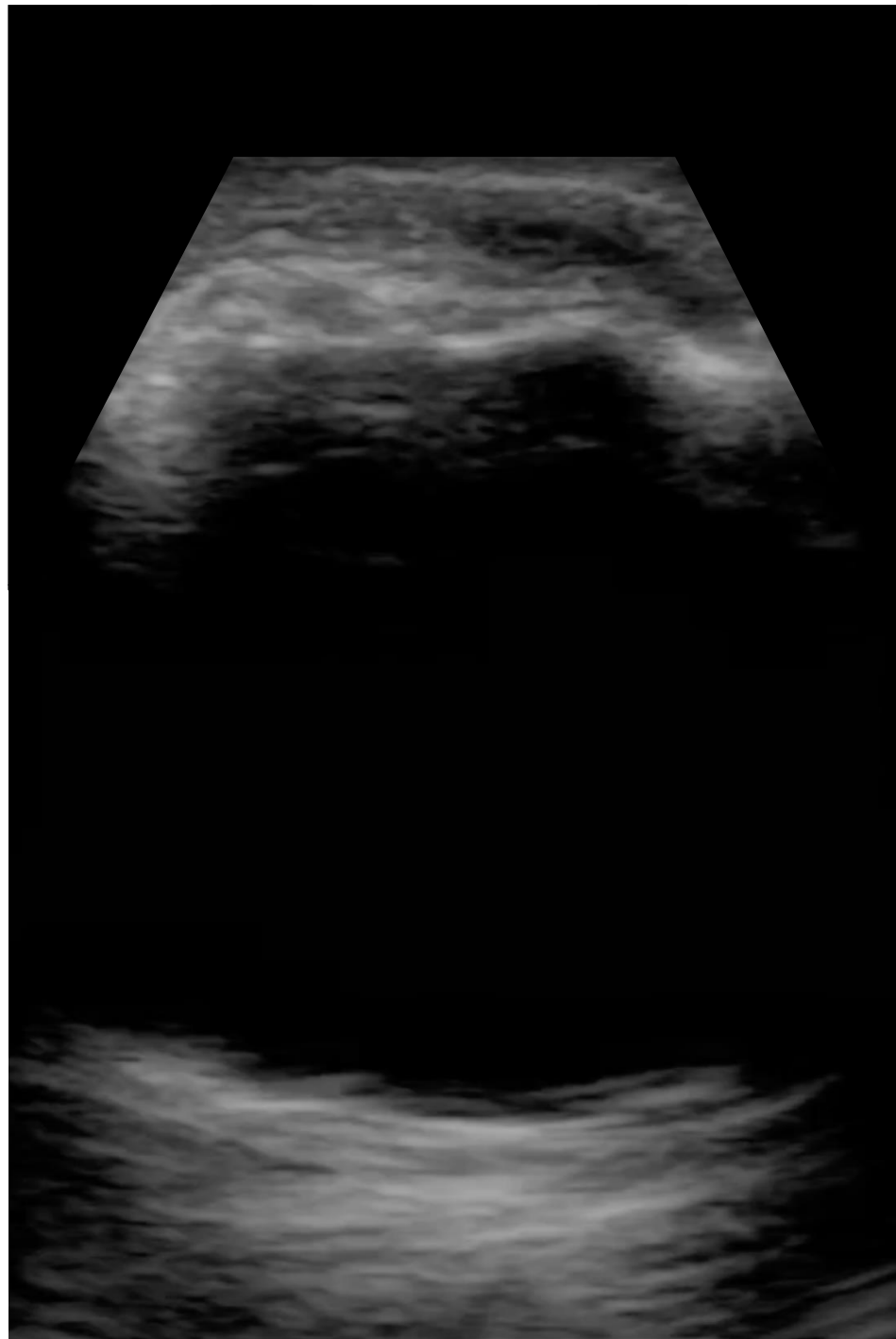
CC: Silicone Oil F/u  
21 y/o M tractional RD  
OS s/p PPV/SOR/  
phacoemulsification/  
anterior membrane  
dissection/SO

# 2D



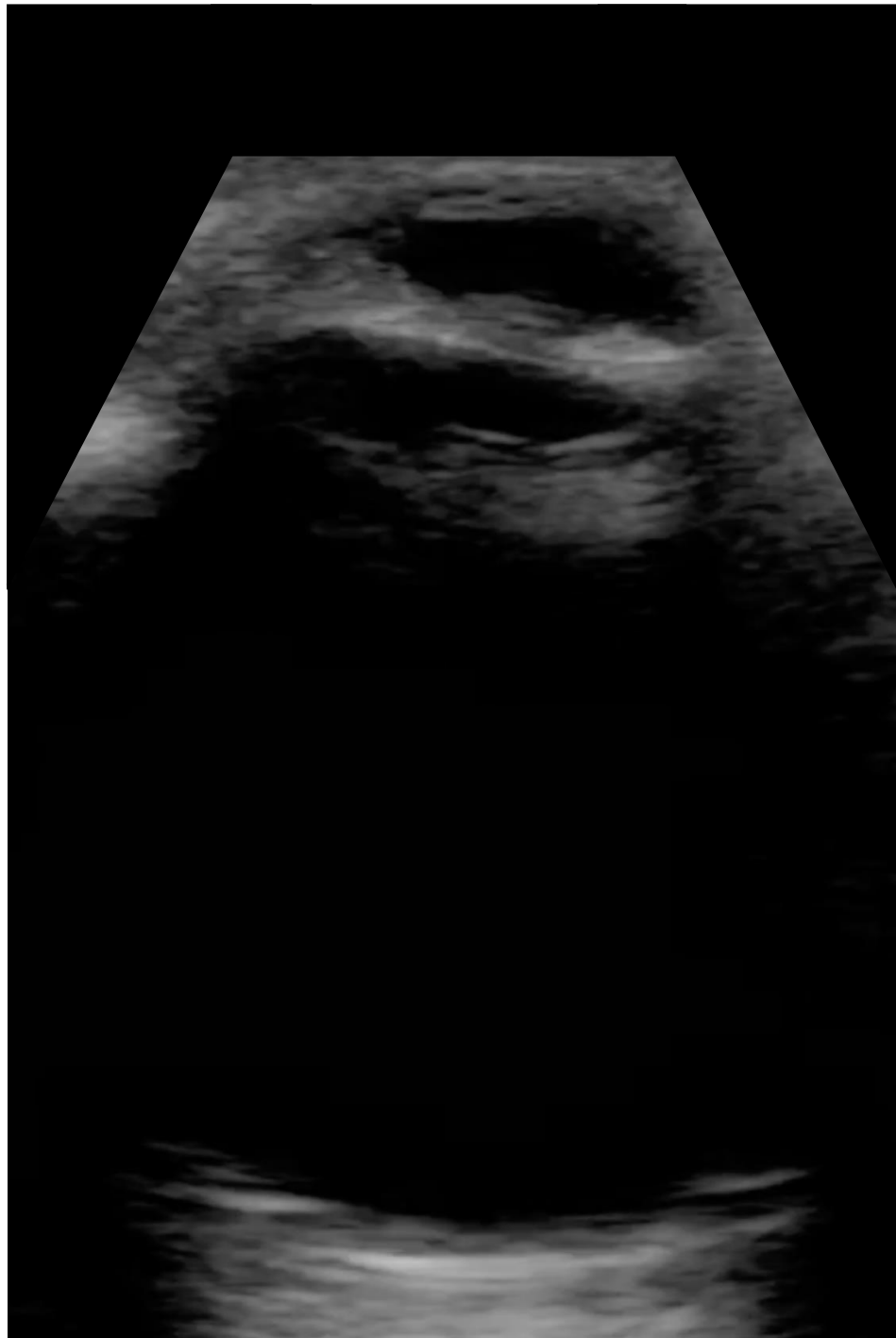CC: Silicone Oil F/u  
21 y/o M tractional RD  
OS s/p PPV/SOR/  
phacoemulsification/  
anterior membrane  
dissection/SO

ZE



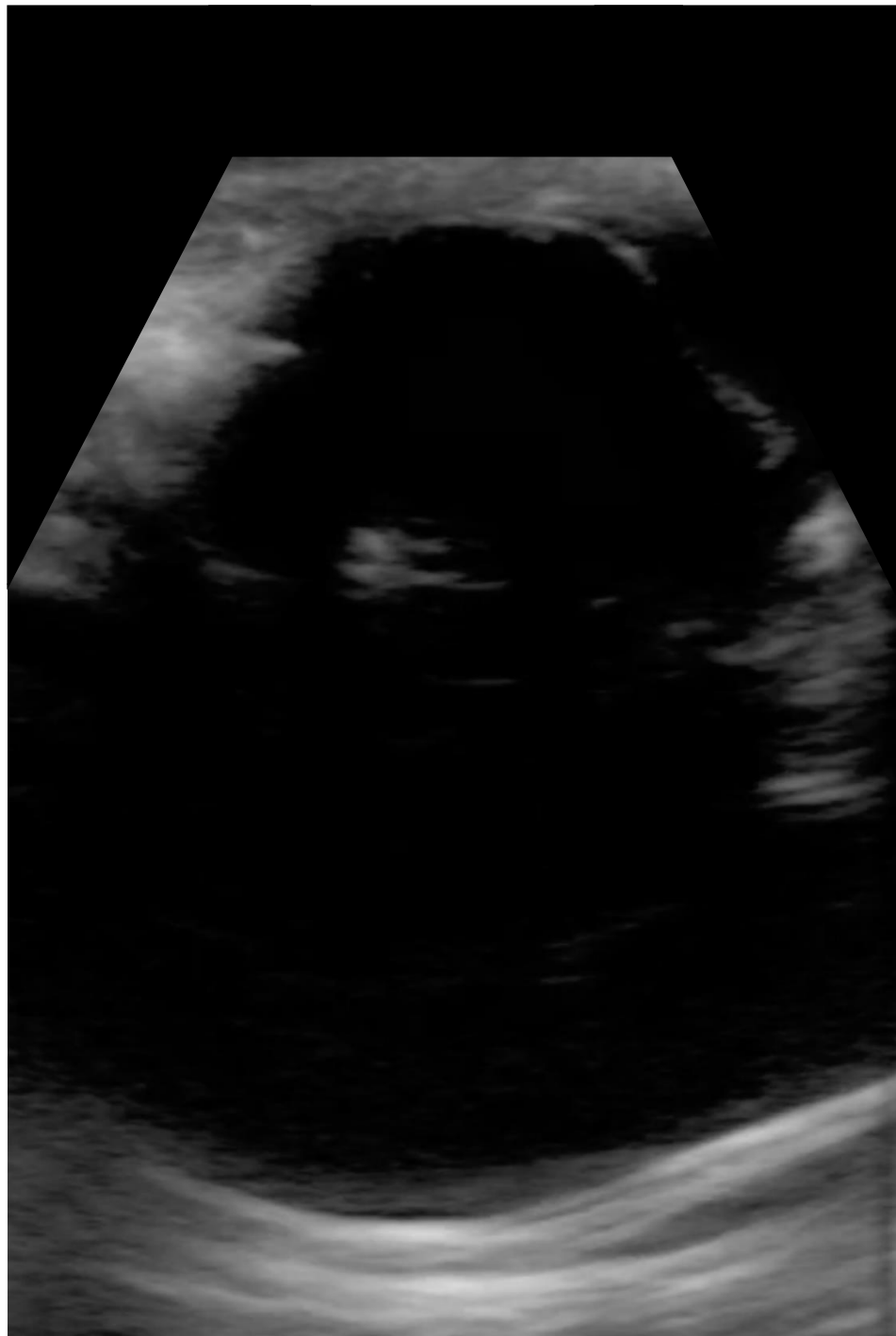
CC: Silicone Oil F/u  
21 y/o M tractional RD  
OS s/p PPV/SOR/  
phacoemulsification/  
anterior membrane  
dissection/SO

3A



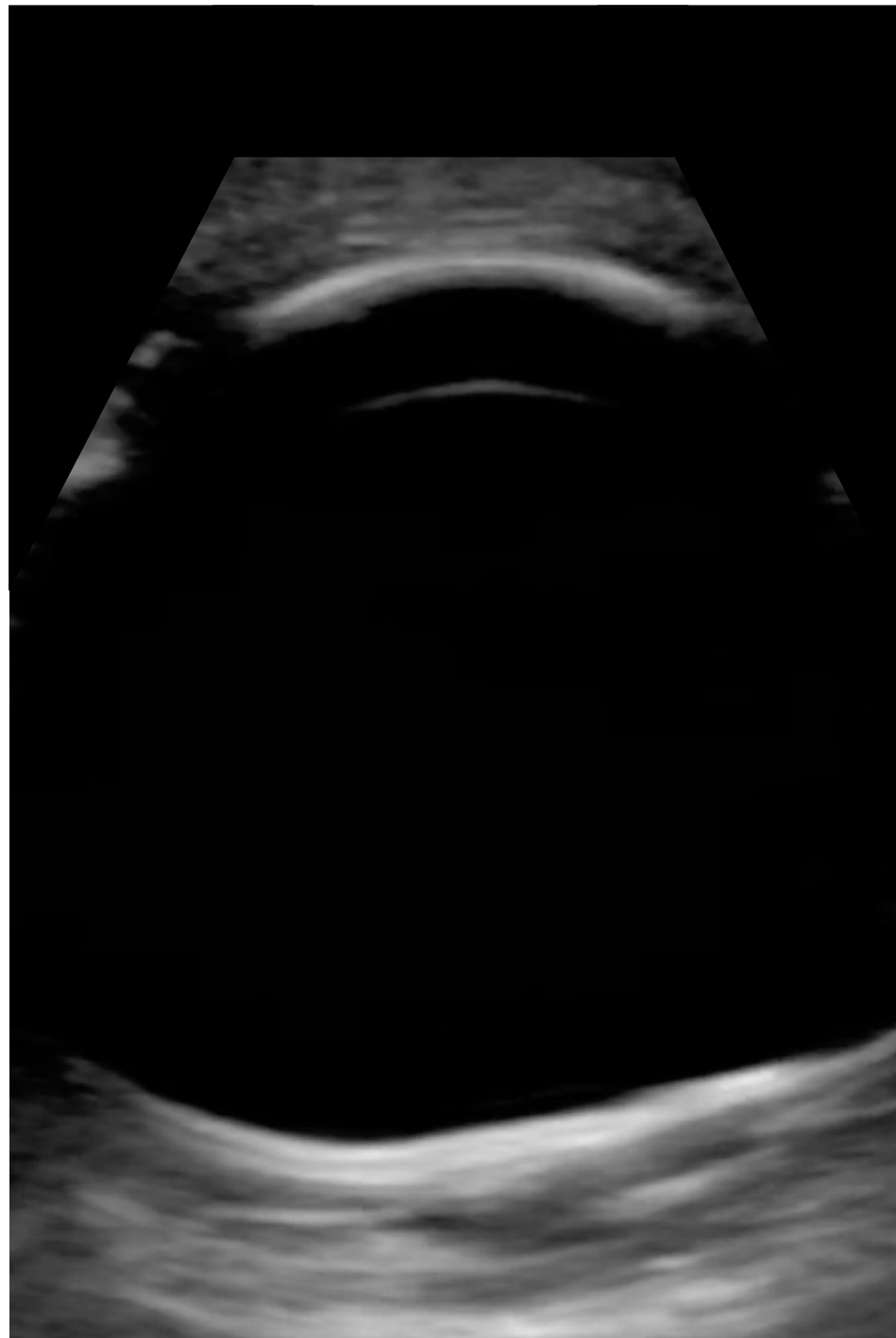
CC: Silicone Oil F/u  
26 y/o M RD OS  
s/p CE/PPV/MP/  
retinectomy/SO

3B



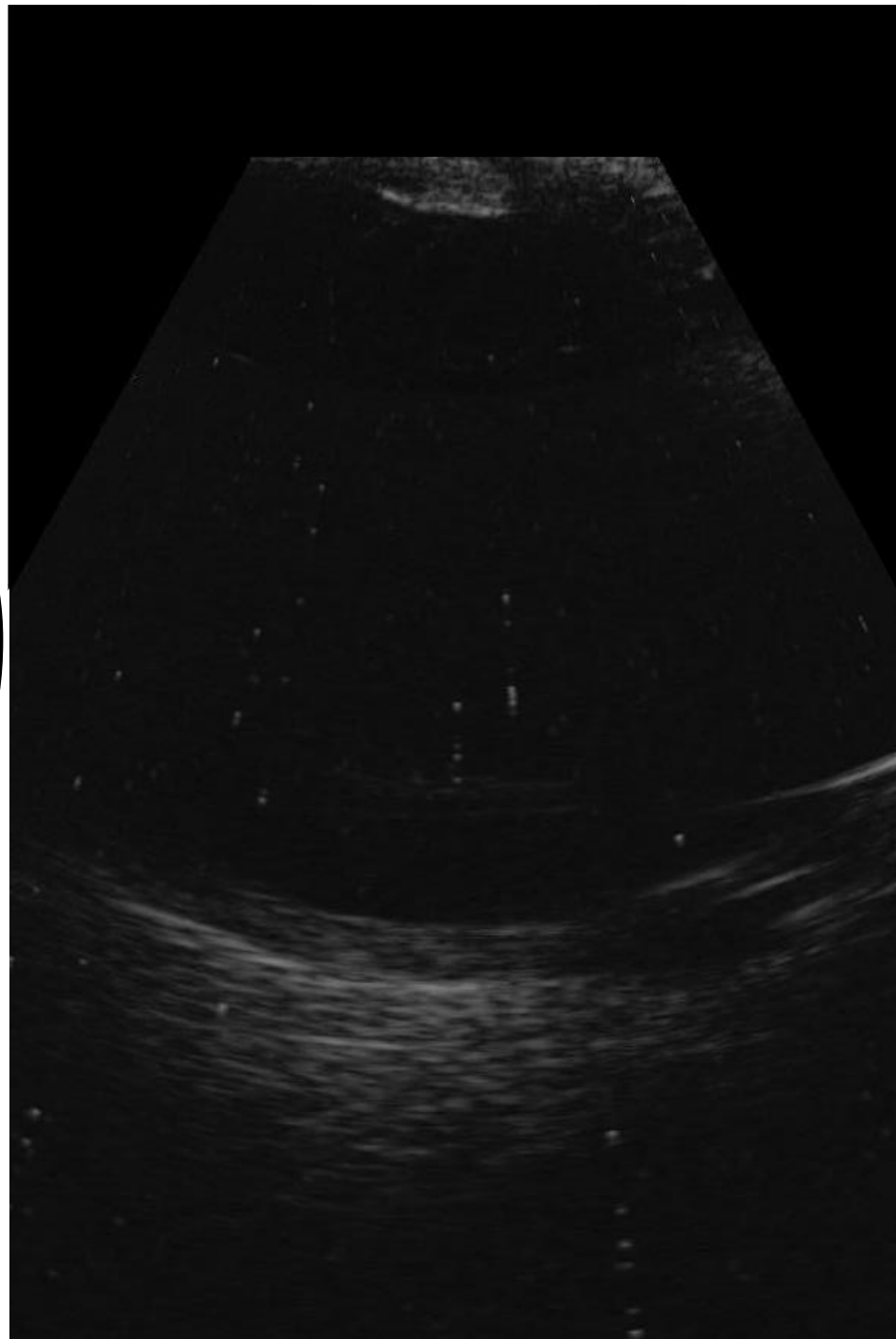
CC: Silicone Oil F/u  
26 y/o M RD OS  
s/p CE/PPV/MP/  
retinectomy/SO

3C



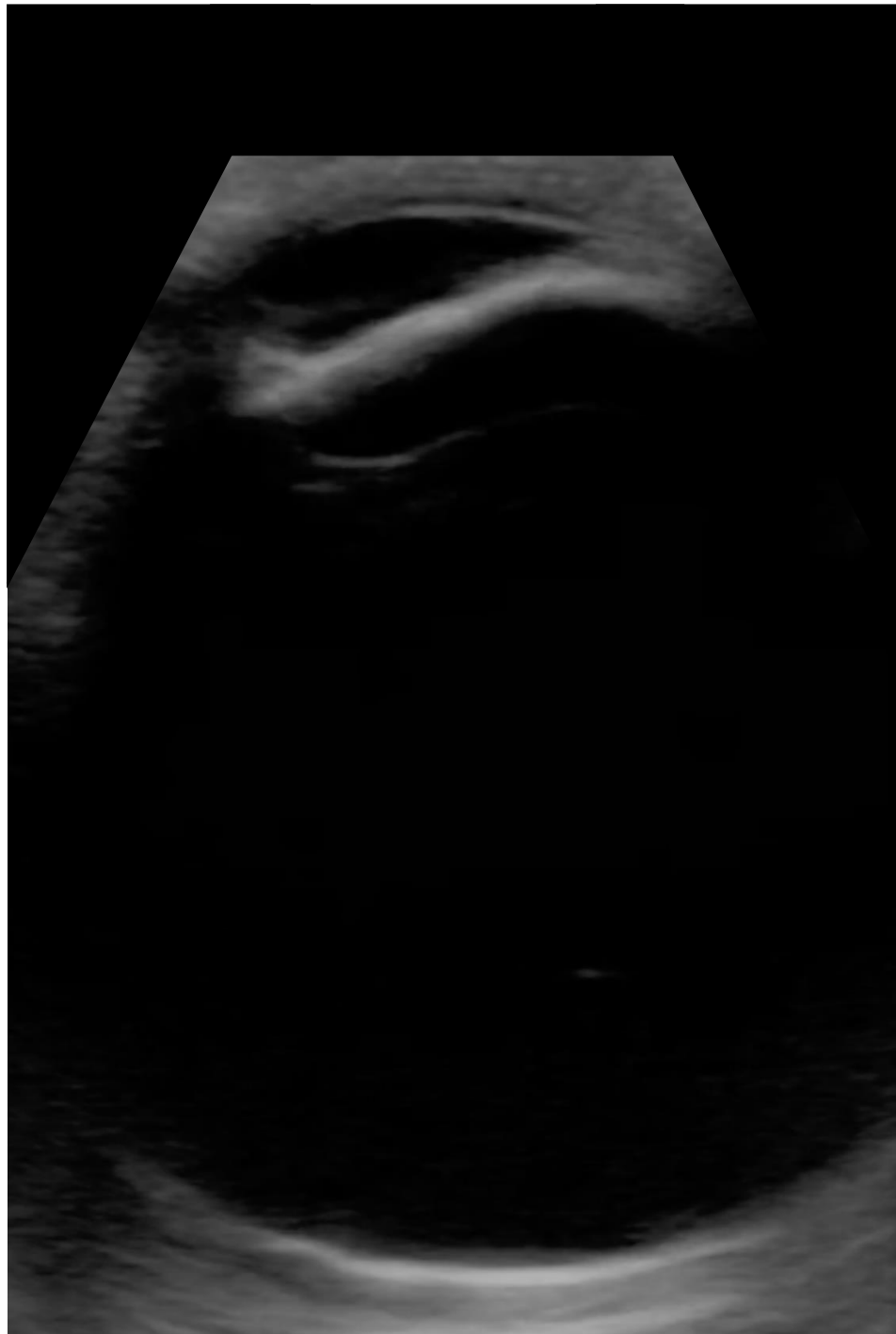CC: Silicone Oil F/u  
26 y/o M RD OS  
s/p CE/PPV/MP/  
retinectomy/SO

# 3D



CC: Silicone Oil F/u  
26 y/o M RD OS  
s/p CE/PPV/MP/  
retinectomy/SO

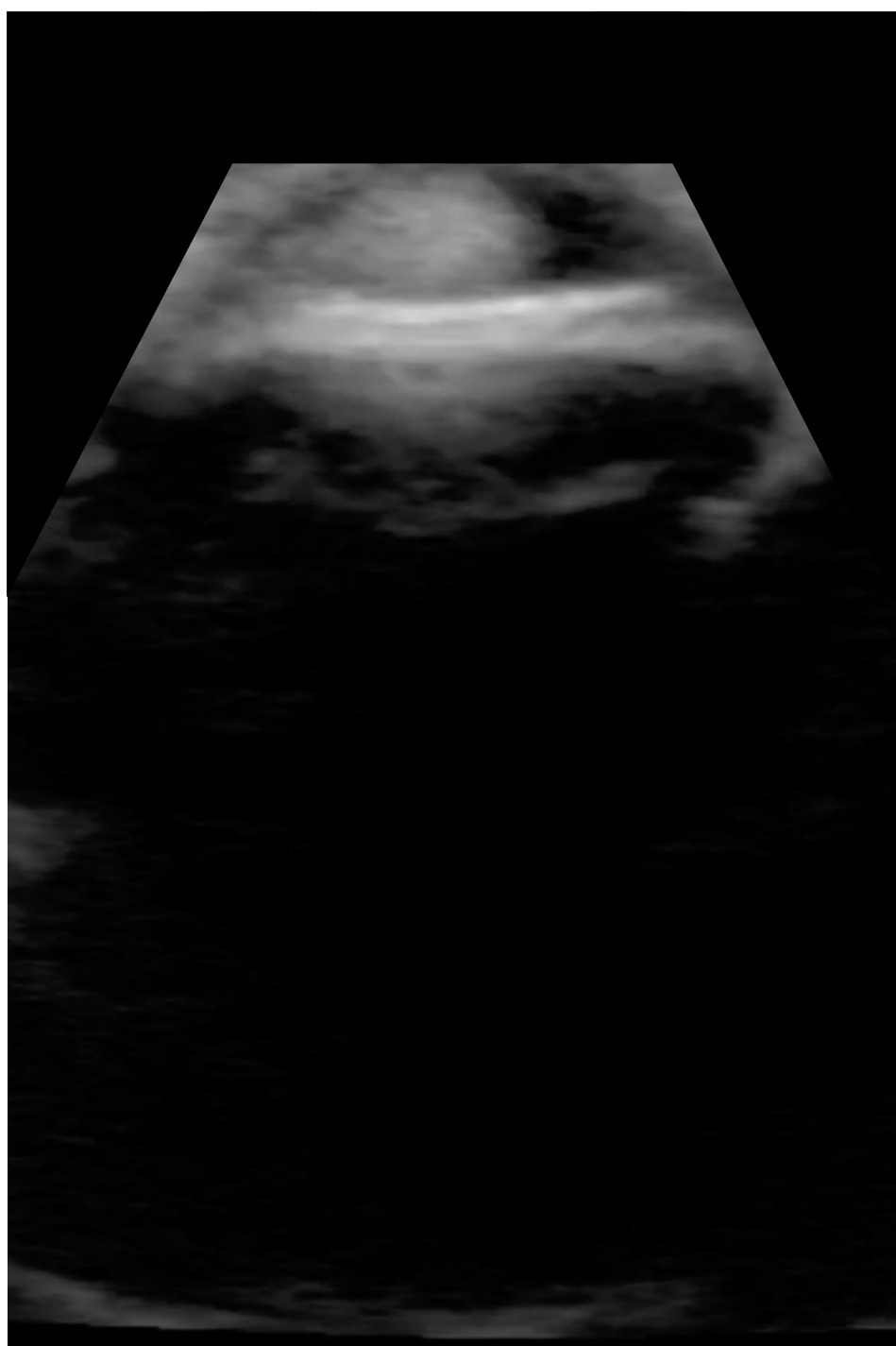
3E



CC: Silicone Oil F/u  
26 y/o M RD OS  
s/p CE/PPV/MP/  
retinectomy/SO

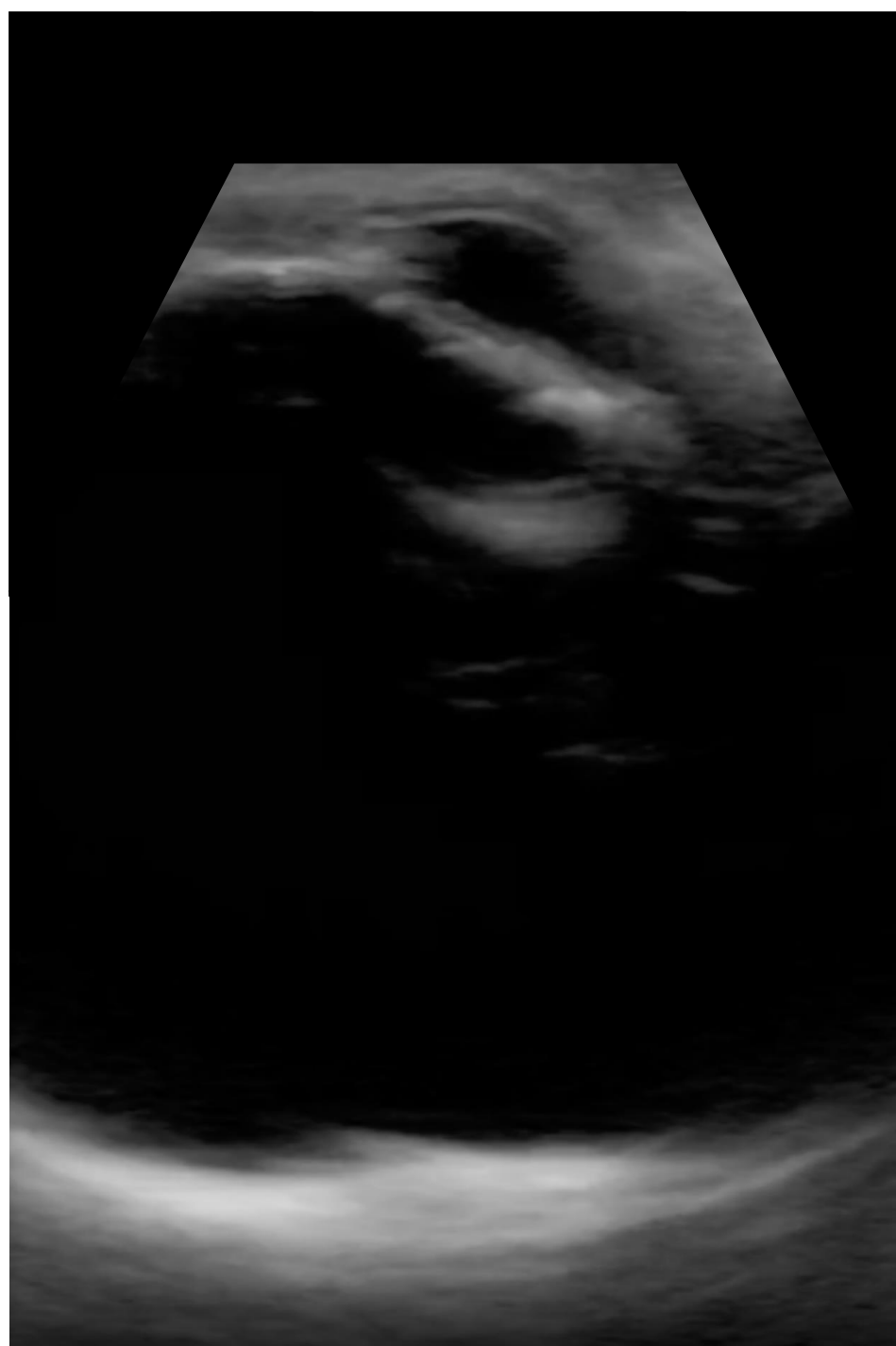

4A



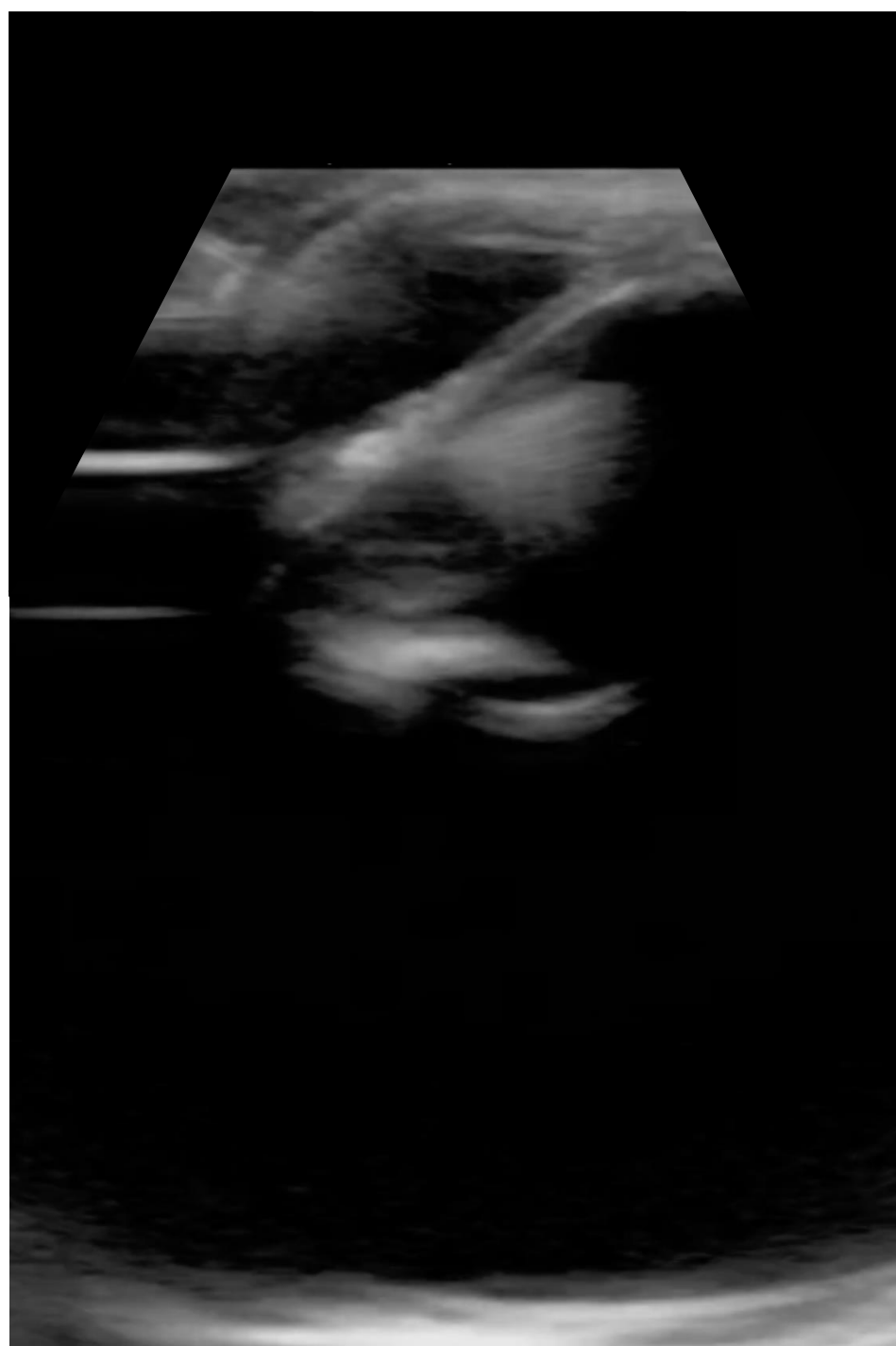CC: Silicone Oil F/u  
66 y/o M RD OD s/p  
PPV/SOI

4B



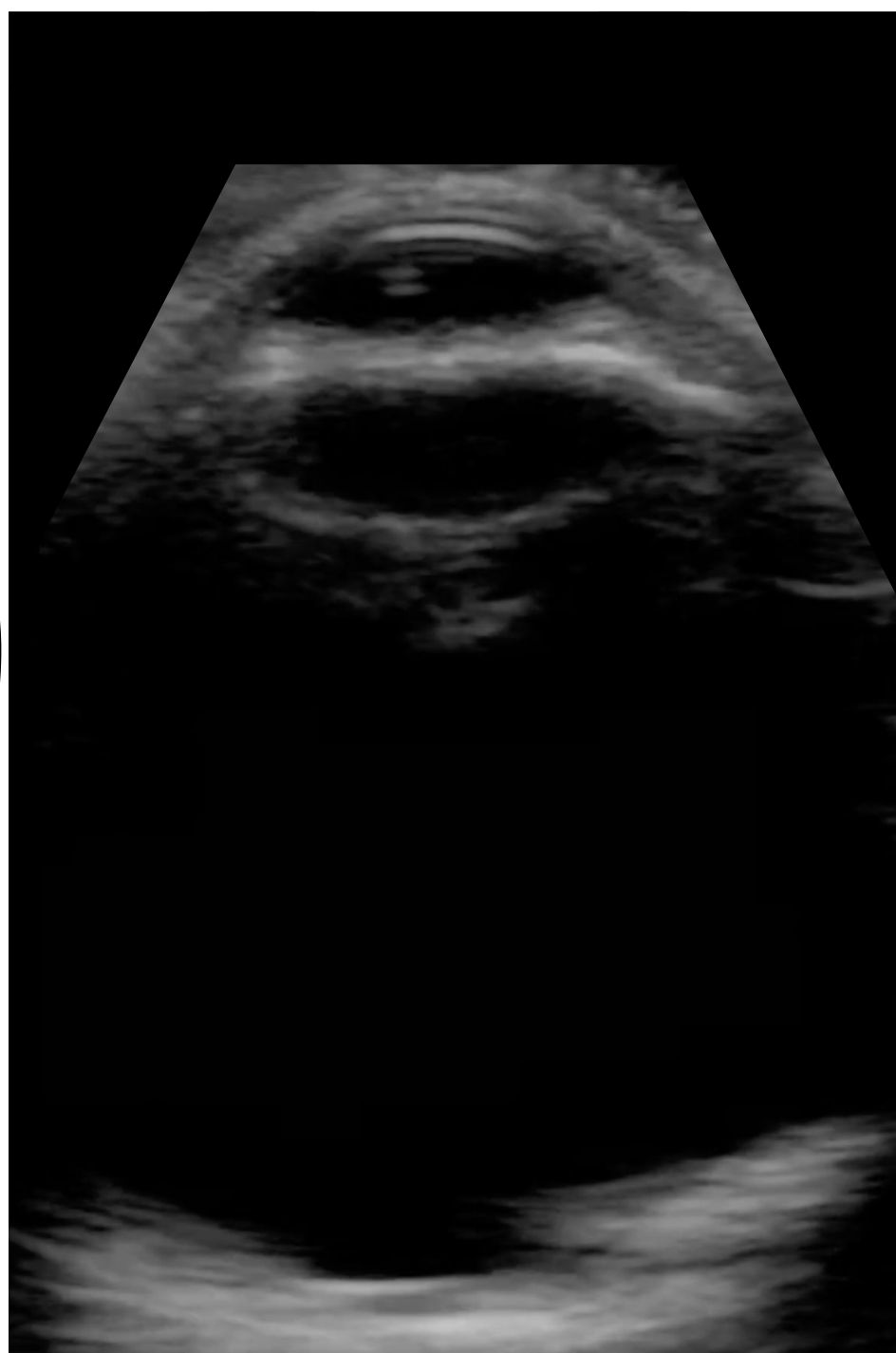CC: Silicone Oil F/u  
66 y/o M RD OD s/p  
PPV/SOI

# 4C



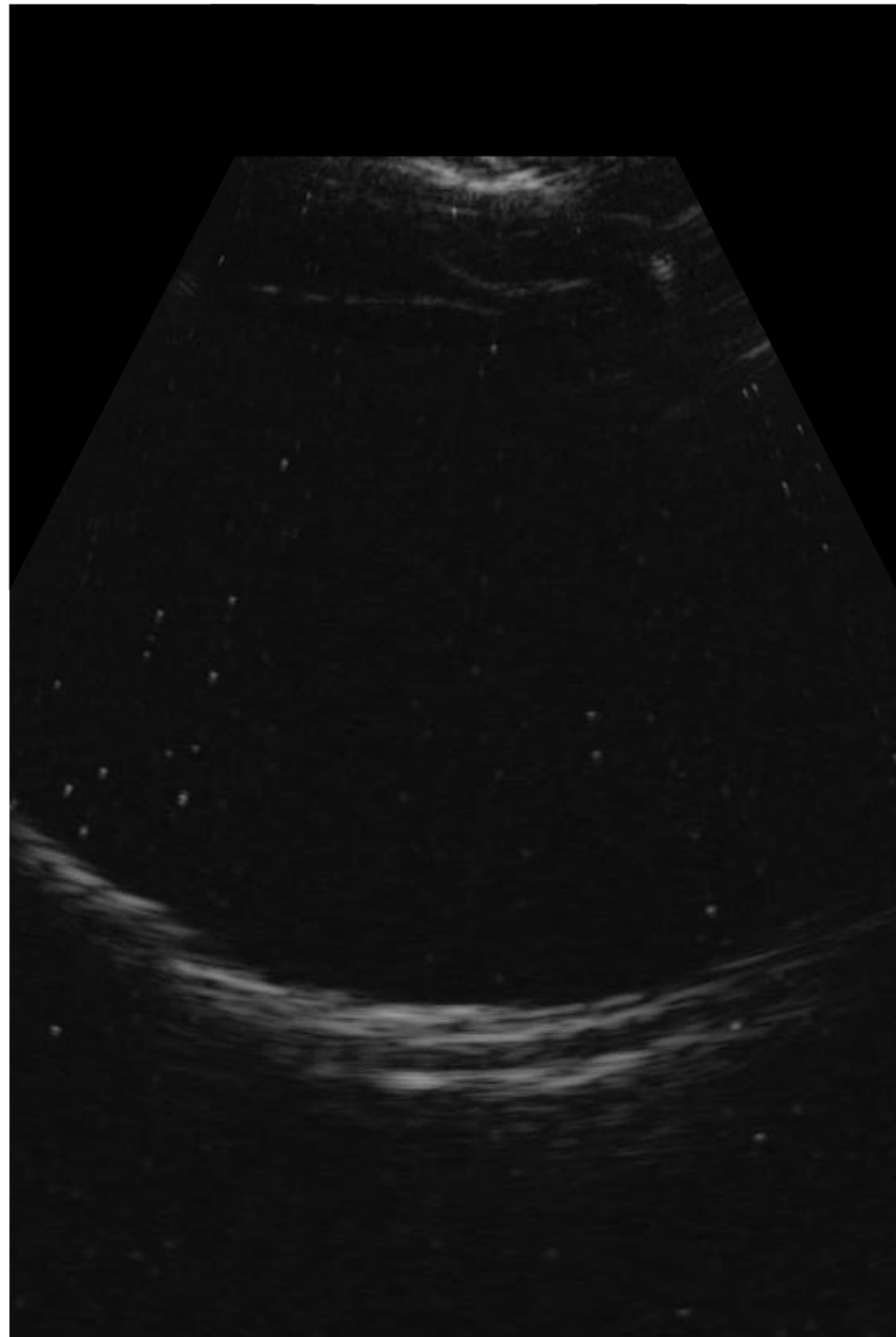
CC: Silicone Oil F/u  
66 y/o M RD OD s/p  
PPV/SOI

# 4D



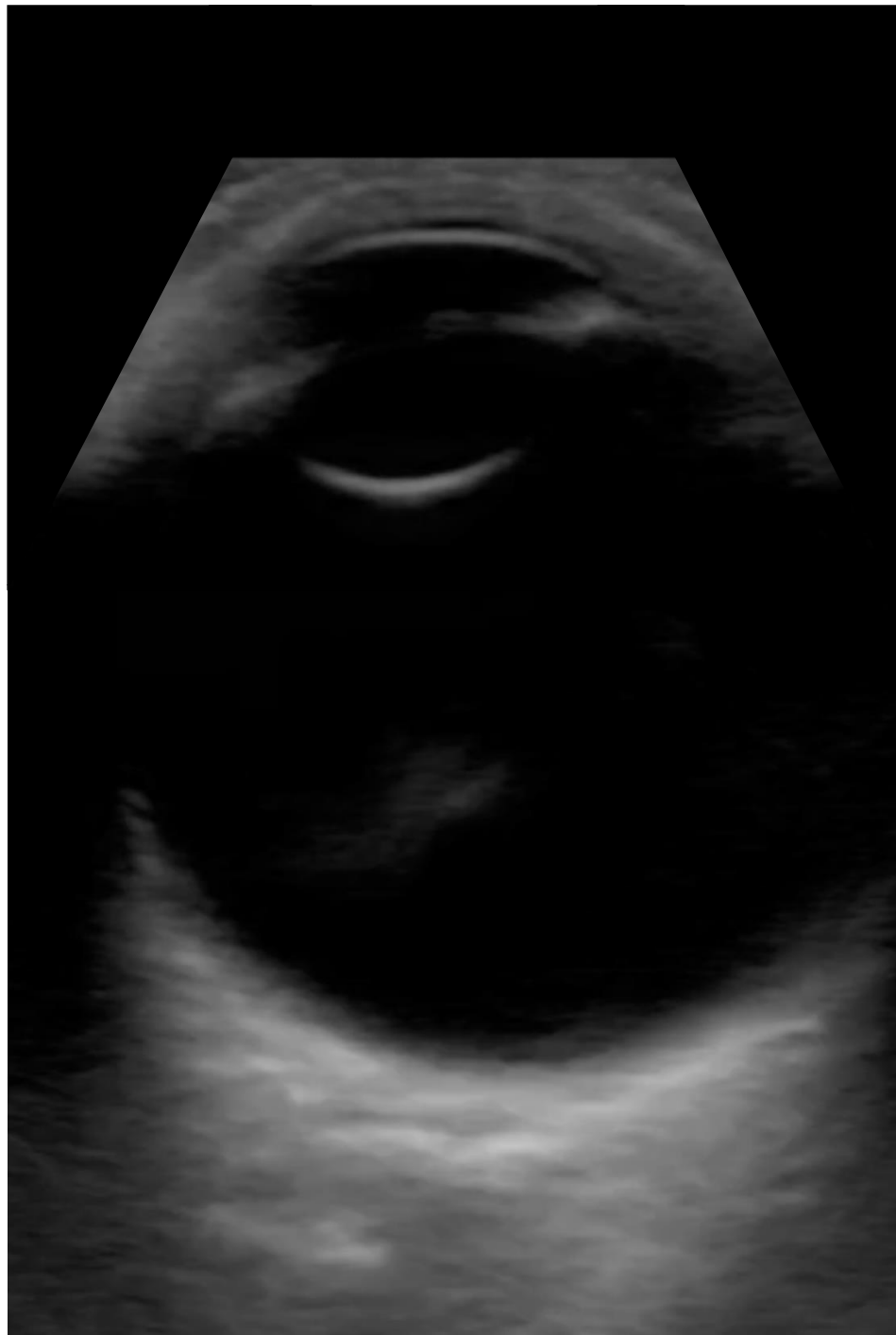
CC: Silicone Oil F/u  
66 y/o M RD OD s/p  
PPV/SOI

4E



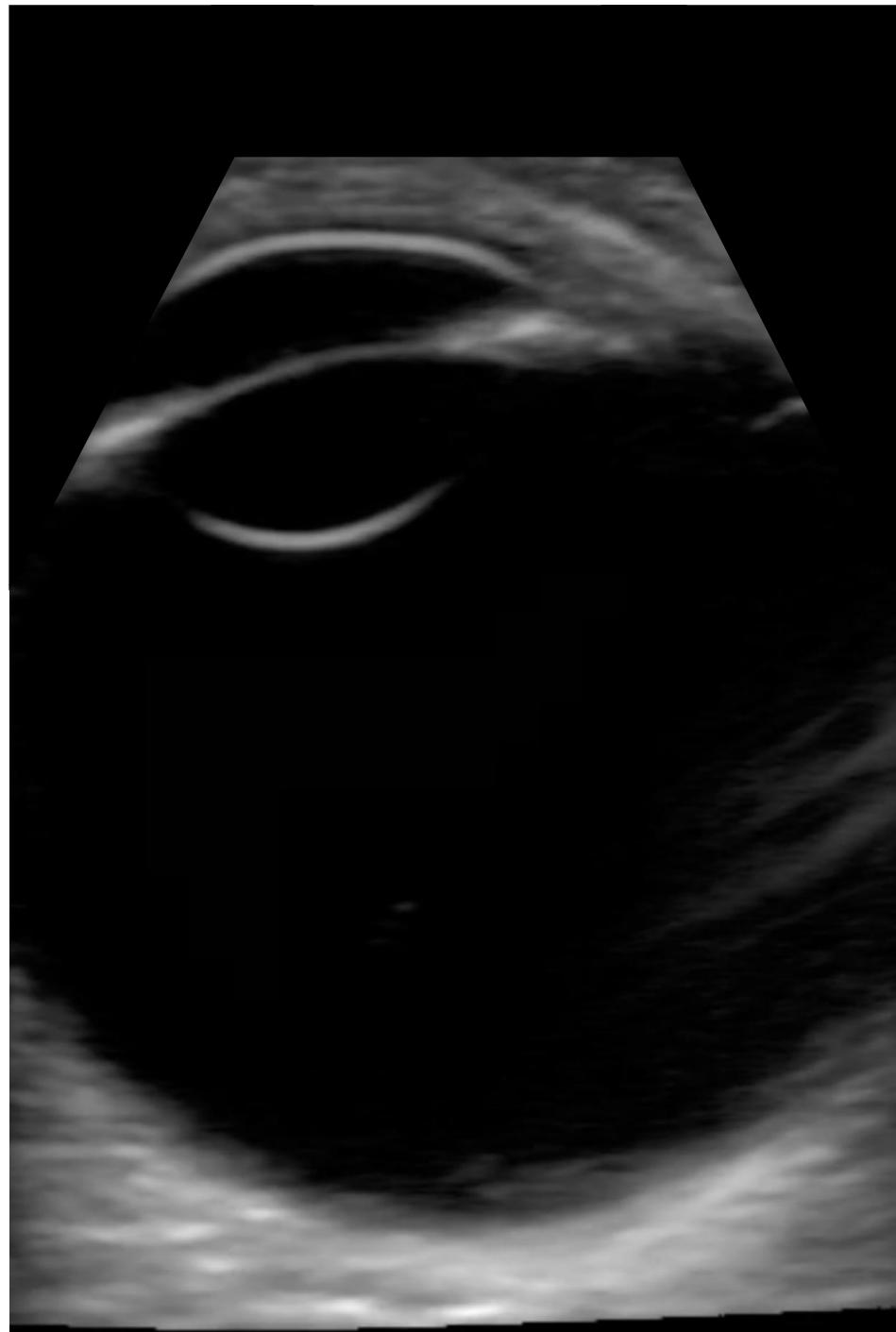
CC: Silicone Oil F/u  
66 y/o M RD OD s/p  
PPV/SOI

5A



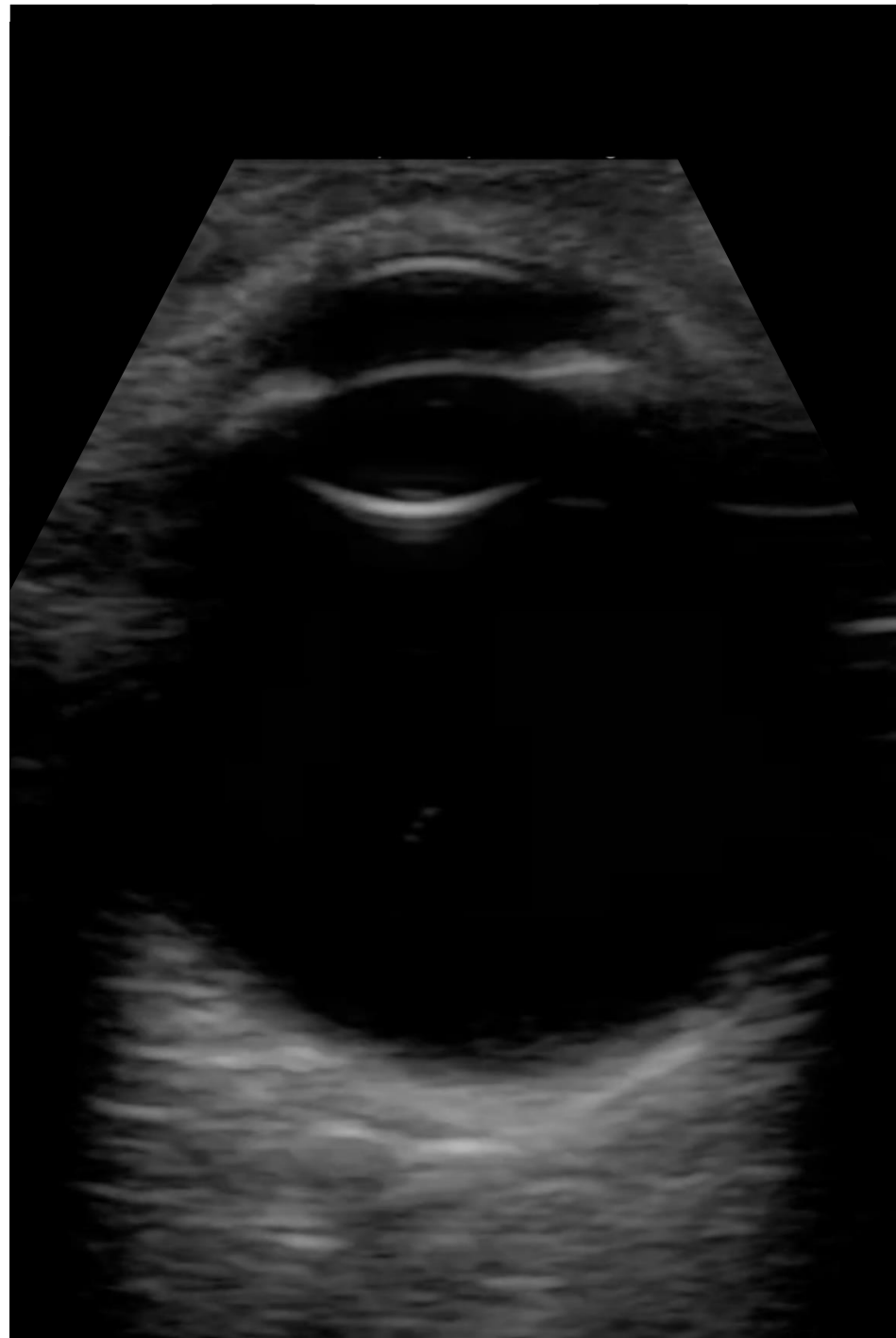
CC: CME F/u + Floaters  
71y/o M w/ cystoid  
macular degeneration  
OD, floater w/ PPV/AFX

5B



CC: CME F/u + Floaters  
71y/o M w/ cystoid  
macular degeneration  
OD, floater w/ PPV/AFX

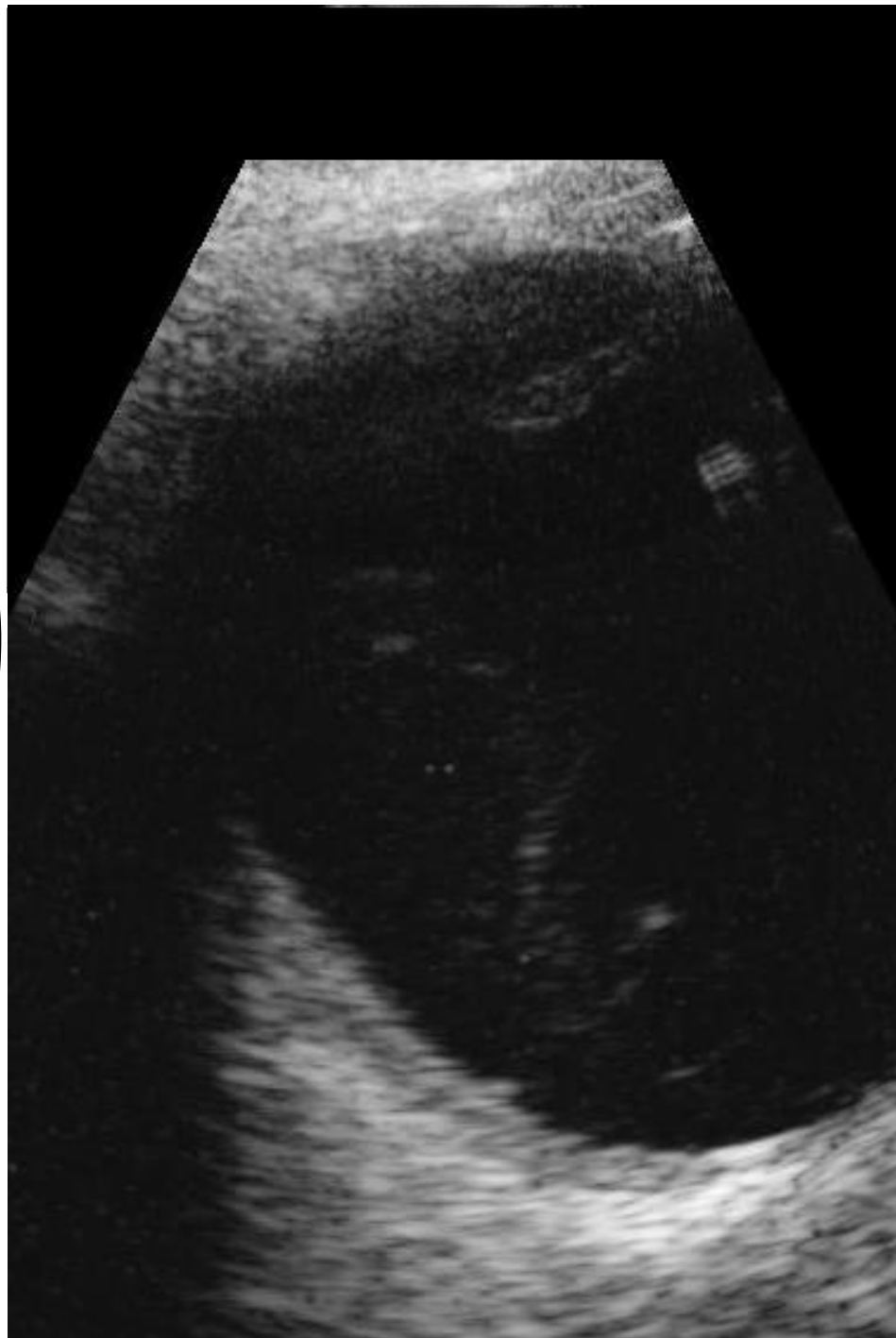# 5C



CC: CME F/u + Floaters  
71y/o M w/ cystoid  
macular degeneration  
OD, floater w/ PPV/AFX

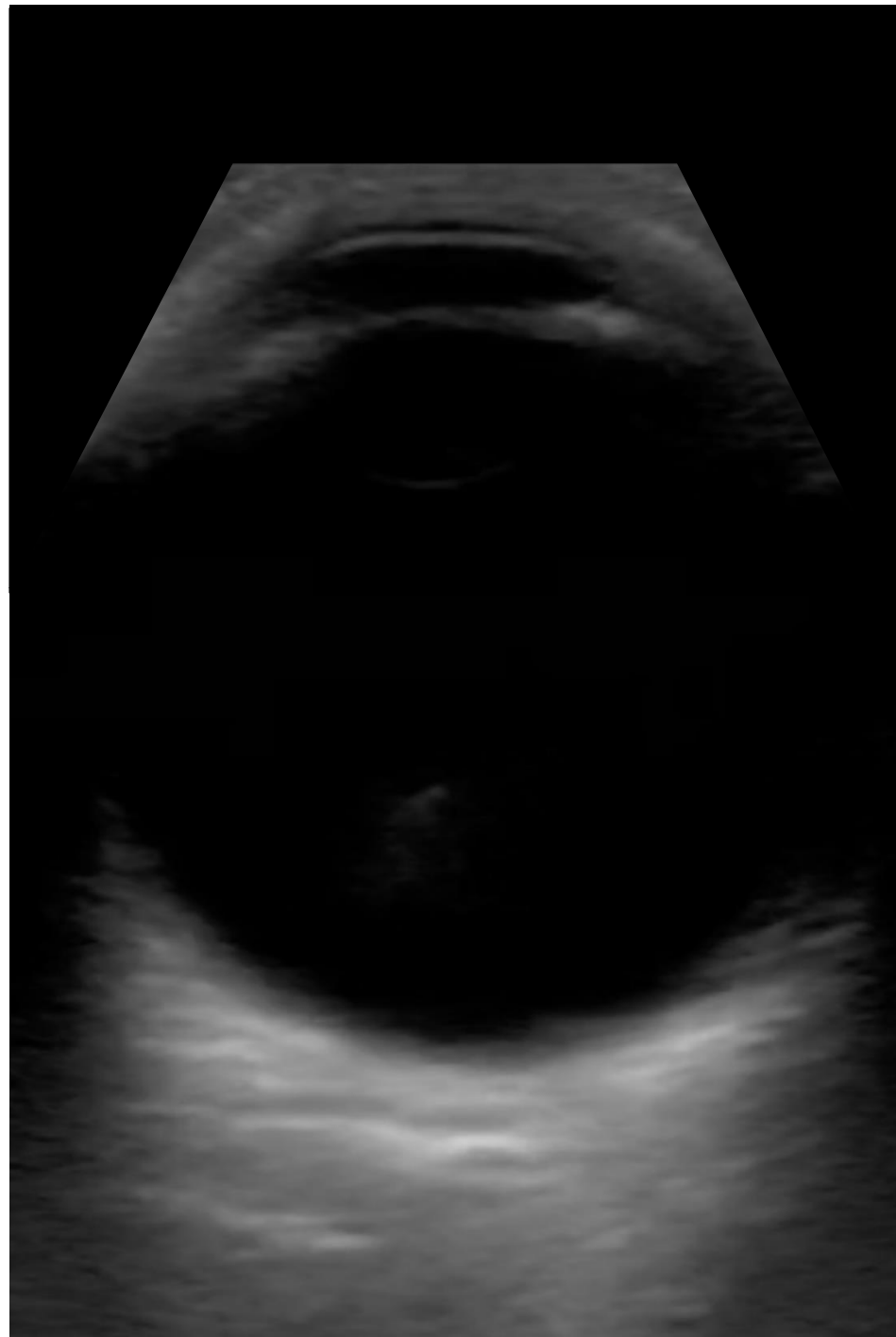

# 5D



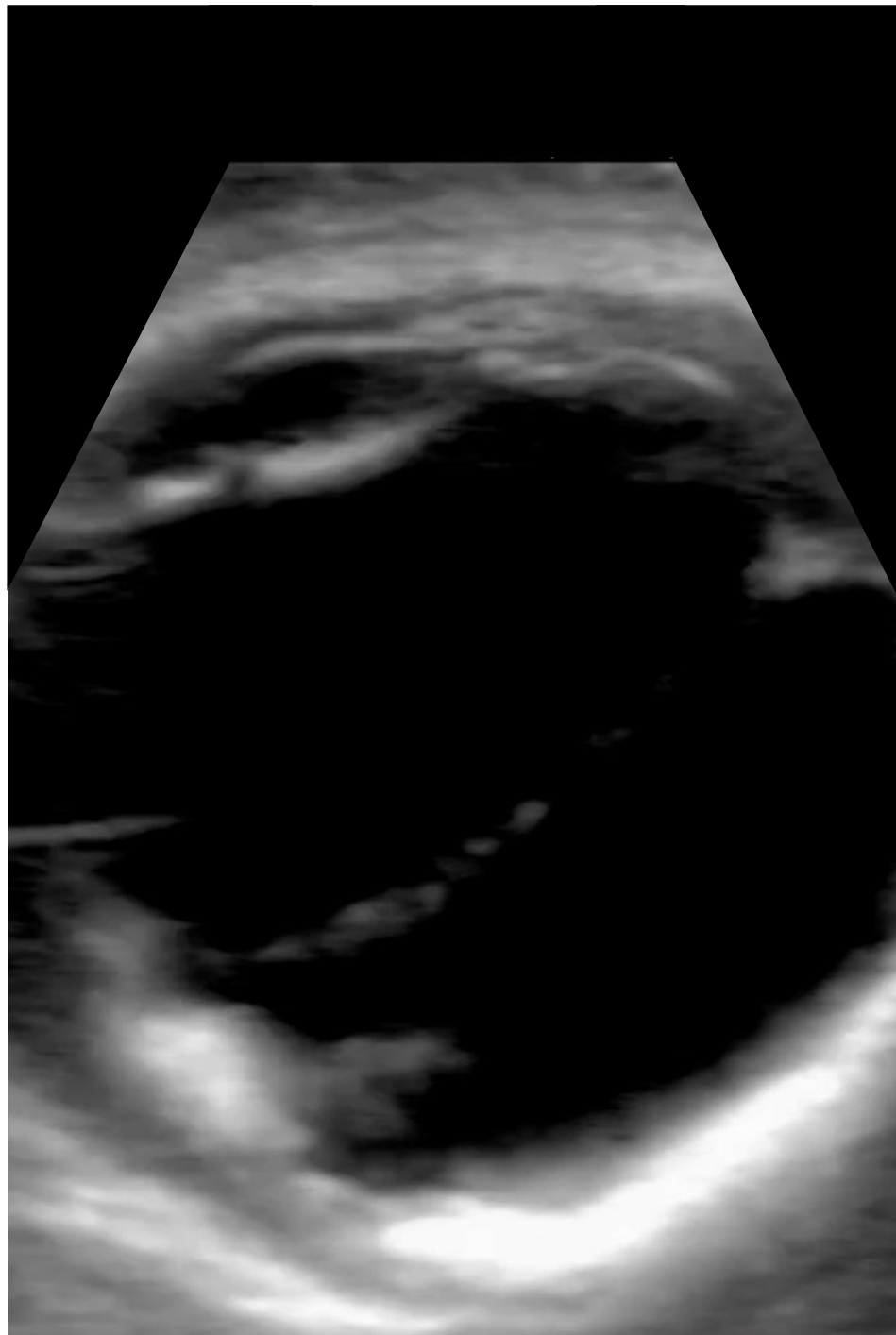
CC: CME F/u + Floaters  
71y/o M w/ cystoid  
macular degeneration  
OD, floater w/ PPV/AFX

# 5E



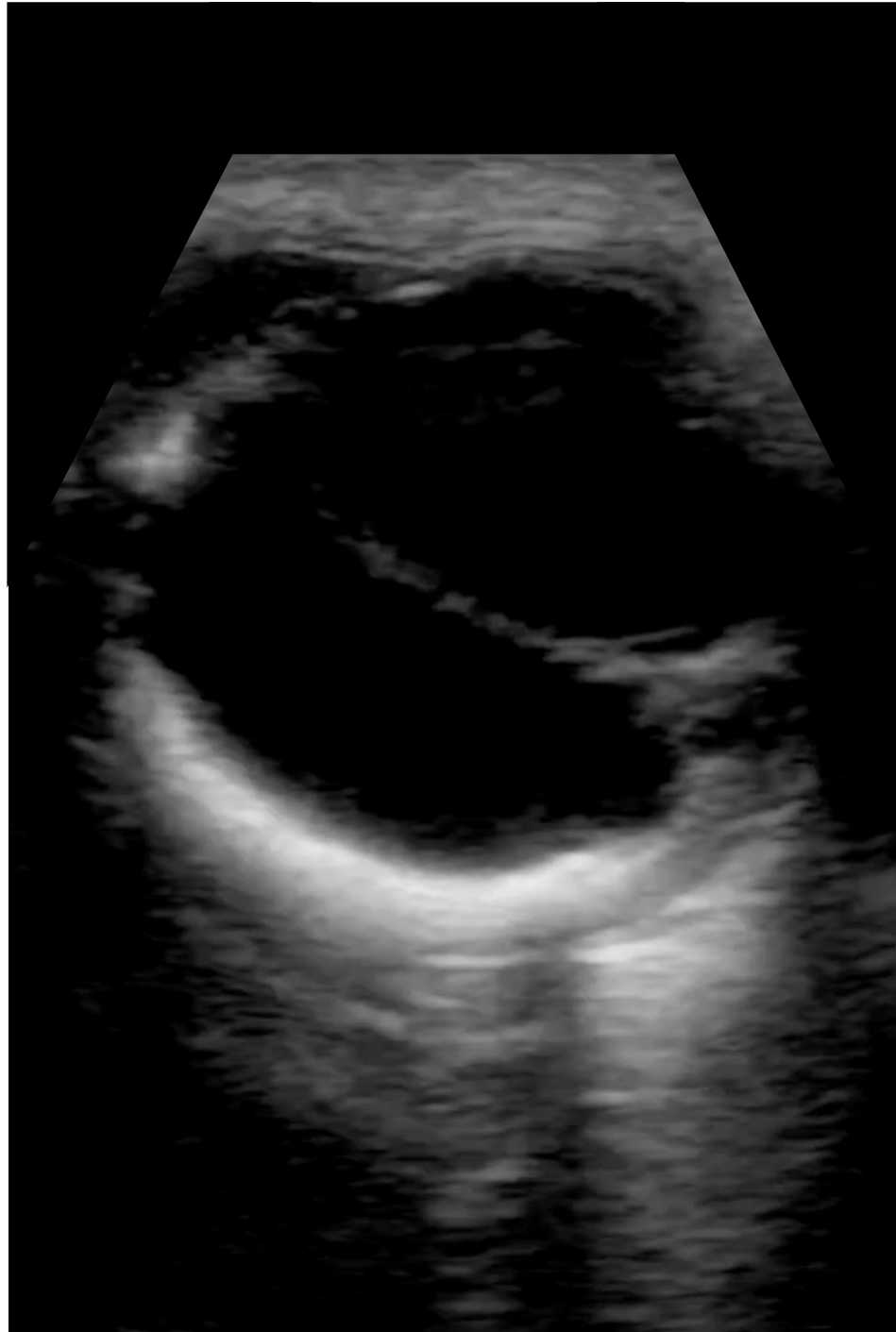CC: CME F/u + Floaters  
71y/o M w/ cystoid  
macular degeneration  
OD, floater w/ PPV/AFX

6A



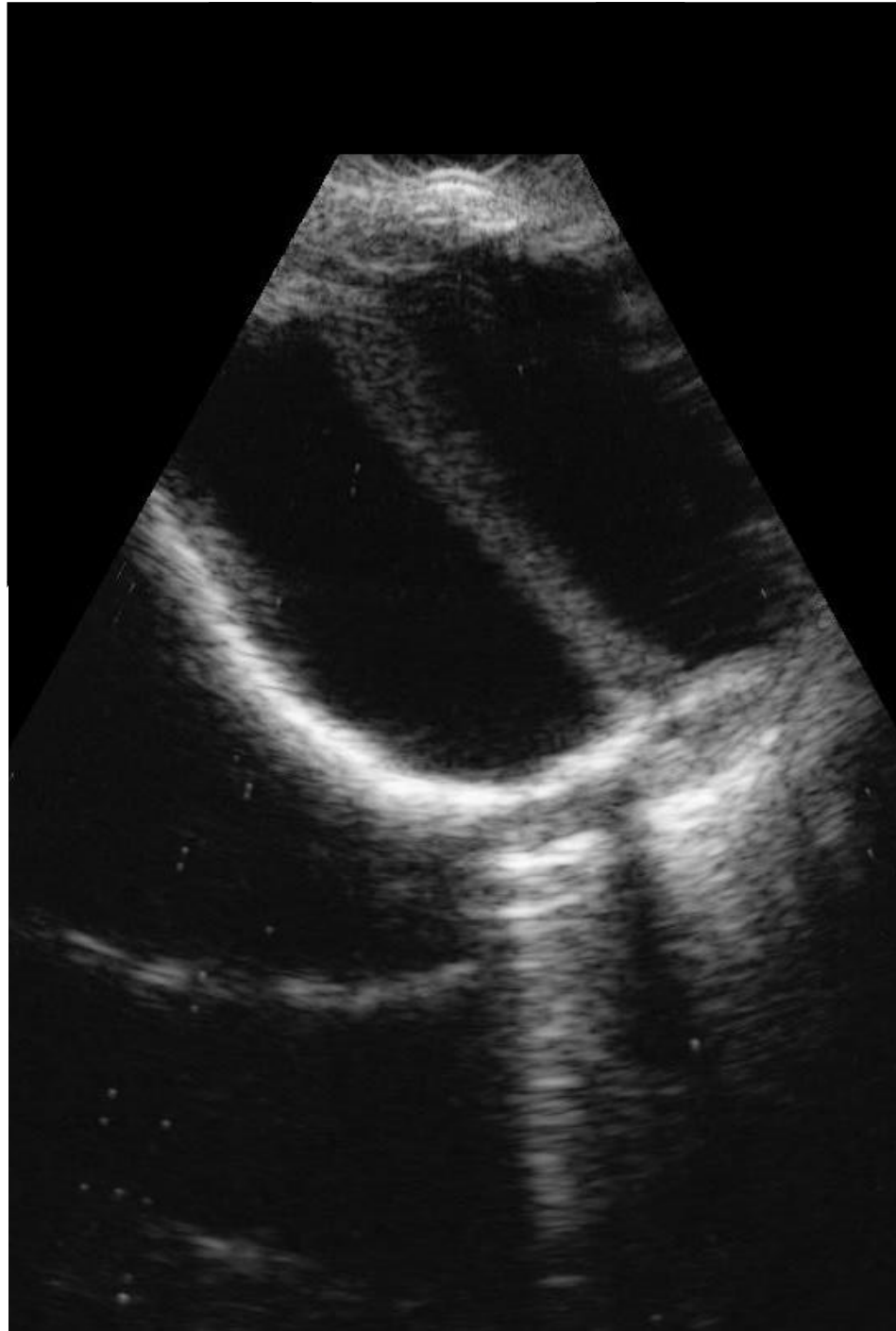
CC: OS Vit Heme F/u  
66 y/o M w/ h/o TRD OS,  
HIV, Aspergillus,  
tractional band, and  
diffuse retinal  
calcifications

6B



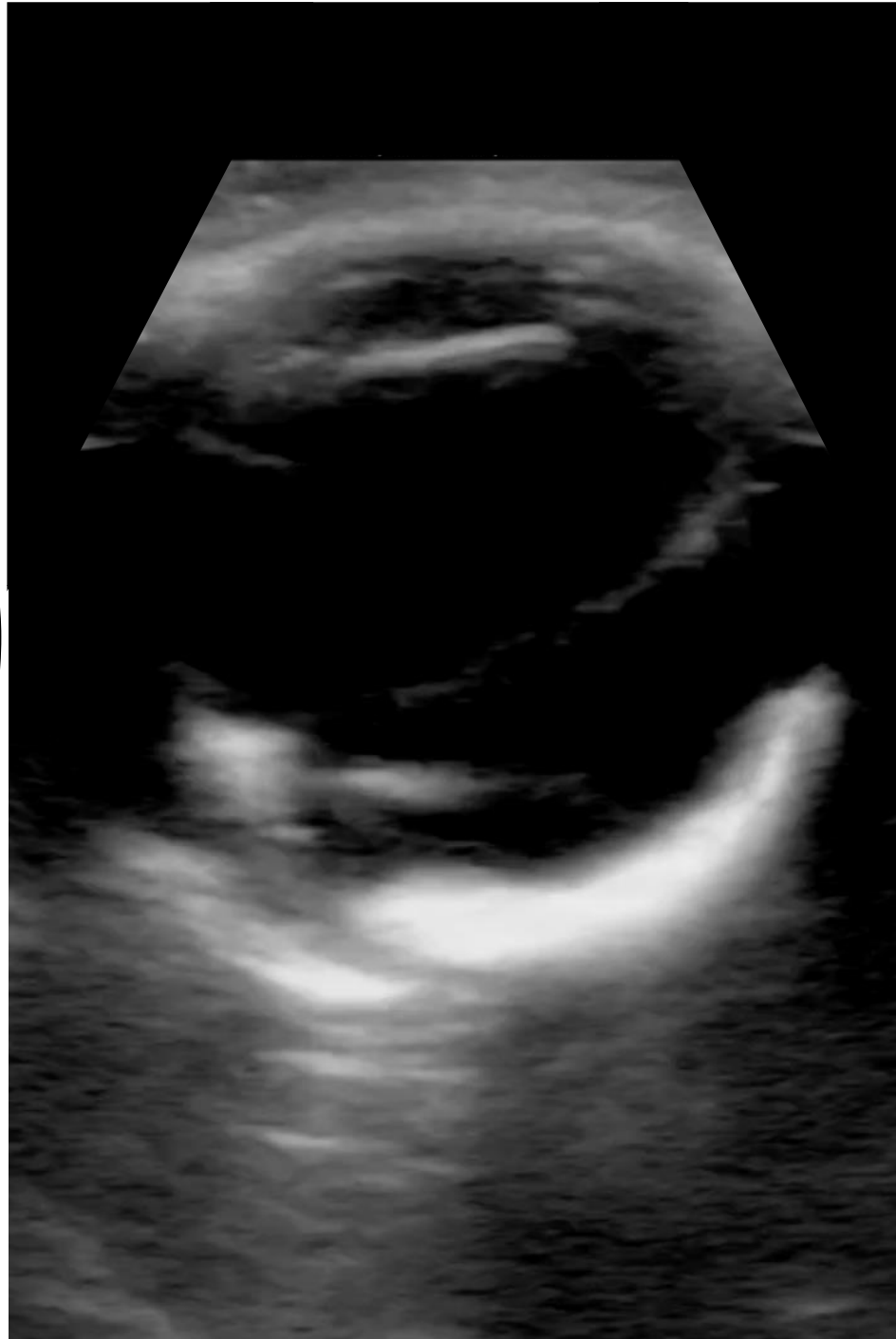CC: OS Vit Heme F/u  
66 y/o M w/ h/o TRD OS,  
HIV, Aspergillus,  
tractional band, and  
diffuse retinal  
calcifications

6C



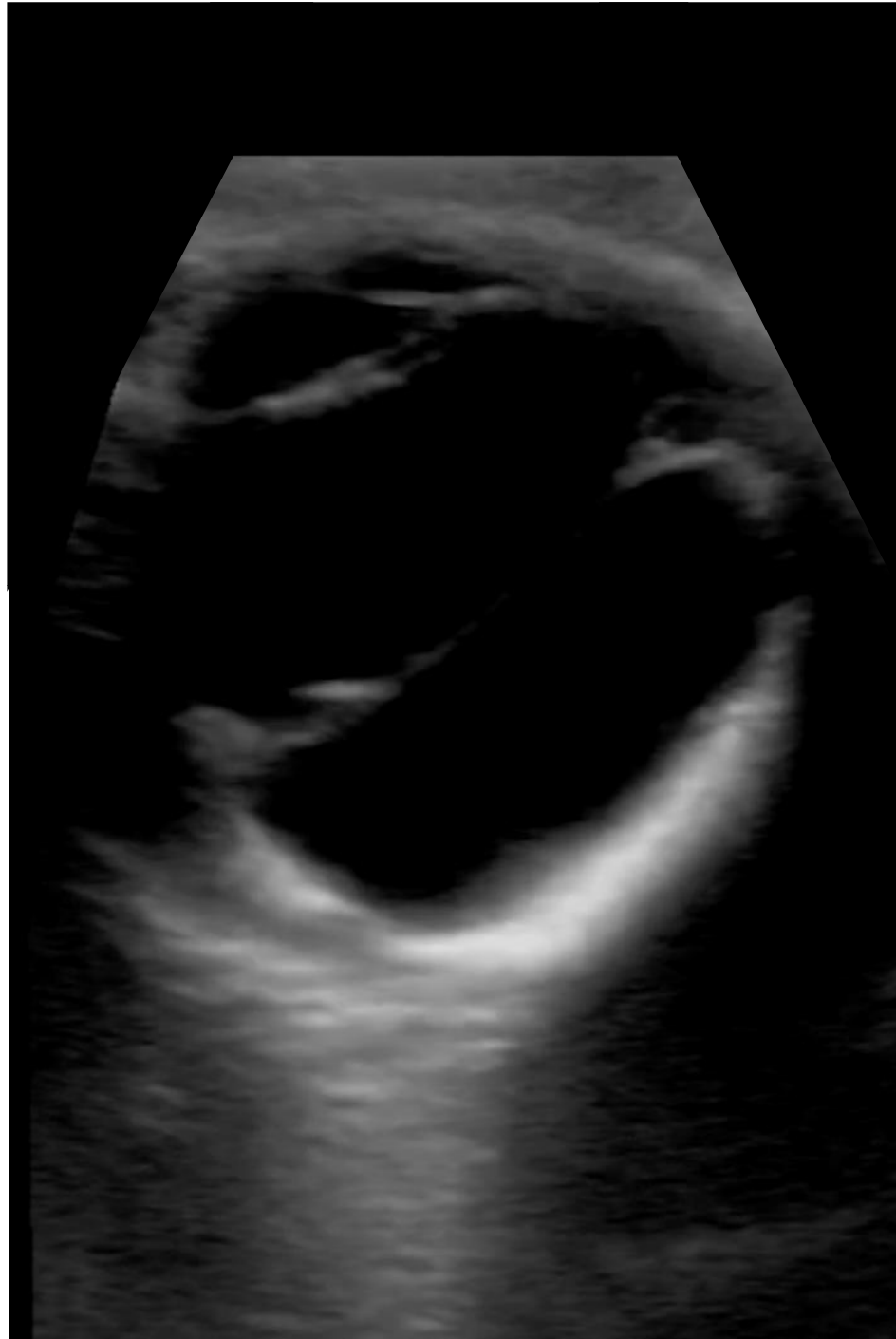CC: OS Vit Heme F/u  
66 y/o M w/ h/o TRD OS,  
HIV, Aspergillus,  
tractional band, and  
diffuse retinal  
calcifications

6D



CC: OS Vit Heme F/u  
66 y/o M w/ h/o TRD OS,  
HIV, Aspergillus,  
tractional band, and  
diffuse retinal  
calcifications

6E



CC: OS Vit Heme F/u  
66 y/o M w/ h/o TRD OS,  
HIV, Aspergillus,  
tractional band, and  
diffuse retinal  
calcifications

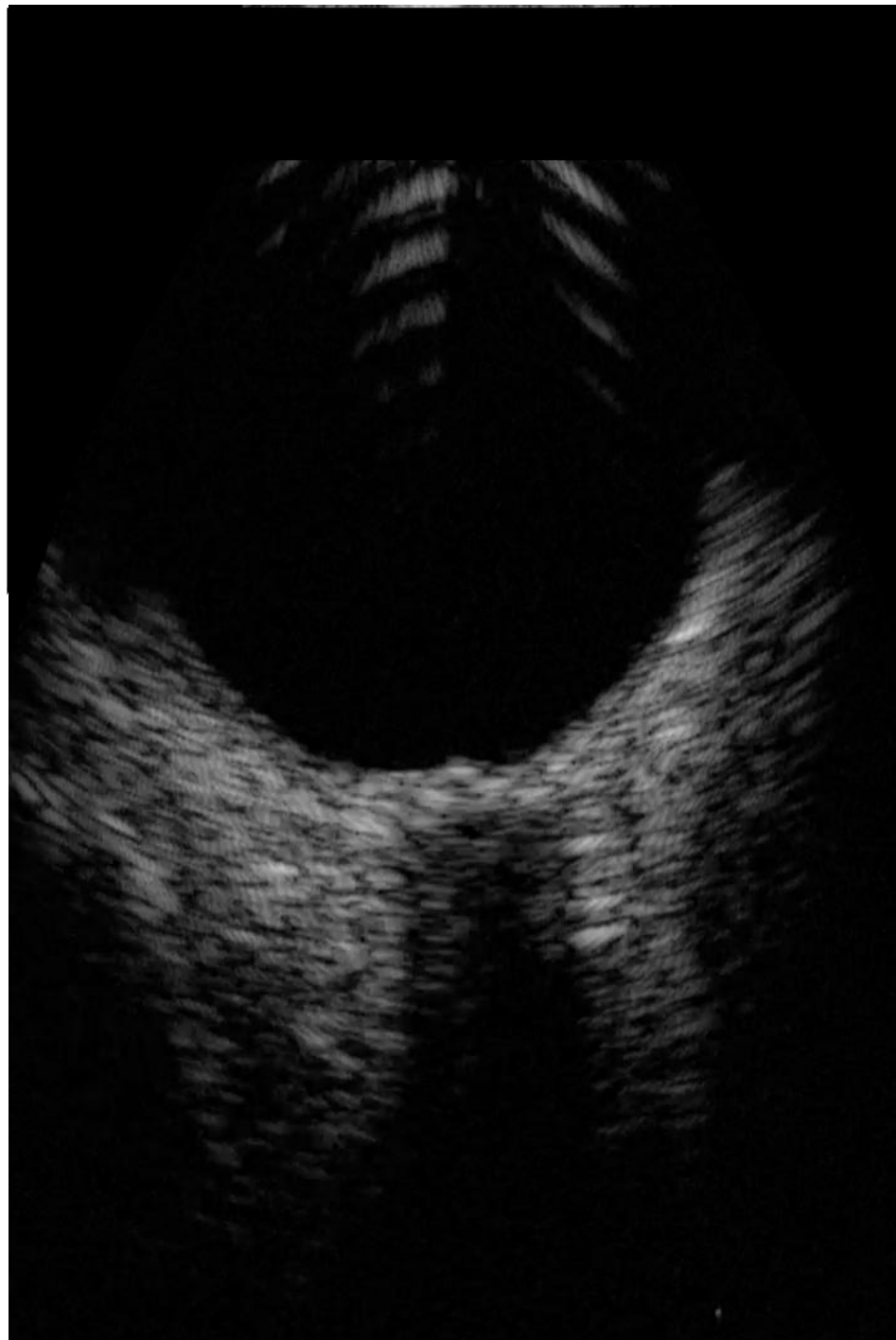
7A



CC: Routine Visit  
Healthy Subject no POH

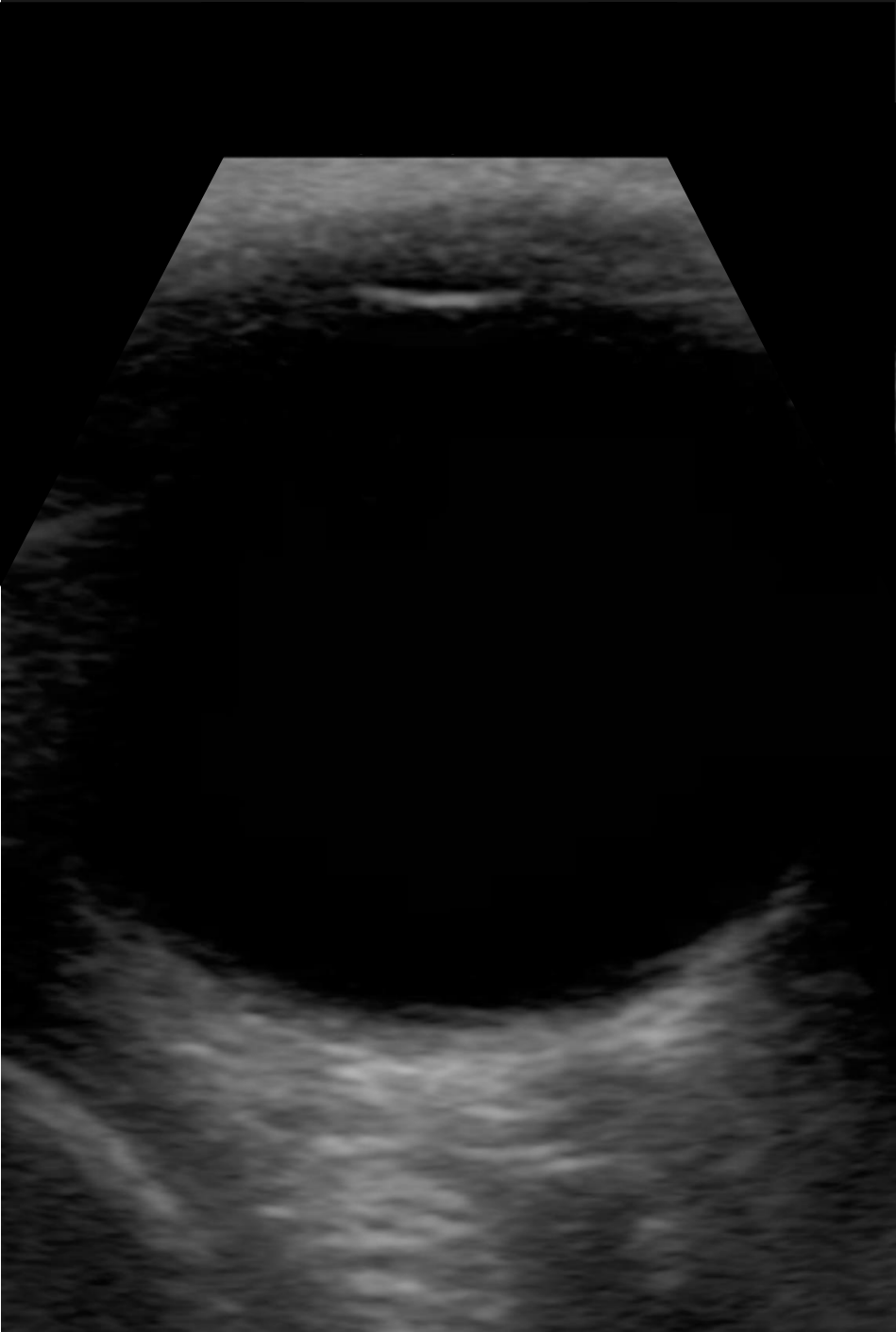

7B



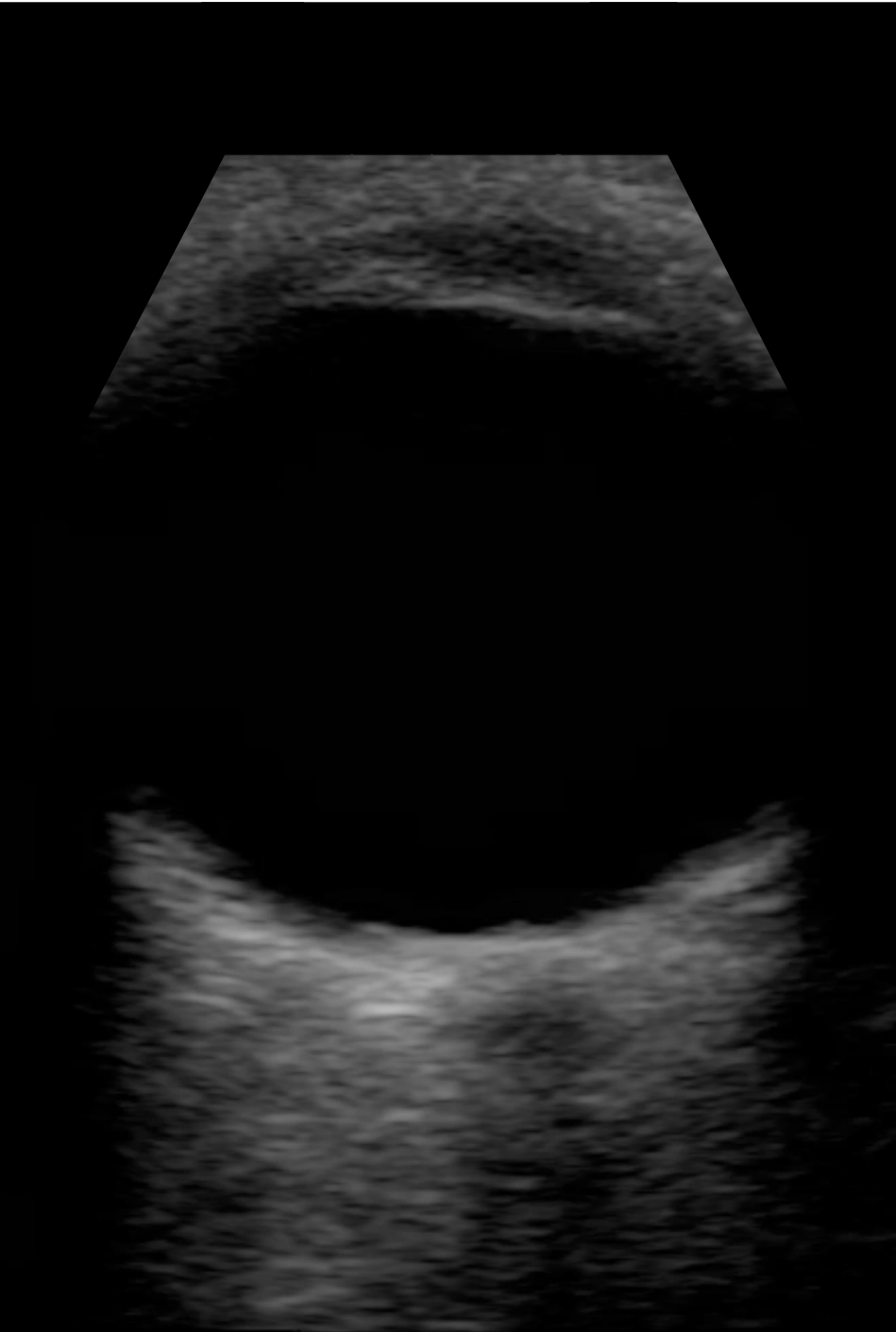CC: Routine Visit  
Healthy Subject no POH

7C



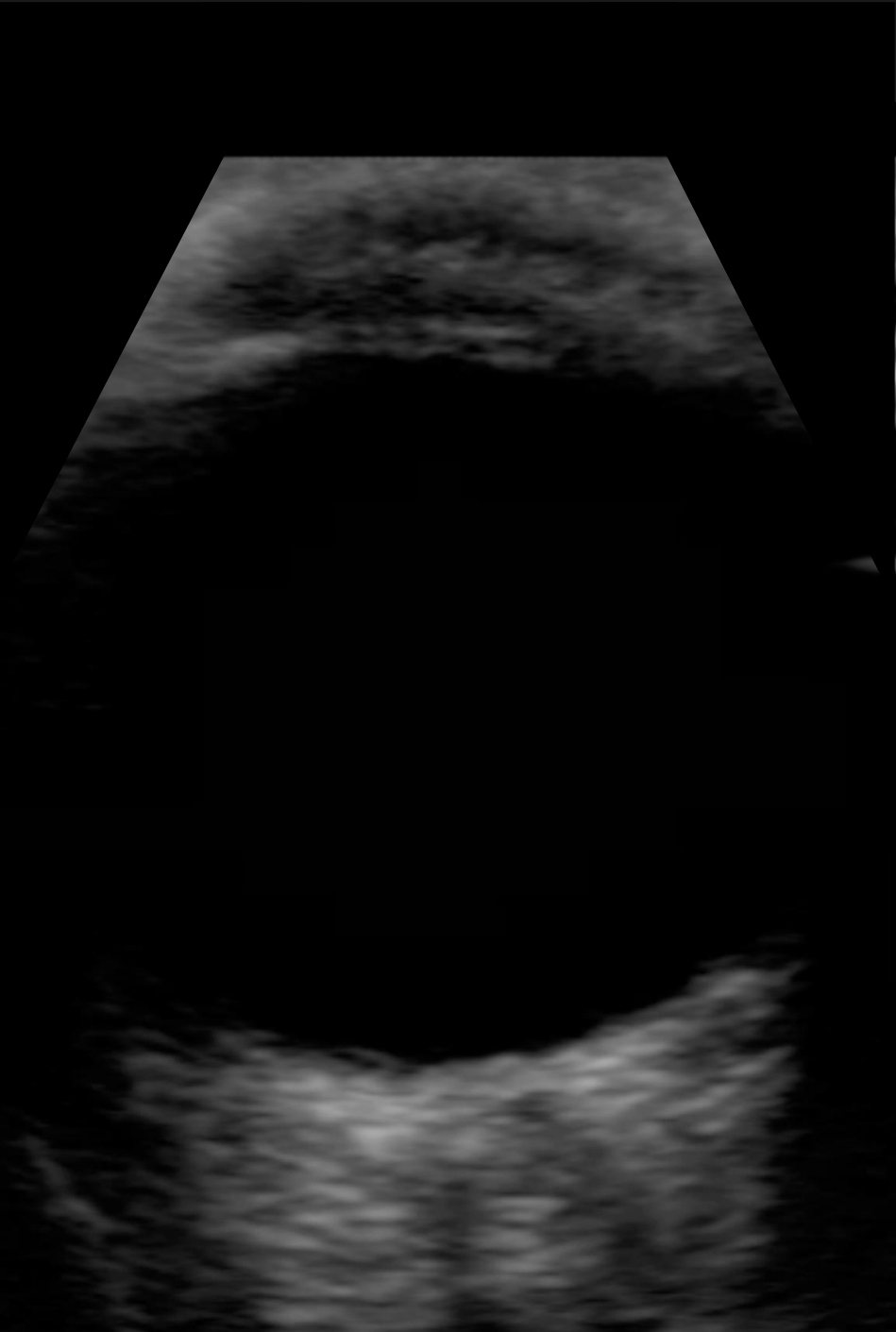
CC: Routine Visit  
Healthy Subject no POH

7D



CC: Routine Visit  
Healthy Subject no POH

7E



CC: Routine Visit  
Healthy Subject no POH