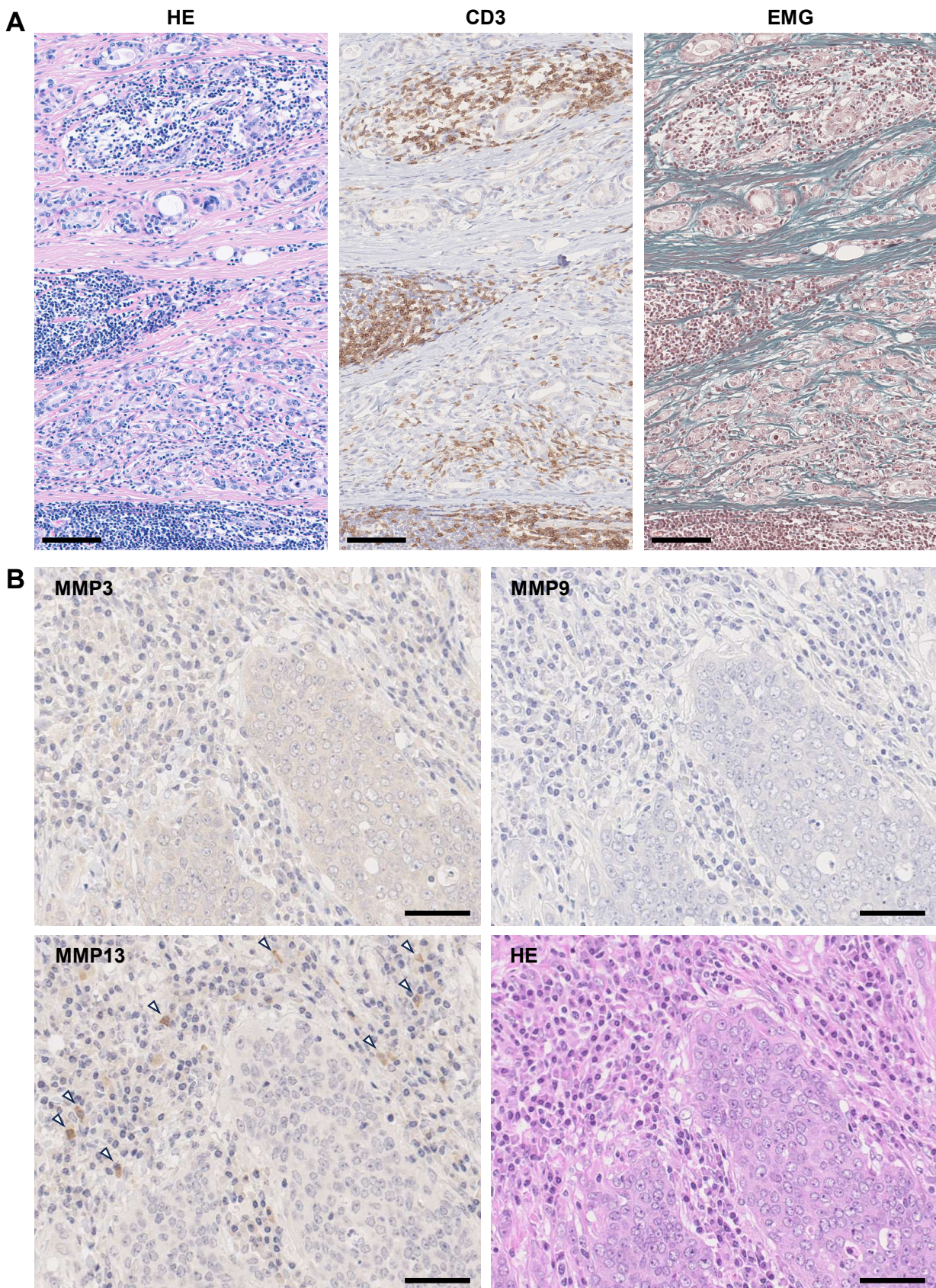


Supplementary Figure 1



Histological analysis of gastric cancer tissues. (A) Serial sections of tumor tissue from Patient 86 were analyzed by H&E, anti-CD3, and EMG staining. Original magnification, $20\times$. Scale bars indicate $100\ \mu\text{m}$. (B) Representative images of tumor tissues from bsPD-L1⁺ patients. Serial sections were analyzed by anti-MMP3, 9, and 13 and H&E staining. Original magnification, $20\times$. Scale bars indicate $50\ \mu\text{m}$. Nuclei were counterstained with hematoxylin (blue). The arrow heads represent MMP13⁺ cells.