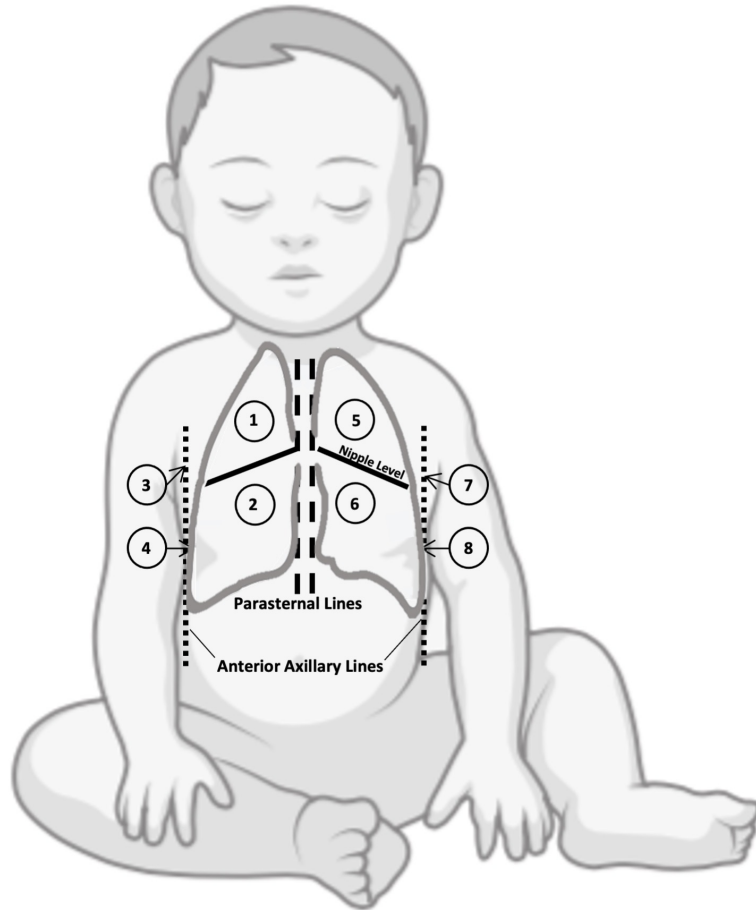
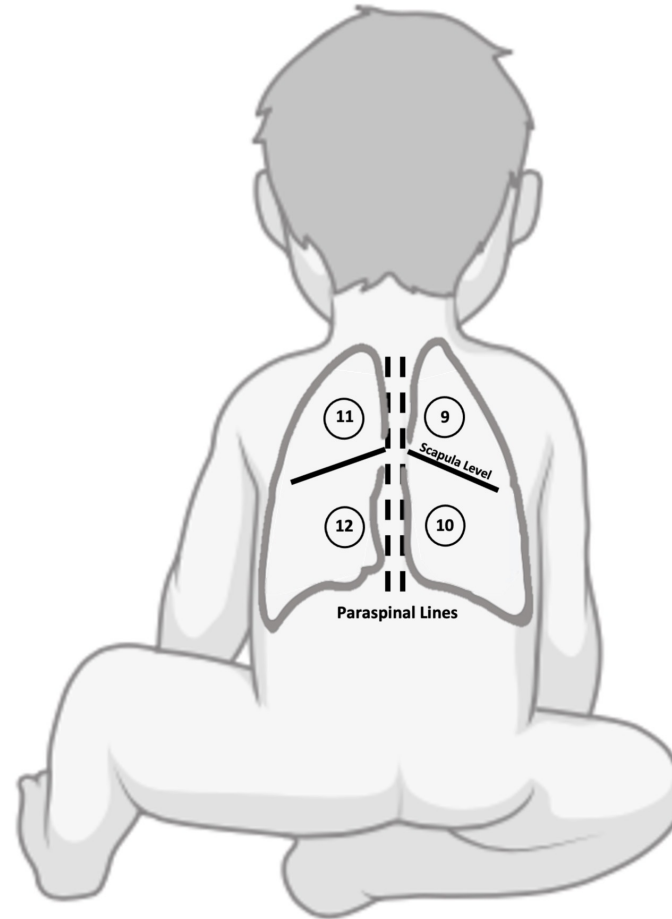


## Anterior / Lateral Zones



## Posterior Zones



### **S1 Fig. Scanning zones for Pediatric Lung Ultrasound**

Lung image acquisition areas. Anterior scan areas: right hemithorax – areas 1, 2, 3, and 4; left hemithorax – areas 5, 6, 7, and 8. Posterior scan areas: right hemithorax – areas 9 and 10; left hemithorax – areas 11 and 12. (Created with [BioRender.com](https://www.biorender.com))