

Timing of infiltration of T lymphocytes induced by gluten into the small intestine in coeliac disease

A R FREEDMAN,* J C MACARTNEY,† J M NELUFER,* P J CICLITIRA*

*From the *Division of Medicine and †Department of Histopathology, The Rayne Institute, United Medical and Dental School of Guy's and St Thomas's Hospitals, London*

SUMMARY Jejunal biopsy was performed on control subjects and patients with treated and untreated coeliac disease. Monoclonal antibodies to T lymphocyte surface markers were used to quantify T cell phenotypic subsets in the jejunal mucosa. The patients with untreated coeliac disease had significantly more of both suppressor/cytotoxic and helper/inducer T cells in the surface epithelium than either the control subjects or the treated patients. Serial jejunal biopsy specimens were taken from five treated coeliac patients for six hours after a gluten challenge. In four of these five infiltration of the surface epithelium by both T cell phenotypes, together with deterioration in the villus architecture, had occurred both within two hours of having started the challenge. This suggests that T lymphocytes may have a role in the pathogenesis of coeliac disease.

Coeliac disease is characterised by a small intestinal enteropathy, resulting in malabsorption. Histological sections of small intestinal mucosa taken from patients with untreated coeliac disease show a variety of abnormalities, including villus atrophy, elongation of the crypts, and abnormally flattened enterocytes with loss of their brush border.¹ Lymphocytes and plasma cells also infiltrate the mucosa. A gluten free diet resolves these changes.

The mechanism of mucosal damage caused by gluten in susceptible subjects remains unclear. Earlier suggestions that the toxicity of gluten was related to a primary specific small intestinal enzyme deficiency^{2,3} or to a lectin-like effect of gluten⁴ have not been substantiated.^{5,6}

A weight of evidence supports the hypothesis that the mucosal damage results from an immunological reaction to gluten. In vitro studies on small intestinal biopsy specimens from patients with coeliac disease showed specific activation to gliadin of both the humoral^{7,8} and cell mediated^{9,10} arms of the immune systems within the small intestinal mucosa.

Most small intestinal intraepithelial lymphocytes both in normal subjects and patients with coeliac disease are T cells.^{11,12} In untreated coeliac disease the number of intraepithelial T cells is increased relative to the number of enterocytes.^{13,14} This study aimed to quantitate intraepithelial and lamina propria T

lymphocyte subsets in the small intestinal mucosa of coeliac and control subjects and to compare the timing of changes in T cell density with that of the morphological damage to the small intestinal mucosa of patients with treated coeliac disease who had been subjected to a gluten challenge.

Patients and methods

Small intestinal biopsy specimens were taken from three subject groups: (i) control subjects (n = 6), who underwent biopsy as part of their diagnostic management and were subsequently found not to have coeliac disease; (ii) patients with treated coeliac disease (n = 5), in whom the diagnosis had previously been established by standard criteria¹⁵ and whose biopsy specimens showed either normal histology or a degree of partial villus atrophy; and (iii) patients with untreated coeliac disease (n = 5) whose biopsy specimens showed the typical histological changes of the disease and who subsequently showed improvement both clinically and in their small intestinal morphology after a period of withdrawal from dietary gluten.

Five patients, three males and two females, aged 17-57 years, with coeliac disease, which had been treated by gluten free diet for between eight months and 30 years, were subjected to serial jejunal biopsy. Biopsy specimens were taken prior to and at half hourly intervals up to six hours after a gluten chal-

lenge; this consisted of 10 g of gluten suspended in 150 ml of water and taken by mouth. One of these five patients served as a negative control by taking water only on a separate occasion. Another of these five had a further biopsy specimen taken one month after the initial challenge, during which time he consumed a normal diet containing gluten.

All biopsy specimens were obtained using a Quinton hydraulic multiple biopsy instrument, with the capsule positioned under fluoroscopic control in the proximal jejunum and left there for six hours in the patients who had been challenged with gluten. Informed consent was obtained from the patients before the study, which was approved by the ethical committee of St Thomas's Hospital.

Each biopsy specimen was carefully orientated on silver foil, coated in optimal cutting temperature (OCT) compound (Miles Laboratories), and snap frozen in liquid nitrogen and isopentane. Biopsy specimens were stored under liquid nitrogen until used.

MORPHOMETRY

Cryostat sections (5 μ m) were mounted on glass slides and stained with haematoxylin and eosin. The sections were examined using an eyepiece micrometer and a Leitz Wetzler microscope; five separate measurements each of villus height: crypt depth ratio and enterocyte surface-cell height were made and the mean values calculated.

LYMPHOCYTE COUNTING

Cryostat sections (5 μ m) mounted on glass slides were stained using an immunoperoxidase method as follows: the sections were air dried, fixed in acetone, and washed first in tap water and then in Tris buffered saline (TBS, pH 7.6). Murine monoclonal antibodies to different human T lymphocyte subsets were diluted 1 in 10 in TBS and applied to the sections for one hour in a moist chamber. The monoclonal antibodies (Becton Dickenson) used with their phenotypic specifications were anti-leu 4 to the pan T cell phenotype, anti-leu 3a to the helper/inducer T cell phenotype, and anti-leu 2a to the suppressor/cytotoxic T cell phenotype.

Sections were then washed in TBS and in a second layer antibody, peroxidase conjugated rabbit anti-

mouse immunoglobulin (Dako Ltd), diluted 1 in 50, and applied for 30 minutes. After further washing in TBS the sections were developed using 3, 3-diaminobenzidine as substrate. Cell nuclei were counterstained with Mayer's haematoxylin. The sections were finally washed, dehydrated in alcohol, cleared in xylene and mounted.

Separate sections from each biopsy specimen were stained with each of the three different monoclonal antibodies so that each T cell phenotypic subset could be counted. In the surface epithelium T lymphocytes were counted per 100 enterocytes in five separate fields using an objective at a magnification of 40 and the mean value taken. Lamina propria T cells were counted per unit area in three different villi, using an eyepiece graticule and the same magnification objective, and again the mean value was calculated. The area of the eyepiece graticule was 1.82×10^{-2} mm². Several biopsy specimens were found to be either too small or too distorted to permit accurate lymphocyte counting. For this reason it was not always possible to follow the changes in counts in each patient at regular half hourly intervals after the gluten challenge. For comparison, changes in T subsets after gluten challenge were presented as percentage changes from the values in the biopsy specimen taken before challenge (time 0). This was necessary because individual patients had different starting values for the numbers of cells in each T cell subset.

Results

BASELINE T SUBSETS

Table 1 shows the means of the individual counts of intraepithelial T lymphocytes that stained with the three different monoclonal antibodies and also the Leu 2a (suppressor/cytotoxic): Leu 3a (helper/inducer) ratios for the three subject groups in the first part of the study. In each group Leu 2a T cells greatly outnumbered Leu 3a positive cells. The patients with untreated coeliac disease had significantly more Leu 2a positive ($p < 0.0001$), Leu 3a positive ($p < 0.02$), and Leu 4 positive T cells ($p < 0.0001$) than the control subjects. Counts for the patients with treated coeliac disease were intermediate between the controls and the untreated patients, although they did

Table 1 Small intestinal intraepithelial T lymphocyte counts (mean (SD)/100 surface enterocytes) and suppressor/cytotoxic:helper/inducer cell ratios

	Leu 2a Suppressor/cytotoxic	Leu 3a Helper/inducer	Leu 4 Pan T	Leu 2a:Leu 3a ratio
Controls (n = 6)	22.0 (6.3)	3.2 (1.4)	27.2 (6.8)	6.9:1
Treated coeliac patients (n = 5)	31.6 (19.9)	3.3 (1.3)	40.1 (19.6)	9.6:1
Untreated coeliac patients (n = 5)	64.2 (9.9)	5.2 (0.9)	78.0 (10.4)	12.3:1

Table 2 Small intestinal lamina propria T lymphocyte counts (mean (SD) No/unit area) and suppressor/cytotoxic:helper/inducer cell ratios

	Leu 2a Suppressor/cytotoxic	Leu 3a Helper/inducer	Leu 4 Pan T	Leu 2a:Leu 3a ratio
Controls (n = 6)	39.5 (17.0)	59.9 (18.1)	101 (31.3)	1:1.5
Treated coeliac patients (n = 5)	38.2 (11.2)	68.2 (27.6)	110 (33.1)	1:1.8
Untreated coeliac patients (n = 5)	37.0 (11.1)	57.2 (25.1)	100.1 (37.4)	1:1.5

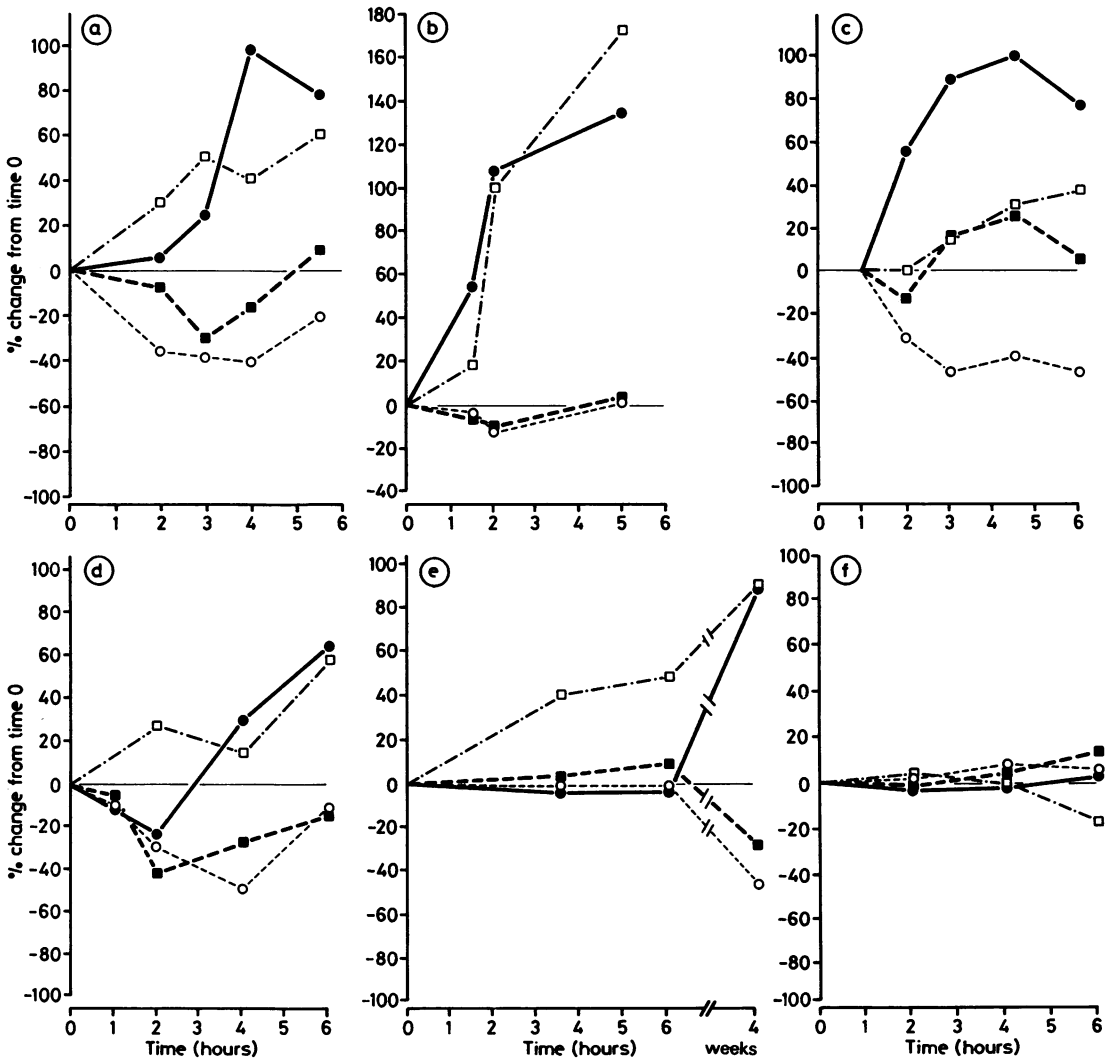


Figure Percentage changes in intraepithelial T lymphocyte counts and mucosal morphometry plotted against time in five patients given gluten challenge and one control patient given only water. ●—● Suppressor/cytotoxic T cells; □—□ helper/inducer T cells; ○—○ villus height: crypt depth ratio; ■—■ epithelial surface-cell height.

not differ significantly from the control group. The differences between the three groups in Leu 2a:Leu 3a ratios were not significant. In the lamina propria there were slightly more Leu 3a positive cells than Leu 2a positive cells (table 2), but there were no significant differences between the three subject groups for any of the three T lymphocyte subsets nor for the Leu 2a:Leu 3a ratios.

EFFECT OF GLUTEN CHALLENGE

Of the five patients with treated coeliac disease who were given a gluten challenge, four showed a similar pattern of changes in intraepithelial lymphocyte counts and morphometry. The figure shows their results as percentage changes from the values before challenge (time 0). There were no significant changes in T lymphocyte counts in the lamina propria in any of the subjects. Each of these four patients cases (a-d) showed an increase in both suppressor/cytotoxic and helper/inducer intraepithelial T cell counts concomitant with a deterioration in mucosal morphometry, shown by a reduction in villus height:crypt depth ratio and a fall in enterocyte height, although the latter actually increased in one patient (c) after an initial fall. These changes started within two hours of the gluten challenge in each subject but showed a variable degree of recovery by six hours. The fifth patient (e), in whom coeliac disease was diagnosed only eight months before the study, showed a very different pattern of changes; there was virtually no change in either intraepithelial suppressor/cytotoxic lymphocyte counts nor morphometric variables during the six hours after the gluten challenge, although there was an increase in epithelial helper/inducer lymphocytes. On rebiopsy, however, after four weeks on a normal diet containing gluten, he was found to have similar epithelial infiltration with both T cell subsets and changes in mucosal morphometry as had occurred in the other four patients during the first six hours.

As expected, in the patient who took water only (f) (figure), there was very little change in either epithelial lymphocyte counts or mucosal morphometry.

Discussion

This study clearly shows considerable differences between the surface epithelium and lamina propria of the small intestinal mucosa in terms of the T lymphocyte phenotype subpopulations, and emphasises the importance of studying them separately. In agreement with the findings of previous studies^{12,16-18} we found that most intraepithelial T cells, both in control and coeliac subjects, are of the suppressor/cytotoxic phenotype, whereas in the lamina propria there was a slight predominance of helper/inducer T cells. The

ratio of suppressor/cytotoxic:helper/inducer cells did not differ significantly between the controls and the treated and untreated coeliac patients in either layer. This ratio was therefore not measured in the challenge studies. In addition, there were no significant differences in the numbers of lamina propria T lymphocytes of any of the three phenotypes that were counted between the control subjects and the patients with treated and untreated coeliac disease. A gluten challenge given to patients with treated coeliac disease produced no significant change in T cell counts in the lamina propria during the first six hours. Lancaster-Smith *et al*¹⁹ also found no significant difference in total lamina propria lymphocyte numbers between control and coeliac patients, although a single gluten challenge given to treated patients did produce a small increase in lymphocyte numbers in the lamina propria 24 to 48 hours later, but which was no longer detectable at seven days. This increase may have been accounted for by B rather than T lymphocytes, and the authors also found a larger increase in lamina propria plasma cells both at 24-48 hours and seven days.

Finding the correct method of quantitating small intestinal intraepithelial lymphocytes has proved controversial. Ferguson and Murray¹³ counted the number of intraepithelial lymphocytes per 100 enterocytes to establish the normal range of values using data from 160 non-coeliac biopsy specimens. They found significantly increased intraepithelial lymphocyte counts in patients with untreated coeliac disease compared with controls. Intraepithelial lymphocyte counts were also raised above the value for normal controls in coeliac patients on a gluten free diet, although these were significantly lower than in the untreated group. Marsh,²⁰ however, argued that intraepithelial lymphocyte counts should be related to a fixed area of underlying muscularis mucosae (areal density) rather than to the number of enterocytes when comparing normal and coeliac mucosa, as coeliac and normal epithelium differ considerably in respect of their relative surface areas, structure, and cell sizes. In this study, however, we chose the former method as, like Corazza *et al*¹⁴ and Dobbins,²¹ we feel that it is the local density of lymphocytes within the epithelium that is most relevant when considering the possible aetiological role of these cells in coeliac disease. Like us, Jenkins *et al*¹⁸ also showed a much higher relative density of T lymphocytes in untreated coeliac small intestinal surface epithelium than in normal surface epithelium. These authors also showed a change in marker patterns of the intraepithelial lymphocytes "which might suggest an altered functional state rather than just an increase in density because of the non-specific crowding of cells into a reduced surface epithelial compartment."

Although we studied only a small number of

patients, in the small intestine of most patients with treated coeliac disease oral gluten challenge caused both damage to the villus architecture, evidenced by a reduction in villus height: crypt depth ratio and enterocyte height, and an increase in density of T lymphocytes in the surface epithelium; both of these events started within two hours of the challenge. The concurrent morphological and lymphocyte density changes suggest that they are interrelated. The delayed response to gluten challenge shown by one of our five patients suggests that there may be a sub-population of coeliac patients who relapse more slowly after reintroduction of dietary gluten. This is in keeping with the large variation in the time taken to relapse in a study performed by Kumar *et al.*²²

The speed with which changes in morphometry and intraepithelial lymphocyte counts occurred in our study in four of the five patients is somewhat surprising, and is faster than has previously been reported. Anand *et al.*²³ in a study of two coeliac subjects, detected the first histological changes three to four hours after gluten challenge and suggested that the timing was in keeping with an Arthus type reaction producing the mucosal damage. Bramble *et al.*²⁴ found changes both in brush border enzymes and villus population counts one to two hours after gluten challenge, but no significant changes in the villus height or crypt depth within 24 hours of the challenge.

Our findings of a rapid increase in density of T lymphocytes in the surface epithelium of the small intestine of treated coeliac patients following gluten challenge, coinciding with the observed damage to the villus architecture, suggest that T lymphocytes have a role in the pathogenesis of the disease, although further work is required to elucidate the exact nature of that role.

ARF is supported by a grant from the St Thomas's Hospital research (endowments) committee. PJC is a Wellcome senior research fellow in clinical science. We thank Dr B Creamer for allowing us to study patients under his care and Barbara E Issom for typing the manuscript.

References

- 1 Stewart JS, Pollock DJ, Hoffbrand AV, Mollin DL, Booth CC. A study of proximal and distal intestinal structure and absorptive functions in idiopathic steatorrhoea. *Q J Med* 1967;36: 425-44.
- 2 Frazer AC. Discussion on some problems of steatorrhoea and reduced stature. *Proc Roy Soc Med* 1956;49:1009-13.
- 3 Weijers HA, Van De Kamer JH. Coeliac disease IV: a rapid method to test wheat sensitivity. *Acta Paediatr* 1955;44:536-40.
- 4 Weiser MM, Douglas AP. An alternative mechanism for gluten toxicity in coeliac disease. *Lancet* 1976;i:567-9.
- 5 Douglas AP, Peters TJ, Hoffbrand AV, Booth CC. Studies of intestinal peptidases with specific reference to coeliac disease. In: Booth CC, Dowling RH, eds. *Coeliac disease*. Edinburgh: Churchill Livingstone, 1970:115-22.
- 6 Colyer J, Farthing MJG, Kumar PJ, Clarke ML, Ohanesian AD, Waldron NM. Reappraisal of the "lectin hypothesis" in the aetiopathogenesis of coeliac disease. *Clin Sci* 1986;71: 105-10.
- 7 Falchuk ZM, Strober W. Gluten-sensitive enteropathy: Synthesis of anti gliadin antibody in vitro. *Gut* 1974;15:947-52.
- 8 Ciclitira PJ, Ellis HJ, Wood GM, Howdle PD, Losowsky MS. Secretion of gliadin antibody by coeliac jejunal mucosal biopsies cultured in vitro. *Clin Exp Immunol* 1986;64:119-24.
- 9 Ferguson A, MacDonald TT, McClure JP, Holden RJ. Cell-mediated immunity to gliadin within the small intestinal mucosa in coeliac disease. *Lancet* 1975;i:895-7.
- 10 Howdle PD, Bullen AW, Losowsky MS. Cell-mediated immunity to gluten within the small intestinal mucosa in coeliac disease. *Gut* 1982;23:115-22.
- 11 Selby WS, Janossy G, Jewell DP. Immunohistological characterisation of intraepithelial lymphocytes of the human gastrointestinal tract. *Gut* 1981;22:169-76.
- 12 Selby WS, Janossy G, Bofill M, Jewell DP. Lymphocyte subpopulations in the human small intestine. The findings in normal mucosa and in the mucosa of patients with adult coeliac disease. *Clin Exp Immunol* 1983;52:219-28.
- 13 Ferguson A, Murray D. Quantitation of intraepithelial lymphocytes in human jejunum. *Gut* 1971;12:988-94.
- 14 Corazza GR, Frazonni M, Gassbarrini G. Jejunal intraepithelial lymphocytes in coeliac disease: are they increased or decreased? *Gut* 1984;25:158-62.
- 15 Meeuwisse G. Diagnostic criteria in coeliac disease. *Acta Paediatr Scand* 1970;59:461-3.
- 16 Flores AF, Winter HS, Bhan AK. In vitro model to assess immunoregulatory T lymphocyte sub-populations in gluten sensitive enteropathy. *Gastroenterology* 1982;82:105.
- 17 Malizia G, Trejdosiewicz LK, Wood GM, Howdle PD, Janossy G, Losowsky MS. The microenvironment of coeliac disease: T cell phenotypes and expression of the T2 "T blast" antigen by small bowel lymphocytes. *Clin Exp Immunol* 1985;60:437-46.
- 18 Jenkins D, Goodall A, Scott BB. T-lymphocyte populations in normal and coeliac small intestinal mucosa defined by monoclonal antibodies. *Gut* 1986;27:1330-7.
- 19 Lancaster-Smith M, Kumar PJ, Dawson AM. The cellular infiltrate of the jejunum in adult coeliac disease and dermatitis herpetiformis following the reintroduction of dietary gluten. *Gut* 1975;16:683-8.
- 20 Marsh MN. Studies of intestinal lymphoid tissue. III Quantitative analysis of epithelial lymphocytes in the small intestine of human control subjects and of patients with coeliac sprue. *Gastroenterology* 1980;79:481-92.
- 21 Dobbins WO. III Human intestinal intraepithelial lymphocytes. *Gut* 1986;27:972-85.
- 22 Kumar PJ, O'Donoghue DP, Stenson K, Dawson AM. Reintroduction of gluten in adults and children with treated coeliac disease. *Gut* 1979;20:743-9.
- 23 Anand BS, Piris J, Jerrone DW, Offord RE, Truelove SC. The timing of histological damage following a single challenge with gluten in treated coeliac disease. *Q J Med* 1981;50:83-94.
- 24 Bramble MG, Zucoloto S, Wright NA, Record CO. Acute gluten challenge in treated adult coeliac disease: a morphometric and enzymatic study. *Gut* 1985;26:169-74.

Requests for reprints to: Dr PJ Ciclitira, The Rayne Institute, St. Thomas's Hospital, London SE1 7EH, England.