

# Simple procedure for assessing relative quantities of neutral and acidic sugars in mucin glycoproteins: its use in assessing cyclical changes in cervical mucins

C B GILKS, P E REID, P B CLEMENT, D A OWEN *Department of Pathology, University of British Columbia, Vancouver, Canada*

**SUMMARY** A simple histochemical procedure for assessing relative amounts of neutral and acidic sugars in mucin glycoproteins, and its application in the study of cyclical changes of human cervical mucins, is described. This procedure, the saponification/selective periodate oxidation/borohydride reduction/alcian blue pH 2.5/periodic acid Schiff (KOH/PA\*/Bh/Ab 2.5/PAS) method, uses a selective oxidation step to remove the PAS positivity of sialic acid; thus only neutral sugars stain positively with PAS, and acidic sugars (O-sulphate esters and carboxyl groups) stain with alcian blue. This differs from the KOH/Ab/PAS technique which stains sialic acid residues with both alcian blue and PAS. Applying the KOH/PA\*/Bh/Ab 2.5/PAS technique to the study of cyclical changes of human cervical mucins, a decreased neutral:acidic sugar ratio in the secretory phase mucins compared with those of the proliferative phase was found. This difference was not seen with KOH/Ab/PAS staining in the same cases.

The techniques and reagents used in this procedure can be easily applied in a clinical histopathology laboratory.

The alcian blue pH 2.5/periodic acid Schiff (Ab 2.5/PAS) technique of Mowry<sup>1</sup> stains magenta sugars with oxidisable vicinal diols and anionic groups (carboxyl and O-sulphate esters) aquamarine blue (aqua). Sialic acids contain both vicinal diols and carboxyl groups and stain purple. Consequently it may be difficult to use the Ab 2.5/PAS method for the histochemical assessment of the relative proportion of neutral and acidic sugars in mucins because changes in sialic acid concentration can be obscured by the dual staining of this residue.

During studies on the histochemical analysis of human cervical and intestinal mucin glycoproteins, it became important to develop a more specific procedure for assessing relative quantities of neutral and acidic sugars in such mucins. Several studies have shown that under certain conditions sialic acids can be selectively oxidised with periodate ion.<sup>2-6</sup> Recently Volz *et al'* have shown that treatment with 0.4 mM periodic acid in about 1 M hydrochloric acid for one hour at 4°C (selective periodate oxidation (PA\*)) will completely oxidise all sialic acid residues without

producing noticeable Schiff reactivity in carbohydrate polymers containing only neutral sugars.<sup>7,8</sup>

In this paper we describe the use of PA\* in the development of a histochemical technique, the saponification/selective periodate oxidation/borohydride reduction/Ab 2.5/PAS (KOH/PA\*/Bh/Ab 2.5/PAS) technique, for the assessment of the relative quantities of acidic sugars (O-sulphate esters, carboxyl groups) and "neutral sugars" with periodate oxidisable vicinal diols (hexoses, 6-deoxyhexoses, N-acetyl hexosamines) and its application to human cervical mucin.

## Material and methods

Specimens of Sprague-Dawley rat liver, salivary glands (sublingual, submandibular, and parotid), and gastrointestinal tract, obtained fresh at necropsy, were fixed in 10% formalin-calcium for periods in excess of seven days. After fixation "swiss rolls" were prepared from the colon and the entire small intestine plus a strip of stomach.<sup>9</sup> All the tissues were routinely processed in paraffin wax and embedded in Paraplast. Studies were also performed on formalin fixed, paraffin wax processed blocks of surgical specimens of

a human stomach, cervix, and colonic adenocarcinoma containing adjacent normal tissue. Specimens of normal cervix ( $n = 46$ ) were obtained from hysterectomy specimens and specimens of endometrium from each case were independently phased according to accepted histological criteria<sup>10</sup> by two of the authors (CBG, PBC). Sections cut at a thickness of  $5 \mu\text{m}$  were stained with haematoxylin and eosin, the Ab 2.5/PAS method of Mowry,<sup>1</sup> and the PA\*/Bh/Ab 2.5/PAS method described below. The latter two staining procedures were preceded by saponification with 0.5% potassium hydroxide in 70% ethanol for 15 minutes.

The saponification step was included for the following reasons. Firstly, Park, *et al* have shown that the mucous cells of the rat descending colon contain neutral sugars which are only PAS reactive after KOH treatment (O-acyl sugars)<sup>11</sup>; similar sugars have been shown in the colonic epithelial glycoproteins of man and rabbit (P E Reid *et al*, unpublished observations). Thus the KOH step is necessary in a general procedure to ensure that O-acyl sugars, if present, are PAS reactive. Secondly, the KOH step ensures the complete oxidation of sialic acids with PA\*<sup>7,8</sup> and therefore avoids the possibility that any side chain O-acylated sialic acids which may be present are de-O-acylated in the subsequent steps of the procedure and contribute to PAS reactivity attributed to neutral sugars. Finally, in the KOH/Ab 2.5/PAS procedure the KOH step is necessary because PAS reactivity will depend on the presence or absence of O-acylated sialic acids. As in this study the results obtained with the KOH/Ab 2.5/PAS procedure were compared with those of the KOH/PA\*/Bh/Ab 2.5/PAS procedure, the inclusion of the KOH step in the latter method ensures that the procedures are as comparable as possible. Diastase digestion can be inserted between steps 3 and 4 in the method described below if desired.

THE SAPONIFICATION-SELECTIVE PERIODIC ACID  
OXIDATION - BOROHYDRIDE REDUCTION -  
ALCIAN BLUE pH 2.5 - PENODIC ACID - SCHIFF  
(KOH/PA\*/Bh/Ab 2.5/PAS) TECHNIQUE

- 1 Bring sections to water.
- 2 Treat with 0.5% (w/v) potassium hydroxide in 70% (v/v) ethanol for 15 minutes at room temperature to remove any O-acyl groups that may be present on sialic acids or neutral sugars.
- 3 Wash in running water for 10 minutes.
- 4 Cool to 4°C and oxidise with precooled (4°C) 0.4 mM periodic acid in about 1 M hydrochloric acid (concentrated hydrochloric acid 1 volume, distilled water 4 volumes) at 4°C for one hour at room temperature (PA\*) to oxidise completely all sialic acids.<sup>7,8</sup>
- 5 Wash in running water for 10 minutes.
- 6 Treat with 0.1% (w/v) sodium borohydride in 1%

(w/v) dibasic sodium phosphate (anhydrous) for 20 minutes at room temperature to reduce aldehydes to Schiff unreactive primary alcohols.<sup>12</sup>

- 7 Wash in running water for 10 minutes at room temperature.
- 8 Stain with 0.3% (w/v) alcian blue 8GX in 3% (v/v) acetic acid for 20 minutes at room temperature to stain carboxyl and O-sulphate ester groups.
- 9 Wash in running water for 10 minutes.
- 10 Treat with 1% (w/v) periodic acid for one hour at room temperature, to oxidise vicinal diols.
- 11 Wash in running water for 10 minutes.
- 12 Treat for one hour at room temperature with pararosaniline Schiff reagent (prepared by the method of Barger and DeLamater<sup>13</sup>) to stain aldehydes.
- 13 Wash in running water for 10 minutes.
- 14 Dehydrate, clear, and mount.

Neutral sugars stain magenta; sialic acid carboxyl groups and O-sulphate esters stain aqua; mixtures of acidic and neutral sugars stain shades of purple.

Staining of cervical mucin was graded on a scale from 1 (aqua) to 5 (magenta). Observations were made by two observers using a co-observation bridge and a consensus result was recorded.

Raw data were analysed by the Mann-Whitney U test<sup>14</sup> and p values of  $< 0.05$  for the two tailed test were considered to be significant.

## Results

The results of staining of the different control tissues from Sprague-Dawley rats agreed with the known distribution of stainable sugars.<sup>7,11,15</sup> The sialoglycoprotein of rat sublingual gland stained blue while the neutral glycoprotein of the submandibular gland stained magenta. The neutral mucin of the stomach stained strongly magenta but small amounts of blue mucin were present at the base of gastric pits. In contrast, the goblet cell sialosulphomucins of the duodenum stained purple while the neutral mucins of the Brunner's glands stained magenta. The goblet cells at the bases of the crypts of the rat descending colon stained bluer than those located more superficially in the crypts. In sections of colonic adenocarcinoma stained with KOH/PA\*/Bh/Ab 2.5/PAS, pools of predominantly extracellular mucin within the tumour stained magenta while the mixed acidic and neutral sugars of the adjacent transitional epithelium<sup>16</sup> stained purple. Glycogen in rat liver stained strongly magenta; this staining was eliminated by diastase digestion.

Comparing cervixes from proliferative phase and luteal phase, a significant ( $0.02 < p < 0.05$ ) difference in the neutral:acidic sugar ratio was seen with KOH/PA\*/Bh/Ab 2.5/PAS staining, with relatively

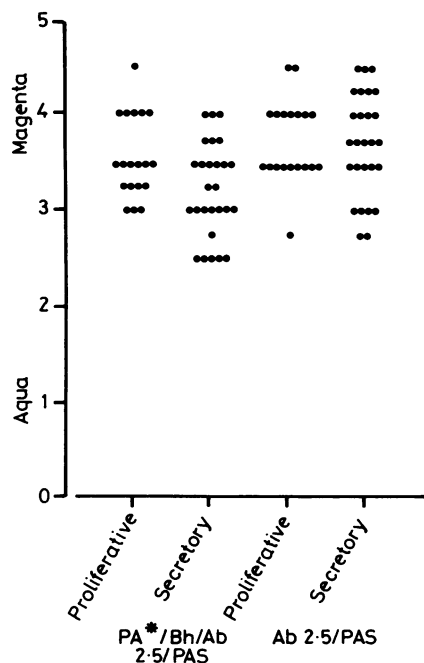


Fig 1 Results of semiquantitative assessment of sections of human cervixes during proliferative and secretory phases after KOH/PA\*/Bh/Ab 2-5/PAS (left) and KOH/Ab 2-5/PAS (right) staining. Higher assessed numerical grades correspond to higher neutral:acidic sugar ratios.

more acidic sugar present in the secretory phase while no significant difference was seen with KOH/Ab 2-5/PAS staining (figure). Overall, there was more intense PAS positivity with the KOH/Ab 2-5/PAS technique corroborated by higher neutral:acidic sugar ratios. Sialic acid will be PAS positive using this technique.

## Discussion

The KOH/PA\*/Bh/Ab 2-5/PAS method specifically stains neutral and acidic sugars magenta and aqua, respectively. Application of this technique to specimens of human endocervix shows significant changes in the ratio of neutral:acidic sugars during the menstrual cycle. The mucin glycoprotein secreted by the human endocervical mucosa forms the predominant solid component of cervical mucus. This mucus is receptive to sperm penetration for a period of about five days in the periovulatory period when, in response to oestrogenic stimulation, it becomes more copious in amount, much less viscous and less acidic.<sup>17-19</sup>

While the protein component of cervical mucin is constant during the menstrual cycle, it remains controversial whether the carbohydrate component

changes significantly during a normal cycle.<sup>20-23</sup> Recently Wakefield and Wells showed that cervical mucin in the secretory phase of the normal menstrual cycle has an increased ratio of sulphated acidic sugars to sialic acids.<sup>24</sup> The new histochemical technique complements these results by showing a decreased ratio of neutral sugars to total acidic sugars during the secretory phase. This method, the KOH/PA\*/Bh/Ab 2-5/PAS procedure, uses techniques and reagents which can be easily introduced into a clinical histopathology laboratory, and permits the semiquantitative assessment of the relative amounts of acidic and neutral sugars.

## References

- Mowry RW. Special value of methods that colour both acidic and vicinal hydroxyl groups in the histochemical study of mucins. With revised directions for the colloidal iron stain, the use of Alcian blue 8GX and their combination with the periodic acid-Schiff reaction. *Ann NY Acad Sci* 1963;106:402-23.
- Weber P, Harrison FW, Hof L. The histochemical application of dansylhydrazine as a fluorescent labelling reagent for sialic acid in cellular glycoconjugates. *Histochemistry* 1975;45:271-77.
- Roberts GP. Histochemical detection of sialic acid residues using periodate oxidation. *Histochem J* 1977;9:97-102.
- Klessen C. Demonstration eines Alkali PAS-effektes bei Verwendung von Perjodsäure in niedriger Konzentration. *Histochemistry* 1978;56:299-305.
- Veh RW, Corfield AP, Schauer R, Andrew KH. The bovine submandibular gland II. Histochemical and biochemical results. In: *Proceedings of the fifth international symposium on glycoconjugates*. Stuttgart: Thieme, 1979:G52-3.
- Volz D, Reid PE, Park CM, Owen DA, Dunn WL, Ramey CW. Can "mild" periodate oxidation be used for the specific histochemical identification of sialic acid residues? *Histochem J* 1986;18:579-82.
- Volz D, Reid PE, Park CM, Owen DA, Dunn WL. A new method for the selective periodate oxidation of total tissue sialic acids. *Histochem J* 1987;19:249-56.
- Volz D, Reid PE, Park CM, Owen DA, Dunn WL. Histochemical procedures for the simultaneous visualization of neutralsugars and either sialic acid and its side chain O-acyl variants or O-sulphate ester. I. Methods based upon the selective periodate oxidation of sialic acids. *Histochem J* 1987;19:257-63.
- Park CM, Reid PE, Walker DC, MacPherson BR. A simple practical "swiss roll" method of preparing tissues for paraffin or methacrylate embedding. *J Microsc* 1987;145:115-20.
- Noyes R, Hertig AT, Rock J. Dating the endometrial biopsy. *Fertil Steril* 1950;1:3-25.
- Park CM, Reid PE, Owen DA, Dunn WL. Histochemical studies of epithelial cell glycoproteins in normal rat colon. *Histochem J* 1987;19:546-54.
- Lillie RD, Pizzolato P. Histochemical use of borohydrides as aldehyde blocking reagents. *Stain Technol* 1972;43:13-6.
- Barger JD, DeLamater ED. The use of thionyl chloride in the preparation of Schiff reagent. *Science* 1948;108:121-2.
- Zar JH. *Biostatistical Analysis*. 2nd edition. Englewood Cliffs, New Jersey: Prentice Hall, 1984:138-45.
- Park CM, Reid PE, Owen DA, Sanker JM, Applegarth DA. Morphological and histochemical change in intestinal mucosa in the reserpine-treated rat model of cystic fibrosis. *Exp Mol Pathol* 1987;47:1-12.
- Filipe MI. Transitional mucosa. *Histopathology* 1984;8:707.
- Fordney-Settlage D. A review of cervical mucus and sperm interactions in humans. *Int J Fertil* 1981;26:161-9.

- 18 Chantler E. Structure and function of cervical mucus. In: Chantler E, Elder J, Elstein M, eds. *Mucus in health and disease II*. New York: Plenum Press, 1982:251-63.
- 19 Daunter B. Biochemical and functional structural aspects of human cervical mucin. *Scanning Electron Microscopy* 1984;1:345-58.
- 20 Moghissi KS, Syner FN. Cyclic changes in the amount of sialic acid in cervical mucus. *Int J Fertil Steril* 1976;21:246-50.
- 21 Iacobelli S, Garea N, Angeloni A. Biochemistry of cervical mucus: a comparative analysis of the secretion from preovulatory, postovulatory and pregnancy periods. *Fertil Steril* 1971;22:727-34.
- 22 Van Kooij RJ, Roelofs HJM, Kathmann GAM, Kramer MF. Human cervical mucus and its mucous glycoprotein during the menstrual cycle. *Fertil Steril* 1980;34:226-33.
- 23 Wolf DP, Sokolaski JE, Litt M. Composition and function of human cervical mucus. *Biochim Biophys Acta* 1980;630:545-58.
- 24 Wakefield EA, Wells M. Histochemical study of endocervical glycoproteins throughout the normal menstrual cycle and adjacent to cervical intraepithelial neoplasia. *Int J Gynecol Pathol* 1985;4:230-9.

Requests for reprints to: Dr D A Owen, Department of Anatomical Pathology, Vancouver General Hospital, 855 West 12th Avenue, Vancouver, British Columbia, Canada, V5Z-1M9.