

# Cerebral infection with *Escherichia coli* 0157:H7 in humans and gnotobiotic piglets

S TZIPORI, C W CHOW, H R POWELL

From the Departments of Microbiology and Anatomical Pathology, and the Renal Unit; Royal Children's Hospital, Melbourne, Australia

**SUMMARY** *Escherichia coli* 0157:H7 was isolated from a fatal case of haemorrhagic colitis with haemolytic uraemic syndrome and neurological symptoms. This strain induced diarrhoea and neurological symptoms including incoordination, ataxia, and convulsions in piglets after oral inoculation. Similar neurological signs were seen in piglets inoculated intraperitoneally with bacterial extracts containing a shiga-like toxin that is elaborated by the bacteria. Histological examination of the brains from these piglets showed vascular damage and small infarcts confined to the cerebellum. Comparable lesions were also seen in the brain of the child from whom *E coli* 0157:H7 was isolated. We suggest that the cerebral changes in the piglets and in the patient were caused by the shiga-like toxin elaborated by *E coli* 0157:H7. The shiga-like toxin is thought to cause neurological abnormalities by damage to cerebral blood vessels rather than by a direct effect on the neurones.

Enterohaemorrhagic *Escherichia coli* (as distinct from other enteropathogenic *E coli*), are bacteria that cause haemorrhagic colitis in humans,<sup>1,2</sup> and they have emerged as pathogens of public health importance in the past two to three years in North America and the United Kingdom.<sup>3</sup> The disease is characterised by copious, bloody diarrhoea not accompanied by white cells and mucus in the faeces, or by fever.<sup>1</sup> Recently, several reports of outbreaks of haemolytic uraemic syndrome complicating haemorrhagic colitis or diarrhoea in nursing homes,<sup>4</sup> schools,<sup>5</sup> day care centres,<sup>6</sup> and individual patients,<sup>7</sup> which were attributed to strains of enterohaemorrhagic *E coli*—notably serotype 0157:H7—provided firm evidence linking these strains with the haemolytic uraemic syndrome.

0157:H7 strains isolated from patients with haemorrhagic colitis and haemolytic uraemic syndrome liberate one or two phage encoded cytotoxins active in *vero* or in HeLa cells.<sup>8</sup> One of these toxins, which is neutralised by antibody against Shiga toxin produced by *Shigella dysenteriae* I, is known as Shiga-like toxin I. Many strains elaborate a second equally potent cytotoxin, Shiga-like toxin II, which is not neutralised by antibody to Shiga toxin.<sup>8</sup> Strains of enterohaemorrhagic *E coli* induce diarrhoea and distinct mucosal lesions in the large intestine when fed

to gnotobiotic piglets.<sup>9,10</sup> Neurological abnormalities have also been noted in infected piglets.<sup>11</sup>

This report describes a case of haemorrhagic colitis, haemolytic uraemic syndrome, neurological complications and death in a child. Oral inoculation of gnotobiotic piglets with *E coli* 0157:H7 isolated from this patient provides some evidence that could link the neurological complications in humans and pigs to infection with the organism.

## Case report

A girl aged 20 months was admitted to hospital after three weeks of general ill health and three days of anorexia, lethargy, bloody diarrhoea, vomiting, and abdominal pain. The child had been born at full term by normal vaginal delivery after a normal pregnancy and had had no other illnesses. She was admitted with the provisional diagnosis of bacterial gastroenteritis. Two days after admission she was still passing bloody stools, became anuric, had a brief grand mal seizure, and on haematological examination red blood cell fragmentation and thrombocytopenia were found. During the next 10 days she remained comatose despite intensive treatment including peritoneal dialysis. She developed right sided focal seizures, remained anuric and hypertensive, became oedematous with profound ascites, and continued to lose blood from melaena and haematemesis. She died 11 days after admission with her cerebral state unchan-

ged. Blood cultures were sterile throughout the illness.

At necropsy extensive oedema, pleural and pericardial effusions, ascites, focal haemorrhage into subcutaneous and retroperitoneal soft tissues, and extensive ulceration of the terminal ileum were found. The kidneys showed features of the haemolytic uraemic syndrome with focal cortical necrosis. Many interlobular arteries and arterioles were occluded by thrombosis, and abundant fibrin was present within the walls of the arteries, some of which showed transmural necrosis. Glomerular changes ranged from total and segmental necrosis to pronounced distention of capillary loops by red blood cells.

The brain showed extensive anoxic changes in the cerebral cortex, thalamus, and hippocampus. In addition, small petechiae and focal gliosis were present in the molecular layer of the cerebellar cortex (figure). There was no obvious loss of granular cells or Purkinje cells. The cerebellar changes were unlike those usually associated with generalised anoxia or ischaemia, but were consistent with a disease of small vessels of several days' duration.

Faecal specimens collected during the 11 days in hospital and a rectal swab from an older sibling who had diarrhoea yielded *E coli* that was confirmed serologically and biochemically to be 0157:H7 (strain RCH/86). The plasmid of strain RCH/86 was also shown to hybridise with the enterohaemorrhagic *E coli* probe.<sup>12</sup> Culture fluid of strain RCH/86 induced in HeLa cells cytotoxic changes that were indistinguishable from those caused by Shiga-like toxin of *E coli* 0157:H7 strain 933.<sup>11</sup> The cytotoxicity in HeLa cells was neutralised by Shiga-like toxin rabbit antiserum.

### Experiment

Fourteen newborn gnotobiotic piglets that were derived by caesarian section and maintained inside sterile plastic isolators throughout the experiment were separated into three groups.<sup>13</sup> Six piglets were inoculated orally with 2 ml of about 10<sup>8</sup> organisms of strain RCH/86 grown overnight at 37°C and washed twice to remove traces of toxin. Another group of four piglets were each inoculated intraperitoneally with 1 ml of polymyxin B extracted bacterial lysates with a 6400 TLD50 cytotoxicity for HeLa cells. Four piglets were similarly inoculated with polymyxin B extracted bacterial lysates of *E coli* K-12 with a cytotoxicity titre of less than 10 in HeLa cells.

After inoculation piglets were examined twice daily for 10 days for signs of illness. They were killed by an overdose of barbiturates when they developed diarrhoea or neurological symptoms, or both, which occurred between two and 10 days after inoculation. Control piglets were also killed between two and 10

days after inoculation. Formalin fixed blocks were taken from the small and large intestines, visceral organs, and brains for histological and electron microscopic examination.

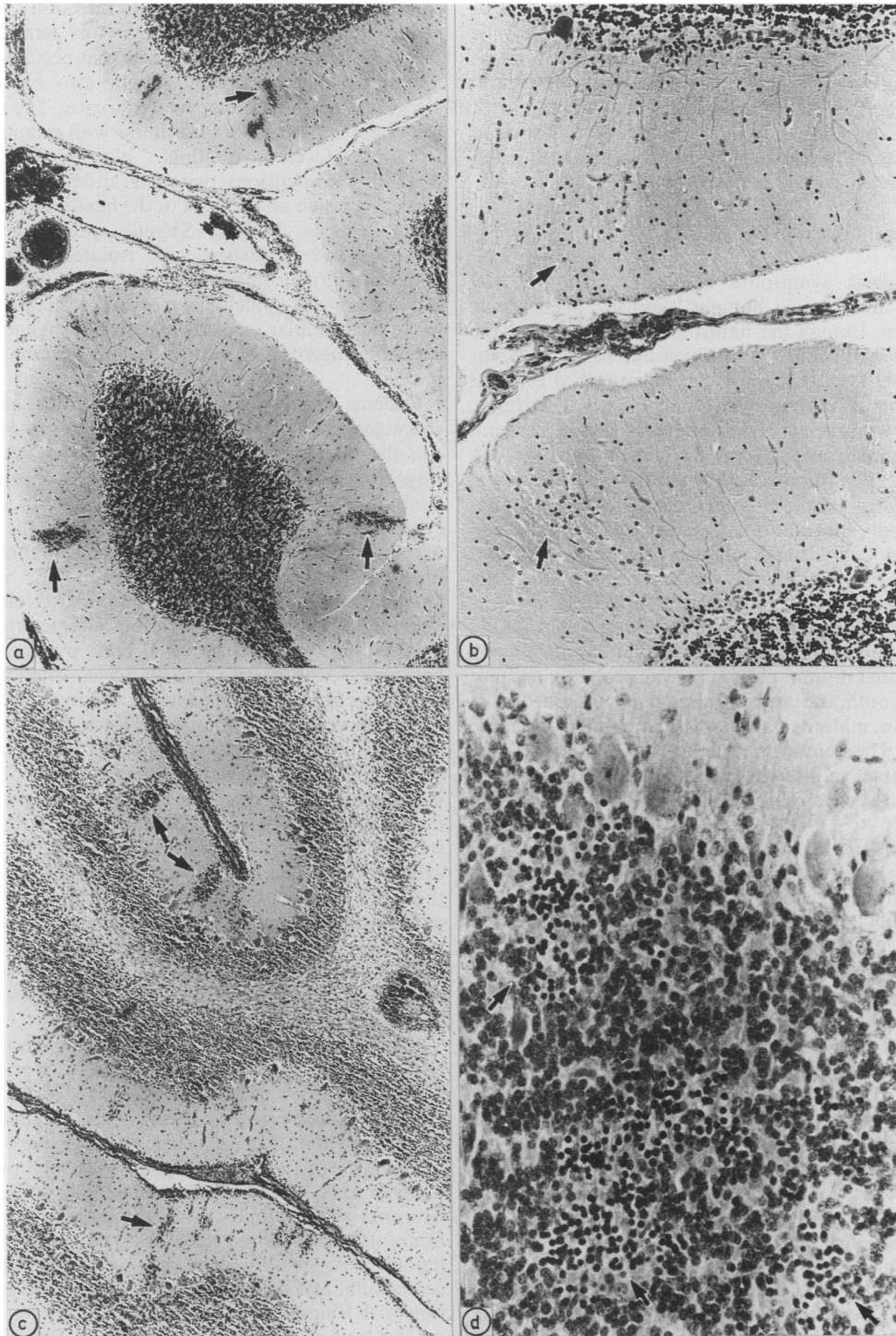
### Results

The six piglets inoculated orally with 0157:H7 strain RCH/86 developed diarrhoea between two and four days after inoculation; they became anorexic, depressed, hunched, and wasted. They were killed between six and 10 days, depending on the severity of the symptoms. Three piglets developed neurological abnormalities on the sixth (two piglets) and seventh day after inoculation. The symptoms included muscular incoordination, staggering gait leading to complete ataxia, paralysis, and recumbency. Ataxic piglets often displayed tremors or convulsions, or both. Once neurological symptoms developed, the piglets deteriorated rapidly and were killed within four to eight hours of onset.

The four piglets inoculated intraperitoneally with polymyxin B extracted bacterial lysates of strain RCH/86 developed similar but more acute symptoms, which appeared between 36 (one piglet) and 72 hours after inoculation. Piglets inoculated intraperitoneally with polymyxin B extracted cultures of *E coli* K-12 remained clinically healthy.

All six piglets inoculated orally with strain RCH/86 developed diarrhoea and showed the characteristic mucosal lesions in the large intestine described previously.<sup>10</sup> These lesions included attachment and effacement of bacteria to the microvillous border, and cellular destruction of surface and glandular epithelium. There was no inflammatory reaction in the mucosa. No such lesions were observed in piglets inoculated intraperitoneally with lysates of RCH/86 or with *E coli* K-12.

The brains from all the piglets were processed for histological examination. Only those with neurological symptoms, irrespective of whether the inoculation was oral or intraperitoneal, had histological changes in the central nervous system; these were confined to the cerebellum. In each case, however, the entire brain appeared oedematous and the leptomeninges covering the cerebellum were congested and more opaque than usual. In piglets that were inoculated orally, numerous petechiae were present mainly in the cortex and most prominently in the molecular layer (figure). The capillaries associated with the haemorrhage often showed pyknosis and karyorrhexis of the endothelial cells. A few capillaries were occluded with fibrin. Bigger vessels showed no abnormality. Small areas of infarction were seen, most easily identified in the internal granular layer (figure), but also to a lesser extent in the adjacent white matter



**Figure** (a) Section of cerebellum showing petechiae in molecular layer from a patient with *E coli* 0157:H7; (b) same patient with focal gliosis in molecular layer; (c) section of cerebellum showing petechiae, mainly in the cortex, of a gnotobiotic piglet that was orally inoculated with the same *E coli* strain isolated from the patient; (d) focal infarction in granular layer with extremely shrunken nuclei in the same piglet (haematoxylin and eosin.)

and molecular layer. There was focal deposition of fibrin in the subarachnoid space.

In the four piglets that were inoculated intraperitoneally, small numbers of petechiae were seen in the cerebellar cortex associated occasionally with pyknosis of endothelial cells. Infarcts were not seen. There was no histological evidence of renal lesions in any of the inoculated piglets.

### Discussion

Neurological symptoms associated with *E coli* 0157:H7 infection in humans<sup>14</sup> and in piglets<sup>11</sup> have been seen, though the nature of the lesions and the probable association with Shiga-like toxin have not previously been studied. We have described cerebral lesions in a patient who had bloody diarrhoea, haemolytic uraemic syndrome and severe cerebral disease which were attributed to infection with *E coli* 0157:H7. The same *E coli* strain induced diarrhoea, neurological symptoms, and cerebral lesions in piglets after oral inoculation. Similar cerebral disease including convulsions, ataxia, incoordination, and paralysis of the hind legs, was also induced in piglets after intraperitoneal inoculation of bacterial extracts containing Shiga-like toxin. Although the gnotobiotic piglets had more acute disease, and clinically deteriorated more rapidly, this was probably because of their youth, the large infecting dose, and the lack of protective maternal antibodies, compared with the patient. The cerebellar changes in the patient were comparable, although the changes seemed more advanced as she survived longer because she was being treated.

Ataxia and ascending paralysis are easily induced in other laboratory animals after intravenous or intraperitoneal inoculation with Shiga-like toxin or Shiga toxin, but not after ingestion, as in piglets and in humans. The development of diarrhoea followed by nervous symptoms in piglets has also been described in a condition known as "oedema disease", which is attributed to several distinct serotypes of *E coli* that elaborate a toxin biologically and antigenically related to Shiga-like toxin II but not Shiga-like toxin I.<sup>15</sup> The infection causes subcutaneous oedema in addition to diarrhoea and nervous symptoms, and usually results in the death of the animal.<sup>16</sup>

Though the part that these toxins play in the pathogenesis of diarrhoea in shigellosis<sup>17</sup> and haemorrhagic colitis<sup>11</sup> remains unclear, there is no doubt that they can be responsible for a number of extragastrointestinal conditions in humans and animals. In addition to their proposed role in the haemolytic uraemic syndrome, and possibly thrombotic thrombocytopenic purpura and oedema disease of swine, their contribution to neurological

complications associated with infection of the gastrointestinal tract is evident. It is tempting to speculate that ekiri, a fatal disease that occurred until the mid 1950s in Japan,<sup>18</sup> might also have been associated with similar or related toxins. The disease was characterised by sudden illness with symptoms of lethargy, fever, vomiting, bloody diarrhoea, irritability, convulsions, twitching, and coma. Oedema was often noted on the back of the hands and feet and of the eyelids. Various *Shigella* species including *S sonnei* and *S flexneri* were isolated from these patients. The neurological symptoms in ekiri (which in Japanese means epidemic dysentery) were attributed to toxic vascular spasm that led to generalised ischaemic necrosis of neurones, and oedema in the brain.<sup>19</sup>

Oedema disease in swine, on the other hand, is characterised by anorexia, subcutaneous oedema, convulsions, muscular incoordination that results in staggering gait leading to ataxia and sudden death. Essentially all symptoms (including neural) can be explained by vascular damage.<sup>16</sup> Changes in the brains of pigs either infected naturally, or experimentally exposed to the bacteria or the toxin, include angiopathy affecting small arteries and arterioles. The angiopathy in its early stages is characterised by swelling of endothelial cells and pyknosis and karyorrhexis of smooth muscle nuclei, often accompanied by fibrinoid degeneration and hyaline change in the tunica media. Pronounced vascular lesions may be difficult to detect in acute disease, particularly in young animals; there is also oedema of the leptomeninges and in the perivascular spaces. In surviving pigs there are signs of focal encephalomalacia in the brain stem together with lesions in small arteries and arterioles. The focal nature of these lesions, which are thought to be due to vascular injury leading to oedema and ischaemia, suggests that ischaemia is probably more important in the genesis of the neurological signs than anoxia itself. Inflammation is not a prominent feature of the angiopathy, nor of the associated oedema at any stage.<sup>16</sup>

Shiga toxin, which has been studied extensively in laboratory animals over many years, was originally considered to be a neurotoxin because of its profound ability to cause neurological symptoms, particularly in mice and rabbits.<sup>20</sup> In each case, however, the damage to the nervous tissue was mediated through primary damage to its blood vessels rather than to primary neuronal injury. Injury to neurones appears many hours after the vascular changes. In monkeys vascular lesions were mainly seen in the cerebral cortex, cerebellum, and basal ganglia after intravenous injection with Shiga toxin.<sup>20</sup> In all these examples, in the patient, and in the gnotobiotic piglets, the common denominators were Shiga and other biologically

related toxins, and neurological signs caused mainly by vascular injury to the central nervous system.

We thank the Veterinary Research Institute, Attwood, Westmeadows, Victoria, for the use of their gnotobiotic facilities; the Royal Children's Hospital Research Foundation for financial support; Marian Batty, Julie Hogg, and Christian Rantzaou for their valuable technical assistance; and Roslyn Gibson for carrying out the DNA hybridisation test.

#### References

- Riley LW, Remis RS, Helgerson SD, *et al.* Hemorrhagic colitis associated with a rare *Escherichia coli* serotype. *N Engl J Med* 1983;308:681-5.
- Smith HR, Gross RJ, Rowe B, Fry NK, Scotland SM. Haemorrhagic colitis and vero-cytotoxin-producing *Escherichia coli* in England and Wales. *Lancet* 1987;ii:1062-5.
- Levine MM. *Escherichia coli* that causes diarrhoea: enterotoxigenic, enteropathogenic, enteroinvasive, enterohemorrhagic, and enteroadherent. *J Infect Dis* 1987;155:377-89.
- Stewart PJ, Desormeaux W, Chene J. Hemorrhagic colitis in a home for the aged: Ontario. *Can Dis Weekly Report* 1983;9:29-32.
- Rogers MF, Budnick LD, Kirson I, *et al.* Hemolytic-uremic syndrome—an outbreak in Sacramento, California. *West J Med* 1986;144:169-73.
- Spike JS, Parsons JE, Nordenberg D, Wells JG, Gunn RA, Blake PA. Hemolytic uremic syndrome and diarrhea associated with *Escherichia coli* 0157:H7 in a day care center. *J Pediatr* 1986;109:287-91.
- Karmali MA, Petric M, Lim C, Fleming PC, Steele BT. *Escherichia coli* cytotoxin, haemolytic-uraemic syndrome, and haemorrhagic colitis. *Lancet* 1983;ii:1299-300.
- Strockbine NA, Marques LRM, Newland JW, Smith HW, Holmes RK, O'Brien AD. Two toxin-converting phages from *Escherichia coli* 0157:H7 strain 933 encode antigenically distinct toxins with similar biologic activities. *Infect Immun* 1986;53:135-40.
- Francis DH, Collins JE, Duimstra JR. Infection of gnotobiotic pigs with an *Escherichia coli* 0157:H7 strain associated with an outbreak of hemorrhagic colitis. *Infect Immun* 1986;51:953-6.
- Tzipori S, Wachsmuth KI, Chapman C, *et al.* Studies on the pathogenesis of hemorrhagic colitis caused by *Escherichia coli* 0157:H7 in gnotobiotic piglets. *J Infect Dis* 1986;154:712-6.
- Tzipori S, Karch H, Wachsmuth KI, *et al.* The role of a 60-Md plasmid and shiga-like-toxins in the pathogenesis of infection caused by enterohemorrhagic *Escherichia coli* 0157:H7 in gnotobiotic piglets. *Infect Immun* 1987;56:3117-25.
- Levine MM, Xu JG, Kaper JB, *et al.* A DNA probe to identify enterohemorrhagic *Escherichia coli* of 0157:H7 and other serotypes that cause hemorrhagic colitis and hemolytic uremic syndrome. *J Infect Dis* 1987;156:175-82.
- Makin TJ, Tzipori S. Inexpensive technique for the production and maintenance of gnotobiotic piglets, calves and lambs. *Aust Vet J* 1980;56:353-8.
- Gransden WR, Damm MAS, Anderson JD, Carter JE, Lior H. Further evidence associating hemolytic uremic syndrome with infection by Verotoxin-producing *Escherichia coli* 0157:H7. *J Infect Dis* 1986;154:522-4.
- Weinstein DL, Marques LRM, Holmes RK, O'Brien AD. Cloning of gene(s) of a newly detected variable of shiga-like toxin II from edema disease-causing *Escherichia coli*. Proceedings of the international symposium on verotoxin producing *Escherichia coli*. 1988: (In press).
- Kurtz HJ, Bergeland ME, Barnes DM. Pathologic changes in edema disease of swine. *Am J Vet Res* 1969;30:791-806.
- Keusch GT, Donohue-Rolfe A, Jacewicz M. Shigella toxin(s): description and role in diarrhoea and dysentery. *Pharmacol Ther* 1981;15:403-38.
- Kobayashi N. Ekiri, an acute encephalopathy associated with dysentery in Japanese children: a review in retrospect. *Acta Paediatr Jpn* 1986;28:651-5.
- Kobayashi N. Histopathology of EKIRI, with special reference to pathogenesis of the neurologic manifestations. *Acta Paediatr Jpn* 1958;1:33-7.
- Cavanagh JB, Howard JG, Whitty JL. The neurotoxin of *Shigella shigae*: a comparative study of the effects produced in various laboratory animals. *Br J Exp Pathol* 1956;37:272-8.

Requests for reprints to Dr Saul Tzipori, Department of Microbiology, Royal Children's Hospital, Parkville 3052, Melbourne, Australia.