

Clinicopathological importance of primary dysplasia of bladder

R J ZUK,* H S ROGERS,† J E MARTIN,* S I BAITHUN*

*From the University Departments of *Morbid Anatomy and †Urology, The London Hospital, Whitechapel, London*

SUMMARY A retrospective study of 15 patients with primary dysplasia of bladder urothelium was performed in an attempt to clarify some of the clinical and histopathological features. The lesion occurs predominantly in middle aged men who present with irritative bladder symptoms with or without haematuria and show no evidence of bacteriological urinary tract infection. Appearances at cystoscopy are non-specific. Thirteen patients showed no progression to carcinoma in situ after a long period of follow up, but primary dysplasia cannot be regarded as an entirely innocuous condition as the remaining two patients did develop carcinoma in situ. The grade of dysplasia on presentation bears no relation to the final outcome. Regular cytological analysis of urine seems to be the best means of follow up, and more active treatment does not seem to be justified.

Over the past 30 years, following early work by Melicow and Hollowel in 1952¹ and Melamed, Voutsas, and Grabstald in 1962,² interest in bladder carcinoma has focused on the early stages of tumour development. These stages included dysplasia (or "atypical hyperplasia")³ and transitional cell carcinoma in situ (CIS). Experimental studies on animals suggest that bladder cancers usually grow slowly through several stages of increasing dysplasia to invasive tumours.⁴

In patients with overt bladder cancer or patients undergoing follow up of previously treated transitional cell carcinoma a complete search of the bladder mucosa often shows that macroscopically normal epithelium is histologically abnormal, with changes varying from minor degrees of dysplasia to CIS.^{5,6} This concomitant or secondary dysplasia or CIS is much more common than that found in the absence of exophytic bladder cancer—that is, primary dysplasia and primary CIS.

Little is known about the clinical presentation, natural history, or incidence of primary dysplasia of the bladder. We performed a retrospective study on patients with this condition in an attempt to assess the features of primary vesical urothelial dysplasia.

Material and methods

Cases of bladder urothelial dysplasia were found in the files of our pathology and urology departments. Forty cases of dysplasia were identified. From this group 25 cases were excluded because the histological features were not those of dysplasia, or the patient had confirmed bladder carcinoma.

Multiple mucosal biopsy specimens had been taken on each of the remaining 15 cases, the histology of which was reviewed by three pathologists without knowledge of the clinical history. Histological features were graded according to the criteria used by Nagy, Frable, and Murphy⁹:

(a) *Mandatory features* degree of change of urothelial polarisation; presence or absence of superficial cells; variation in nuclear size; presence of nuclear crowding; degree of nuclear irregularity; chromatin structure.

(b) *Non-critical features* mitotic activity; prominence of nucleoli; cytoplasmic glycogen; absence or presence of inflammation in the underlying connective tissues.

Using these guidelines the histological material was divided into four groups—mild, moderate, severe dysplasia, and CIS (figs 1 to 4). The clinical histories were then reviewed in the 15 cases, with particular attention paid to age, sex, symptoms on presentation, and the appearance of the bladder mucosa on cystoscopy. Subsequent clinical course, including the

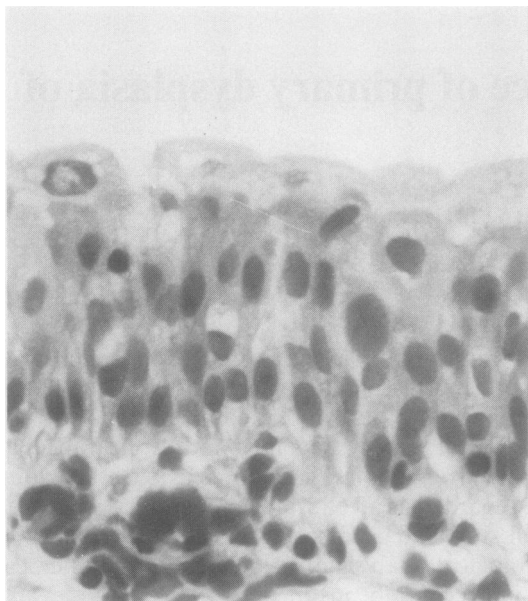


Fig 1 *Mild dysplasia: urothelium shows slight change of polarisation, superficial cells are present, and there is slight enlargement, minimal crowding and slight irregularity of nuclei. Nuclear chromatin is finely granular and evenly distributed. No mitoses are visible. (Haematoxylin and eosin).*

development or not of further urothelial abnormalities and duration of follow up were noted.

Results

AGE AND SEX

There were 11 male and four female patients (ratio 2.75:1). The male patients ranged from 49 to 70 years with a mean of 58.5 years; the female patients ranged from 55 to 66 years with a mean of 60.8 years (table).

CLINICAL HISTORY

Of the 15 patients, four presented with haematuria and the remainder with irritative bladder symptoms. None of the patients had evidence of bacteriological urinary tract infection. In eight patients cystoscopy showed an erythematous bladder mucosa and in the remaining seven the epithelium looked normal. Follow up on all patients was obtained and ranged from two to eight years (mean 4.8 years). Two patients developed CIS with no clinically important change in their symptoms. Two patients went on to develop the clinical syndrome of chronic interstitial cystitis.

PATHOLOGY

All 15 cases were graded using the criteria described.

Eight cases were classified as mild, six as moderate and one as severe dysplasia. All cases were followed up by regular cytological analysis of the urine. Two male patients developed CIS the first three months after presenting with mild dysplasia and the second three years after presenting with severe dysplasia. In both cases the onset of CIS was detected by cytology and confirmed histologically on biopsy. No other patients had positive urine cytology for CIS at any stage and no patients developed papillary or invasive tumours.

Discussion

Little is known of the clinical presentation, biological importance, and incidence of dysplasia of the urothelium. Most information has been gained from patients on follow up for bladder cancer. Dysplastic epithelium is found in selected or random mucosal biopsy specimens from patients with previously resected superficial bladder carcinoma and is also a recognised finding in bladders removed for multifocal carcinoma.^{6,7,10}

In the groups with secondary or concomitant dysplasia most patients are middle-aged men with no evidence of bacteriological urinary tract infection who present with frequency, dysuria, or haematuria, or a

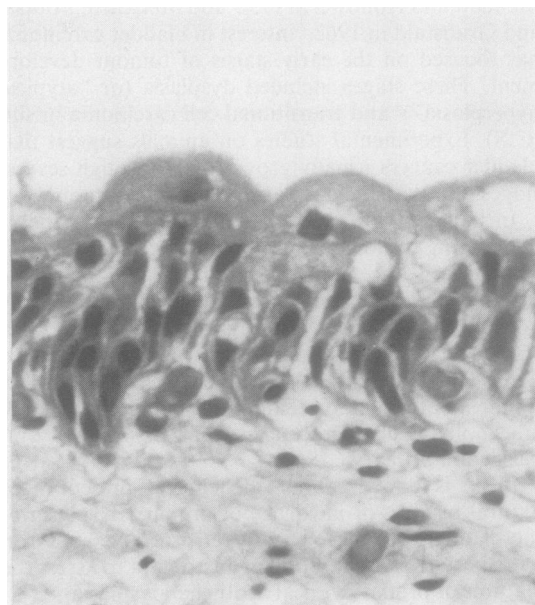


Fig 2 *Moderate dysplasia: urothelium shows changed polarisation. Superficial cells are still present. Nuclear size exhibits more variation, and nuclear crowding and nuclear irregularity are more prominent than in mild dysplasia. Chromatin structure in some nuclei is coarsely granular. (Haematoxylin and eosin).*

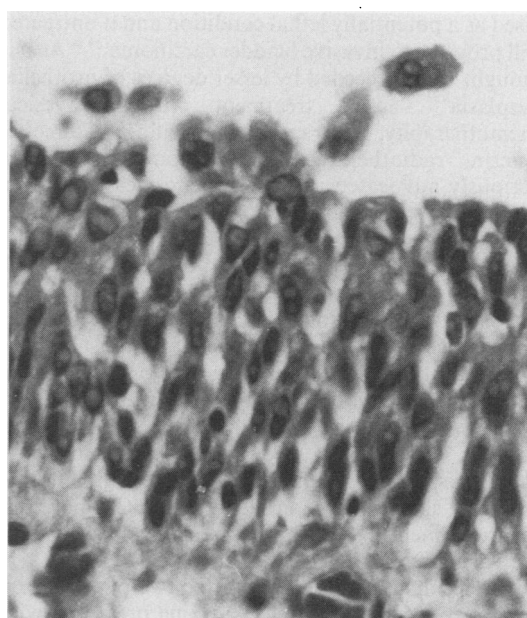
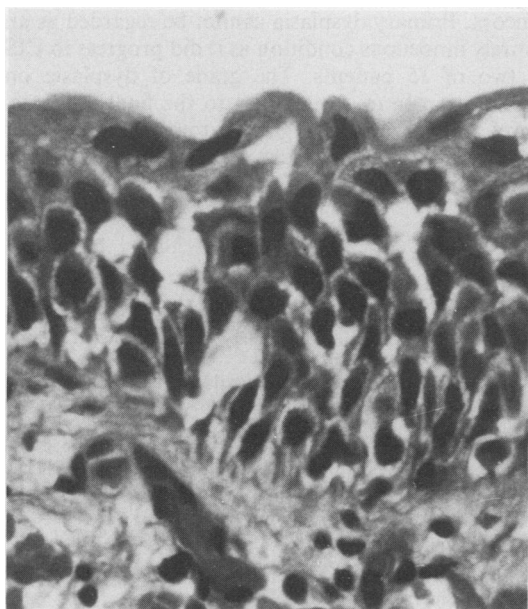


Fig 3 Severe dysplasia: urothelium shows severely changed polarisation. Superficial cells are present but abnormal in appearance. Bizarre nuclei are present with nuclear crowding and prominent nuclear irregularity. Chromatin is coarsely granular and irregularly distributed. (Haematoxylin and eosin).

Fig 4 Carcinoma in situ: there is complete loss of urothelial polarisation. There are no superficial cells. Nuclear size, crowding irregularity, and chromatin structure are the same as visualised in severe dysplasia. (Haematoxylin and eosin).

combination.^{11,12} These findings are similar to ours in that primary dysplasia chiefly affects middle-aged men, most presenting with irritative bladder symptoms but occasionally with haematuria. There was no evidence of bacteriological urinary tract infection in any of the cases but two patients progressed to the clinical syndrome of "chronic interstitial cystitis".

Cytoscopic examination performed on patients with secondary dysplasia usually shows no obvious macroscopic abnormality apart from occasional slightly raised irregular areas of mucosa.¹¹ The cytosopic findings in our study were mostly non-specific, varying from a slightly erythematous to a normal appearing mucosa.

Primary CIS of the bladder is now generally recog-

Table Case details

Case No	Sex/age (year)	History on presentation	Cystoscopy on presentation	Histology on original biopsy	Length of follow up (year)	Details of follow up
1	M 69	Frequency	Erythema	Mild dysplasia	6	Cytology negative
2	M 49	Haematuria	Erythema	Severe dysplasia	—	Developed CIS after three years, detected by urine cytology, confirmed histologically
3	M 51	Frequency; haematuria	Normal	Mild dysplasia	8	Cytology negative
4	M 64	Frequency	Normal	Mild dysplasia	2	Developed chronic interstitial cystitis
5	F 64	Haematuria	Erythema	Mild dysplasia	2	Cytology negative
6	M 57	Frequency; urgency	Erythema	Mild dysplasia	7	Cytology negative
7	M 57	Frequency	Normal	Mild dysplasia	—	Developed CIS after three months, detected by urine cytology, confirmed histologically
8	M 70	Frequency	Normal	Moderate dysplasia	4	Cytology negative
9	F 58	Frequency	Erythema	Moderate dysplasia	3	Cytology negative
10	F 55	Frequency	Normal	Mild dysplasia	3	Cytology negative
11	M 58	Frequency	Normal	Moderate dysplasia	8	Developed chronic interstitial cystitis
12	F 66	Haematuria	Erythema	Mild dysplasia	2	Cytology negative
13	M 58	Frequency	Normal	Moderate dysplasia	3	Cytology negative
14	M 55	Haematuria	Erythema	Moderate dysplasia	8	Cytology negative
15	M 55	Frequency	Erythema	Moderate dysplasia	7	Cytology negative

nised as a potentially lethal condition and if untreated will progress to invasive bladder carcinoma.^{13,14} As it is thought to be preceded by lesser degrees of urothelial dysplasia^{5,14} active treatment with intravesical chemotherapy, intravesical bacillus Calmette-Guerin, radiotherapy or cystectomy have been variously advocated as prophylactic measures when primary dysplasia is found. Our results show that primary dysplasia progressed to CIS in only two cases despite the relatively long period of follow up for all the cases. If all dysplasia ultimately evolves into CIS there must be a long latent interval before its appearance. At this time the best and most reliable follow up procedure is urinary cytology which can determine accurately the appearance of CIS.¹⁵ Definitive diagnosis still depends on histological analysis, however, and cystoscopy with rebiopsy should be performed when cytological examination of the urine shows malignant cells. When CIS develops then treatment by one of the many established techniques in use today is recommended.¹⁶

The results also show that of the two patients who developed CIS during follow up one presented with severe dysplasia and CIS was found three years later; the other presented with mild dysplasia and developed CIS three months later. This would suggest that the grade of dysplasia on presentation bears no relation to the final outcome. It may be argued that in the second case with mild dysplasia an area of CIS was missed on initial biopsy due to sampling error. This seems unlikely as multiple biopsy specimens had been taken on presentation and cytology performed at this time was negative for CIS.

From this study it is impossible to ascertain if (a) dysplastic urothelium can revert back to normal appearances or (b) once initiated the affected urothelium must progress through the stages of mild to moderate, to severe dysplasia, and ultimately to CIS and invasive carcinoma. The numerous detailed studies of cervical intraepithelial neoplasia (CIN) have shown not only that lesser degrees of dysplastic cervical epithelium can revert back to normal without treatment but also that mildly dysplastic cervical epithelium can progress to invasive carcinoma albeit in a very small percentage of patients.^{17,18} Future studies may show that urothelium may behave similarly.

In conclusion, primary dysplasia of bladder urothelium is found predominantly in middle-aged men who present with irritative bladder symptoms with or without haematuria. There is no evidence of concurrent bacteriological urinary tract infection. Cytoscopy shows a normal or slightly erythematous

mucosa. Primary dysplasia cannot be regarded as an entirely innocuous condition as it did progress to CIS in two of 15 patients. The grade of dysplasia on presentation bears no relation to the final outcome. Careful follow up and regular cytological analysis of urine are required to detect CIS, when more active treatment is justified.

References

- Melicow MM, Hollowell JW. Intraurothelial cancer, carcinoma in situ, Bowen's disease of the urinary system: discussion of thirty cases. *J Urol* 1952;**68**:763-72.
- Melamed MR, Voutsas NG, Grabstald H. Natural history and clinical behaviour of in situ carcinoma of the human urinary bladder. *Cancer* 1964;**17**:1522-45.
- Eisenberg RB, Roth RB, Schweinsberg MH. Bladder tumours and associated proliferative mucosal lesions. *J Urol* 1960;**84**:544-50.
- Ito N, Matayoshi K, Arai M, et al. Effect of various factors on induction of urinary bladder tumours in animals by N-butyl-N-(4-hydroxybutyl) nitrosamine. *Gan Jap J Cancer Res* 1973;**64**:151-9.
- Schade ROK, Swinney J. Pre-cancerous changes in bladder epithelium. *Lancet* 1968;**ii**:943-6.
- Koss LG, Tiamson EM, Robbins MA. Mapping cancerous and pre-cancerous bladder changes. *JAMA* 1974;**227**:281-6.
- Farrow GM, Utz DC, Rife CC. Morphological and clinical observations of patients with early bladder cancer treated with total cystectomy. *Cancer Res* 1976;**36**:2495-501.
- Kakizoe T, Matumoto K, Nishio Y, Ohtani M, Kishi K. Significance of carcinoma *in situ* and dysplasia in association with bladder cancer. *J Urol* 1985;**133**:395-8.
- Nagy GK, Frable WJ, Murphy WM. The classification of premalignant urothelial abnormalities: a Delphi study of the National Bladder Cancer Collaborative Group A. *Pathol Annu* 1982;**17**:219-33.
- Soloway MS, Murphy WM, Rao MK, Cox C. Serial multiple-site biopsies in patients with bladder cancer. *J Urol* 1978;**120**:57-9.
- Murphy WM, Soloway MS. Urothelial dysplasia. *J Urol* 1982;**127**:849-54.
- Murphy WM, Soloway MS. Developing carcinoma (dysplasia) of the urinary bladder. *Pathol Annu* 1982;**17**:197-217.
- Utz DC, Farrow GM, Rife CC, Segura JW, Zincke H. Carcinoma in situ of the bladder. *Cancer* 1980;**45**:1842-6.
- Zincke H, Utz DC, Farrow MD. Review of Mayo Clinic experience with carcinoma in situ. *Urology* 1985;**26**: (Suppl 4):39-46.
- Highman WJ. Flat in situ carcinoma of the bladder: cytological examination of urine in diagnosis, follow up, and assessment of response to chemotherapy. *J Clin Pathol* 1988;**41**:540-6.
- Jenkins BJ, England HR, Fowler CG, et al. Chemotherapy for carcinoma in situ of the bladder. *Br J Urol* 1988;**61**:326-9.
- Petersen O. Spontaneous course of cervical precancerous conditions. *Am J Obstet Gynecol* 1956;**72**:1063-71.
- Fox CH. Biologic behaviour of dysplasia and carcinoma in situ. *Am J Obstet Gynecol* 1967;**99**:960-74.

Requests for reprints to: Dr R J Zuk, Department of Morbid Anatomy, The London Hospital, Whitechapel, London E1 1BB, England.