

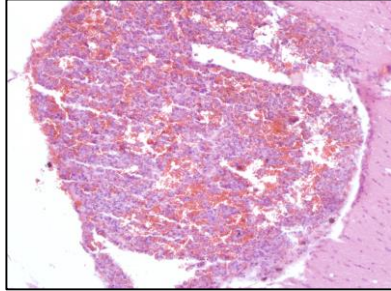
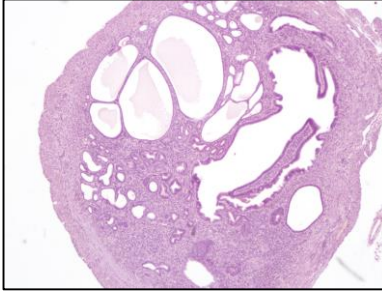
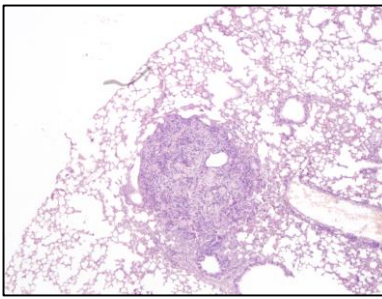
A**B**

Figure S5: Necropsy of mice lacking macroscopic disease.

OvTrpMyc mice were evaluated by necropsy when macroscopic tumors were not immediately observed. **(A)** Dissected brain (top panel) and H&E section of brain tumor (bottom panel). **(B)** Lung metastasis (top panel) and a normal phenotype of some aged mice: cystic uterus (bottom panel).