

## THE OPTIC FORAMEN\*

BY

J. GRAY CLEGG

MANCHESTER

FORTY years ago affections of the optic nerve and the visual tracts were but inadequately understood. In fact, atrophy of the nerve, whether primary or secondary, was regarded almost as an act of God, and therefore unavoidable, and practically irresponsive to treatment. During the subsequent period great progress has been made in knowledge of its aetiology, and consequently in prophylaxis and remedial measures. One of the recent modes of investigation is examination of the optic foramina by Roentgen rays.

The optic foramen or canal can readily be demonstrated in a human skull. It is, on the average, 4-9 mm. in length (Whitnall), but it may be 12 mm. (Onodi). The lumen varies in shape, but is practically oval. It runs between the body and the two roots of the lesser wing of the sphenoid. The direction is down and out, making an angle of  $38^{\circ}$  with the horizontal plane, and  $38^{\circ}$  with the vertical sagittal plane. Considerable variations in length, lumen, thickness and density of its walls, occur.

The anterior opening is oval in outline and measures 5-6 mm. in longer diameter (Pfeiffer); the central part is circular, with an average diameter of 5.5 mm.; the posterior portion is generally considered to be flattened from above downwards.

Great clinical importance is attached to the variable character of the bony walls, which may be 5-7 mm. thick (Stanculeanu), or exceedingly thin, 2 mm.

Michele Del Duca studied ninety crania. He emphasises the influence of the carotid groove in the body of the sphenoid, as it affects the greater or lesser length of the inferior wall.

Anomalies of the sphenoid bone, and of the skull in general, can affect the optic canal, as for instance, the distance between the two internal and intra-cranial orifices are in relation with the existence of brachiocephaly or dolichocephaly. The position of the ophthalmic artery and its grooves is important.

The canal can be examined in the living subject by radiographical processes. The head has to be arranged carefully in the correct position to allow for the radiations to pass parallel to its length; or the lateral aspect can be seen by another adjustment of the rays, head and plate. One method of taking the film is given by Raymond Pfeiffer.

\* Paper read in the Ophthalmic Section at the Annual Meeting of the British Medical Association, Oxford, 1936.

The radiographic image of the optic canal is the resultant of superimposition of the image of the internal and external orifices. The exact size must be calculated from the X-ray plate, allowing for the distance of tube, plate, etc. Its diameters correspond to the smallest diameter of these orifices, and its oval form (horizontal or vertical) or its circular form depends upon the relation of horizontal and vertical axes of external and internal orifices.

The presence of a clino-carotid canal, or of a highly thickened lamina quadrilatera alter the shape and visibility of the image of the canal.

A simplified technique for Roentgenographic examination of the optic canal is given by Camp and Granturco.

Goalwin in 1925 published two articles, viz. :—

“Standardisation of a Roentgen ray tube for the precise Roentgenology of the Optic Canals,” and

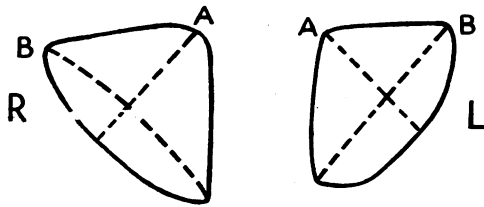
“The precise Roentgenography and measurement of the Optic Canal.”

Frimann-Dahl describes “A new projection for the Roentgenology of the Optic Foramen.” It is said to be simple, rapid and accurate, requires no special apparatus, and eliminates any special adjustment of the tube.

Considerable variations occur in the normal anatomy, and others where the skull is deformed by hydrocephalus or oxycephaly. A thorough knowledge of these variations is necessary in order to interpret the radiograms of truly pathological conditions.

A very good paper by Goalwin, entitled “One Thousand Optic Canals” was written in 1927. Examination was definitely indicated in 253 cases. In all, 23 pathological conditions of the optic canal were demonstrated in 89 of the 253 cases, equal to 35 per cent. The cause of the visual disturbance was found elsewhere in the skull in 126 cases, equal to 50 per cent.

The optic canal attains full lumen at the age of three years. The shape when radiographed approximates a quadrant of a circle. An absolutely circular section is never found in normal canals.



Two diameters are differentiated, viz., A and B.  
A is usually 0.3 mm. less than B.

The average of A is 4.26 mm., and of B 4.49 mm.

The largest normal canals have been observed in cases of tumour of the middle fossa : (R) 4.7 × 7.24 mm. (L) 4.3 × 7 mm.

The largest pathological canal occurred in an optic nerve tumour : the A diameter showed 71 per cent. of increase of measurement, and the B diameter 54 per cent., on the left side, as compared with a normal lumen on the right side.

Only one canal was noted with a diameter of 2.8 mm. without any ophthalmological evidence of optic nerve atrophy. The smallest pathological canal observed had a B diameter of 1.4 mm., due to a hyperostosis.

It is evident that from the clinical point of view the important thing is not the classification of normal foramina, but the recognition of typical shapes associated with various skull deformities and with the various forms of pathological change in the lumen and walls of the canal and adjacent structures.

The conclusions arrived at by Goalwin are as follows :—

1. Discrepancies between sizes and shapes of the canal are due to :—

- (a) Measurement made at different points of a conically shaped canal.
- (b) Observation from varying angles.
- (c) The use of X-ray dimensions without proper deduction.

2. In the series of 253 cases examined for 34 causes, 23 types of pathological change were found in 35 per cent. of cases; in 50 per cent. the cause was found elsewhere in the skull, and in about 7 per cent. the negative diagnosis was of clinical value.

3. Skull deformity with optic nerve symptoms is fully twice as frequent in eye practice as optic nerve tumour.

4. The average shows no appreciable variation depending on sex or racial stock.

The average inclination in normal skulls is 39°, and is the same in the vertical as in the median vertical plane.

5. The average normal canal measures 4.1 by 4.65 mm., with virtually no variation due to age, sex or stock.

6. Absolute symmetry may be expected in 45 per cent. normal skulls; difference of 10 per cent. or less may be expected in about 40 per cent. of normal skulls; and difference of 10 per cent. to 20 per cent. in 14 per cent. of normal skulls.

7. A canal measuring less than 2.8 mm. in one of its diameters cannot contain a normal optic nerve.

8. A classification of normal shapes is not of clinical value because pathological canals present changes in size or structure of their walls, or both.

9. An enlarged circular canal is indicative of optic nerve tumour.

10. Irregularity, erosion or destruction of any wall, or part thereof, is always pathological. Hyperostosis or exostosis is also always pathological.

van der Hoeve states that the first man to take radiograms of the optic canal was Rhese of Königsberg.

van der Hoeve found that enlargement of the optic canal was present in:—

1. Neuro-fibromatosis diffusa of the optic nerve.
2. Glioma of the orbit.
3. Glioma of the chiasma and intra-cranial portions of the optic nerves.
4. Hydrocephalus.

He considered operation justifiable if the optic foramen is compressed by tumours, callus, or haemorrhages; also if the canal is too small. He mentioned methods of operation.

Worms has given indications for, and methods of, surgical interference. He stated that decompressive trephining of the canal is a simple operation, without much risk, holding a worthy place along with older proceedings.

In a paper by Leon E. White, he concludes that pneumatisation about the canal causes distortion and narrowing, thus rendering the optic nerve vulnerable. The size and shape of the canal can be determined by careful radiography. The data, up to the present, indicate that there is a great danger of permanent impairment of vision wherever a severe neuritis occurs in canals abnormally small, while with the same impairment of vision in a normal canal, spontaneous recovery may be expected.

In the chronic conditions, the neuritis is thought to be toxic from some focus, such as teeth or tonsils.

Neuritis, either acute or chronic, in the normal or abnormally large canals, seems to be usually of extra-nasal origin. This, if it proves true, should be of great importance in making a differential diagnosis between intra-cranial, multiple sclerotic, luetic and accessory sinus cases. While it is, of course, possible for any infection to reach the nerve through the circulatory system by bacteriaemia or toxæmia, the writer feels that canals of normal size are not specially vulnerable, and that either local treatment or the removal of some definite focus of infection is the more advisable method, rather than ventilation of the sinuses.

In White's opinion a canal of 4 mm. or less in a case of severe optic nerve involvement indicates the necessity for immediate ventilation of the posterior sinuses to prevent permanent atrophy unless some other definite focus can be found. A 4.5 mm. canal gives greater leisure for study and investigation, for optic atrophy

is less to be feared. A 5 mm. canal would probably recover from almost any acute attack, either spontaneously or under local treatment. Further, if some remote focus of infection is found (diseased teeth or tonsils for instance), it should be removed to prevent recurrence.

H. K. Taylor practically confirms the view that a contracted canal warrants early surgical interference.

Lysholm and Olivecrona state that changes of the canals are described in cases of gliomata of the optic chiasma, supra-sellar cholesteatomata and pituitary adenomata. In gliomata of the chiasma and supra-sellar cholesteatomata the changes consist in the widening of one or both optic canals, and widening of the sulcus chiasmatis, while the sella remains essentially normal. In pituitary adenomata destruction of the walls of the canals, together with the destruction of the sella and the clivus was observed. Their paper is very interesting, and is illustrated by numerous X-ray appearances.

Leon White comes to the following conclusions: Extensive pneumatisation about the canal is usually associated with narrowing. When the lesser wing is more pneumatised the canal is flattened on top. If the region below is pneumatised it becomes oval, rarely triangular. Any irregularity of contour of the optic canal, from whatever cause, produces a diminution in calibre, and renders its contents more susceptible to infections from surrounding sinuses. Incorrect conclusions may be drawn from faulty X-ray films. The image of the canal should always appear in the radiogram in the lower outer quadrant of the orbit. If the canal is large, one must look elsewhere for the causes of amblyopia.

Leon E. White has stated that in a series of X-ray films it was found that patients with optic nerve disturbance had abnormally small canals. By analysing 36 cases of optic nerve involvement, it was found that in the smaller canals the vision in 50 per cent. was permanently impaired, while in patients with larger canals the percentage was much less. In 37 cases of optic atrophy studied, nasal infection was responsible for atrophy in 12 out of 124 optic canals, *i.e.*, 10 per cent.

Raised intra-cranial tension seemed to be responsible for abnormally large canals, as intra-cranial lesions were found in all.

Atrophy of the optic nerve in infancy is not responsible for very small canals. While it is possible to enlarge the canal surgically, cases are rarely seen at the stage when it would be beneficial. Leon White confirmed the view that the chance of permanent loss of vision is markedly increased whenever any process capable of producing atrophy occurs in abnormally small canals. As the foramina approach normal size they rapidly reduce the menace to their neural content although optic atrophy may occur in canals of all sizes.

Goalwin, in a paper entitled "The profile Roentgenogram of the Optic Canal," summarises as follows:—

1. A profile X-ray of the optic canal is a view taken at right angles to its axis, in contradistinction to cross section.
2. True profile is not obtainable at same time as true profile of sella turcica.
3. A true profile X-ray is obtained by placing the patient's head on a horizontal plate in a special position.
4. On a typical profile X-ray of the optic canal, the roof, anterior clinoid processes and bridge which separates the canal from the sphenoidal fissure can be identified.
5. Profile view is of value in determining the length and other normal and pathological details, transverse of section, hyperostosis, etc.
6. The peculiar shape of the sella turcica found by Martin and Cushing in tumour of the chiasma and intra-cranial portion of the optic nerve is not due to enlargement of the canal, nor to destruction of bridge between the optic canal and sphenoidal fissure.
7. A long canal is unfavourable in presence of pathology in it, particularly if the section is small.

In another paper Goalwin maintains that the clinical value of radiology of the optic foramina holds in cases of:—

1. Optic neuritis, retrobulbar neuritis, choked disc, optic atrophy, etc.
2. Sphenoidal disease, with or without optic nerve symptoms.
3. Orbital, ocular or optic nerve tumours.
4. Known or suspected fracture of the skull, whether recent or healed.
5. Foreign body in orbit.
6. Skull deformity with visual disturbances.
7. Tumours of anterior and middle fossa.
8. Certain general diseases, like Paget's disease, acromegaly, rickets, etc.
9. Cases of tuberculosis with optic nerve symptoms.
10. Medico-legal cases where loss of sight is alleged to have been caused by injury.

A man aged 25 years, recently under my care at the Manchester Royal Eye Hospital, has optic discs which are extremely pale; the visual acuity is (R) 6/60, as a blotch, J.16, and (L) 6/60, as a blotch, J.16; and he has a large central scotoma for white in each field. The foramina measure (R) 3 mm., and (L) 4 mm. They are the smallest seen so far by Mr. G. Jefferson and myself. The radiogram was taken at the Manchester Royal Infirmary.

In my opinion careful and accurate radiography should be carried out in all cases of affections of the optic nerves. Positive

evidence of variations in the lumen and in the state of the walls of the optic foramina is of considerable help, but negative findings are also of much service in diagnosis and treatment.

## BIBLIOGRAPHY

1. Pfeiffer.—New Technique of Roentgenology of the Optic Canals. *Amer. Jl. of Roentg.*, March, 1933.
2. Michele Del Duca.—*Rivista Oto-Neuro-Oftal.*, 1929.
3. Camp and Granturco.—A Simplified Technique for Roentgenographic Examination of the Optic Canal. *Amer. Jl. of Roentg.*, April, 1933.
4. Goalwin.—Standardisation of a Roentgen Ray tube for the precise Roentgenology of the Optic Canals. *Amer. Jl. of Roentg.*, 1925.
5. ——— The precise Roentgenography and Measurement of the Optic Canal. *Amer. Jl. of Roentg.*, 1925.
6. Frimann-Dahl.—A new Projection for the Roentgenology of the Optic Foramen. *Acta Radiol.*, 1933.
7. Goalwin.—One Thousand Optic Canals. *Jl. of Amer. Med. Assoc.*, June-December, 1927.
8. van der Hoeve.—Radiographie du Trou Optique. *Bull. et Mem. de la Soc. Franc. d'Ophtal.*, Vol. XXXVIII, p. 689, 1925.
9. Worms.—Le Trepanation decompressive du Canal Optique. *Bull. et Mem. de la Soc. Franc. d'Ophtal.*, Vol. XLIII, p. 417, 1930.
10. H. K. Taylor.—Roentgen findings of Optic Canals in Blindness due to Nasal Accessory Sinuses. *New York State Jl. of Med.*, December, 1926.
11. Lysholm and Olivecrona.—On changes of the Optic Canals in cases of Intracranial Tumour. *Acta Chir.Scand.*, Vol. LXXII, p. 192, 1932.
12. Leon E. White.—Treatment of Optic Nerve involvement as determined by Optic Canal Radiographs. *Amer. Acad. of Ophthal. and Oto-laryng.*, p. 20, 1923.
13. ——— An Anatomical and X-ray Study of the Optic Canal in case of Optic Nerve Involvement. *Boston Med. and Surg. Jl.*, Vol. CLXXXIX, p. 741, 1923.
14. ——— The Optic Canal in Optic Atrophy. *Boston Med. and Surg. Jl.*, Vol. CXCIII, p. 771, 1925.
15. Goalwin.—The profile Roentgengram of the Optic Canal. *Amer. Jl. of Roentg.*, 1927.
16. Hartmann.—*La Radiographie en Ophtalmologie.* Masson et Cie., 1936.
17. B. J. Farberov.—Ueber den klinischen Wert einer Roentgensuchung der Foramen Opticum. June, 1936.
18. Jefferson, Geoffrey.—The value of Radiology in Neuro-surgery. *Proc. Roy. Soc. Med.*, July, 1936.

---

## INDUSTRIAL EYE INJURIES AND THEIR PREVENTION

BY

JOSEPH MINTON

LONDON

THIS contribution is based on a study of patients who attended the casualty department of the Royal Eye Hospital, St. George's Circus, London. The hospital, situated in a highly industrialized area, is the only eye hospital south of the river. In the year 1935, 10,786 patients attended the casualty department of whom