

inhibition with 30 µg disc) and they appear to form a distinct subgroup. We have tested 46 such organisms: they do not grow at 25°C, but most grow freely at 45°C, are relatively salt-tolerant, and produce coccoid forms in cultures much earlier than with most *jejuni* strains. We have isolated them commonly from locally caught seagulls, but also occasionally from other animals and man. Thus the nalidixic acid sensitivity test is a useful adjunct to the 25°C test, but it is not infallible.

We, too, have found that while all *jejuni* group organisms grow freely at 42°C, a few isolates of what are ostensibly subsp. *intestinalis* (25°C positive and with typical morphology) do manage to grow at this temperature. Such strains, which were mostly isolated from bovine faeces, have generally produced more H<sub>2</sub>S than orthodox *intestinalis* strains, notably in iron-containing medium. Of course, one has to be careful in performing tests near the upper limit of temperature tolerance; the cut-off point is sharp, and unless the temperature is accurately controlled results will be variable. We hope to publish a full account of our studies shortly.

MB SKIRROW  
J BENJAMIN  
Worcester Royal Infirmary,  
Castle Street Branch,  
Worcester  
WRI 3AS

#### 'Ultra-fast' alkaline phosphatase isoenzyme

Koett and colleagues, in your December 1979 issue, requested investigators to report their experience (if any) of 'ultra-fast' alkaline phosphatase isoenzyme in serum with substrates other than the alpha naphthol ASM-X phosphate they used. Over the past 10 years I have used cellulose acetate electrophoresis (on Sephadex III) and indoxyl phosphate substrate to examine alkaline phosphatase isoenzyme patterns in more than a thousand serum specimens with raised total alkaline phosphatase activity. I have never demonstrated 'ultra-fast' alkaline phosphatase of albumin mobility in any of these samples.

SIDNEY B ROSALKI  
The Royal Free Hospital,  
Pond Street,  
Hampstead,  
London NW3 2QG

#### Staphylococcal enterocolitis and inflammatory bowel disease

We were interested by the articles of Willoughby *et al.* and Price *et al.* (Volume 32, page 986 and page 990 respectively). We are also studying the role of rectal biopsy in the diagnosis of acute colitis and have encountered two patients with infective colitis who are of particular interest.

##### Patient 1

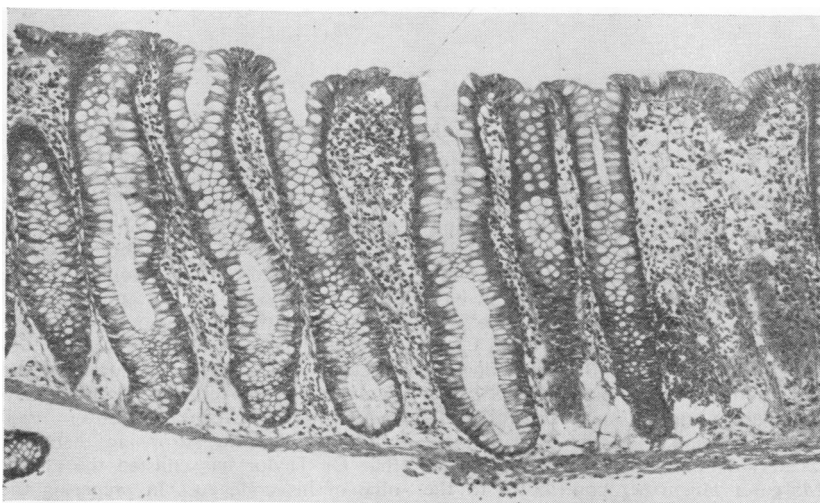
A 55-year-old housewife was well and on no medication until February 1976 when she had a sudden onset of severe watery diarrhoea associated with flu-like symptoms. At the time she attributed her symptoms to the ingestion of a pork pie 2-3 hours before the onset of her illness. Her GP prescribed cotrimoxazole and kaolin to no effect, and she was admitted three weeks later to an infectious diseases hospital for investigation. On admission she was unwell and pyrexial. The abdomen was distended but there was no tenderness. Investigations revealed Hb 11.8 g/dl, WBC 12.0 × 10<sup>9</sup>/l (82% neutrophils), ESR 50. Stool cultures showed *Staphylococcus aureus* +++ (ie, massive overgrowth of staphylococcus with relative absence of the normal Gram-negative enteric flora) (GL Gibson—personal communication). The organism was resistant to penicillin and ampicillin but sensitive to tetracycline, cotrimoxazole, cloxacillin, lincomycin, fucidin, and erythromycin. No other pathogens were detected on routine culture although *Clostridium difficile* and pathogenic *Escherichia coli* were not sought. Ten days after admission she was transferred to this hospital where investigations showed the serum albumin was low at 30.3 g/l. Sigmoidoscopy was normal and rectal biopsy revealed a mild acute proctitis compatible with an infective aetiology.<sup>1,2</sup> Barium enema revealed severe ulceration of the whole colon but with rectal sparing. A small bowel meal was normal. She was treated with steroids and intravenous hyperalimentation (IVH) and improved rapidly and was discharged after 18 days. She has since had no further bowel symptoms and sigmoidoscopy, rectal biopsy, and barium enema nearly three years after her acute illness were normal.

##### Patient 2

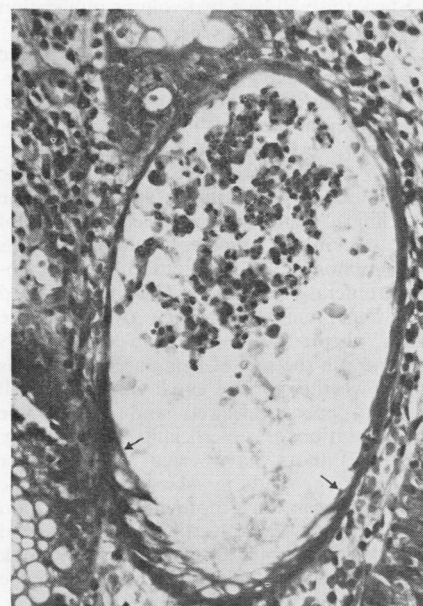A 25-year-old male factory worker, who was on no medication, presented in May

1978 with a three-week history of watery diarrhoea of sudden onset, fever, and weight loss. His GP had prescribed sulphasalazine, 3 g/day, to no effect and he was admitted. On examination he was toxic with a temperature of 39°C. Sigmoidoscopy revealed no mucosal abnormality. Stool taken at sigmoidoscopy and plated immediately on to blood agar showed a massive overgrowth of staphylococci with almost complete absence of normal enteric flora. This finding was subsequently confirmed in stool samples sent to the routine laboratory, and the organism was identified as *Staph. aureus* resistant to penicillin but sensitive to tetracycline, erythromycin, fucidin, clindamycin, gentamicin, and cloxacillin. A search for other routine faecal pathogens, including *Campylobacter* species, was negative. *Cl. difficile* and its toxin were not sought. In addition, no pathogenic *E. coli* were found in a faecal sample obtained five days after admission, by which time the flora had apparently returned to normal. Other investigations showed Hb 13.2 g/l, WBC 7.6 × 10<sup>9</sup>/l (78% neutrophils with a toxic shift and 2% myelocytes). The ESR was 46 mm/h. Plasma albumin was low at 33.5 g/l. Barium enema showed gross colonic ulceration with rectal sparing similar to that of patient 1. A small bowel meal was normal. Rectal biopsy (Fig. 1a and 1b) showed characteristic changes of infective colitis.<sup>1,2</sup> He was treated with steroids and IVH and showed dramatic improvement; he was discharged 18 days after admission. Six months after discharge from hospital he suffered a further attack of diarrhoea necessitating treatment with steroids. Sigmoidoscopy during this second attack showed minimal erythema only but a barium enema showed continuing ulceration in the descending and transverse colon. Faecal bacteriology was not performed on this occasion.

These patients are of interest for three reasons. Firstly, the bacteriological findings strongly suggest the diagnosis of staphylococcal enterocolitis. A massive overgrowth of staphylococci in the faeces to the exclusion of the normal enteric flora is uncommon and probably diagnostic of staphylococcal enterocolitis.<sup>3</sup> These cases appear to be highly unusual since we have been unable to find similar reports in the literature. They do suggest, however, that staphylococcal enterocolitis may occur in previously healthy individuals who are not on antimicrobials. This suggestion is supported both by the observation that staphylococci have been recovered from



(a)



(b)

Fig. 1(a) Patient 2. Rectal biopsy showing a normal glandular pattern and only a minor degree of mucin depletion maximal at the surface. The lamina propria contains a moderately heavy polymorphonuclear cell infiltrate and slightly increased numbers of mononuclear cells. Haematoxylin and eosin  $\times 374$ .  
 (b) Patient 2. A 'mucoid' crypt abscess in which crypt dilatation is associated with atrophy and degeneration of epithelial cells involving much of its lining but showing preservation of mucin vacuoles in the epithelium between the arrows. H and E  $\times 1484$ .

the stomach of a patient dying of staphylococcal food poisoning<sup>4</sup> and by a report from elsewhere implicating staphylococcal enterocolitis as a frequent cause of diarrhoea and not always in patients who had received antimicrobials.<sup>5</sup> The source of infection in these patients is unknown although a pork pie was implicated by the first. Neither patient was aware of others

suffering similarly so epidemiological evidence is lacking.

Secondly, these patients confirm that typical changes may be found in the rectal biopsies of patients with infective diarrhoea as described by Price *et al.* and others.<sup>1,2</sup>

Thirdly, they provide further evidence for a possible relationship between

infective episodes and the development of chronic inflammatory bowel disease. Although to our knowledge this has never been demonstrated in patients with staphylococcal enterocolitis chronic disease has been shown to follow acute pseudomembranous colitis of non-staphylococcal aetiology.<sup>6</sup>

We think these patients demonstrate the need for careful bacteriology in all patients presenting with acute colitis. Staphylococci are easily overlooked in the routine screening of faecal samples for enteric pathogens,<sup>7</sup> and the routine use of either blood or salt agar, both of which are satisfactory for the isolation of faecal staphylococci,<sup>3</sup> appears indicated in the analysis of faeces from patients with acute colitis. Thus other cases of staphylococcal enterocolitis might be discovered and more might be learned about the aetiology of chronic inflammatory bowel disease.

RJ DICKINSON

MF DIXON

ATR AXON

Gastroenterology Unit,  
 The General Infirmary,  
 Leeds LS1 3EX

## References

- Day DW, Mandal BK, Morson BC. The rectal biopsy appearances in Salmonella colitis. *Histopathology* 1978;**2**:117-31.
- Dickinson RJ, Gilmour HM, McClelland DBL. Rectal biopsy in patients presenting to an infectious disease unit with diarrhoeal disease. *Gut* 1979;**20**:141-8.
- Hinton NA, Taggart JG, Orr JH. The significance of the isolation of coagulase-positive staphylococci from stool. *Am J Clin Path* 1960;**33**:505-10.
- News and Notes: Epidemiology. Staphylococcal food poisoning in summer. *Brit Med J* 1976;**2**:376.
- Kelemen L, Keresztély J, Csösz IK, *et al.* Some data on the epidemiology and clinical aspects of acute enterocolitis of staphylococcal origin. (Rumanian.) *Medicina Interna (Bucarest)* 1974;**26**: 717-22.
- Goodacre RL, Hamilton JD, Mullens JE, Qizilbash A. Persistence of proctitis in two cases of clindamycin-associated colitis. *Gastroenterology* 1977;**72**:149-52.
- Altemeyer WA, Hummel RP, Hill EO. Staphylococcal enterocolitis following antibiotic therapy. *Ann Surg* 1963; **157**:847-58.