

requires extra time for cells to settle before readings are made.

In our hands, this equipment has proved reliable and simple to use, and recordings have been reproducible and free from the bias detected in results derived from human observation.

Although the Multiskan Plate Reader was designed for enzyme-linked immunosorbent assay, its role in reading CF tests in the manner described above has proved satisfactory, and it is possible that it will prove satisfactory for other types of serological tests also. It has the advantage that it reads the microtitre plates directly, thus avoiding the need for transfer of the well contents to cuvettes. The plate reader has a facility for computer linkage, and a fully automated system of serological testing and reporting could be developed.

We are indebted to Mrs Sheila Holt and Miss Susan Jordan for technical assistance. We also wish to thank Flow Laboratories for the use of the plate reader.

References

- ¹ Bradstreet PCM, Taylor CED. Technique of complement-fixation test applicable to the diagnosis of virus diseases. *Monthly Bulletin of the Ministry of Health and Public Health Laboratory Service* 1962;21:96-104.
- ² Spencely M, Parker MJ, Dewar RAD, Miller DL. The clinical value of microbiological laboratory investigations. *J Infection* 1979;1:23-36.

Requests for reprints to: Dr DA McSwiggan, Public Health Laboratory, Central Middlesex Hospital, Park Royal, London NW10 7NS, UK.

Influence of clearing agent on immunohistochemical staining of paraffin-embedded tissue

JB MATTHEWS *Immunology Laboratory, Department of Oral Pathology, University of Birmingham B15 2TJ, UK*

It is well recognised that fixation is an important factor in the determination of immunoreactivity of antigens in paraffin-embedded tissues.¹⁻⁴ The effect of subsequent tissue processing has rarely been studied^{5,6} and the ethanol-chloroform schedule appears to be the 'routine method' when details are available.^{7,8} Many laboratories use xylene as their routine clearing agent, which has been shown to have an extracting quality on cell cytoplasm as seen ultrastructurally⁹ and to decrease immunoreactivity of frozen sections.⁶ This paper describes a study to determine the effect of different clearing agents on subsequent immunoreactivity of fixed and embedded tissue.

Material and methods

Slices of palatine tonsil 2-3 mm thick were fixed for 4 or 22 hours at room temperature in the fixatives listed (Table), processed via ethanol (12 hours) and xylene, chloroform or Inhibisol (methyl chloroform containing a patented inhibitor—Bestobell Chemical Products Ltd, Mitcham, Surrey)¹² at room temperature (10 hours) and waxed at 60° (3 hours); 5 μ sections were mounted on clean, adhesive-free slides and dried at 56° for 2 hours. Before immunostaining, sections were dewaxed in xylene (3 \times 1 min) and rehydrated through 74 OP ethanol (3 \times 1 min) and 64 OP ethanol (1 \times 2 min) to 0.05 M Tris-HCl buffered saline, pH 7.6 (TBS), which was used for trypsinisation and reagent dilution.

B-5 fixed sections were treated with Lugol's iodine (5 minutes) and sodium thiosulphate (0.2 M, 5 minutes) after the diaminobenzidine reaction and before counterstaining. Removal of picric acid by pretreatment of Bouin's fixed tissue with lithium carbonate (saturated solution in 70% ethanol, 2 minutes) did not affect immunoreactivity.

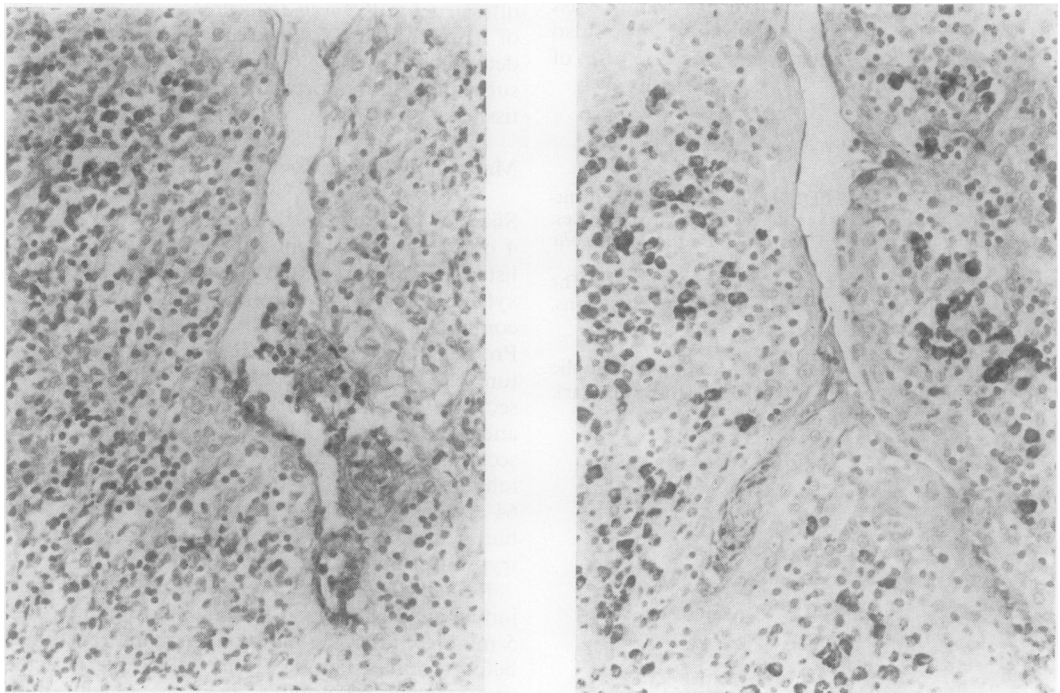
The unlabelled antibody enzyme method (PAP) was performed with and without prior trypsinisation of sections, essentially as described by Curran and Gregory¹³ except that digestion was carried out at room temperature and endogenous peroxidase activity was blocked with 0.3% hydrogen peroxide

Effect of clearing agent on PAP staining of plasma cells for IgG, with and without trypsin pretreatment, in tissue fixed for 22 hours using a primary antiserum dilution of 1:1000

Fixative*	No trypsin			Trypsin
	Tissue processed via ethanol and: Xylene	Chloroform	Inhibisol	Xylene, chloroform, or Inhibisol
Neutral buffered formalin	+(1)	+(2)	+(2)	+++ (4)
Formol calcium (pH 4)	+(1)	++ (3)	++ (3)	+++ (4)
Formol calcium (pH 7)	+(1)	++ (3)	++ (3)	+++ (4)
Formol saline	+(1)	++ (2)	++ (2)	+++ (4)
B-5 (sodium acetate buffered formol sublimate)	+++ (2)	+++ (3)	+++ (3)	+++ (3)
Helly's fluid	+++ (1)	+++ (2)	+++ (2)	+++ (2)
Bouin's fluid	+(1)	++ (3)	++ (3)	++ (3)
Zenker's acetic	++ (2)	++ (2)	++ (2)	+(2)
Heidenhain's susa	++ (1)	++ (1)	++ (1)	++ (3)

*Fixatives prepared as described by Culling¹⁰ except B-5.¹¹

+ few positive cells; ++ moderate numbers of cells; +++ many cells. Numbers in parentheses indicate staining intensity: 1, light; 2, medium; 3, dark brown; 4, black.



PAP staining for IgG of non-trypsinised formol calcium (pH 4, 22 hours) fixed tonsil processed via (a) xylene and (b) Inhibisol. $\times 250$.

in methanol (30 minutes). The dilutions and times for each antiserum overlay were as follows: rabbit anti human IgG (1:200 or 1:1000) 60 minutes; swine anti rabbit Ig (1:50) 30 minutes; PAP complex (1:50) 30 minutes. Controls included omission of the primary and secondary layers, replacement of

primary antiserum with normal rabbit serum plus specific inhibition by preincubation of antihuman IgG with purified human IgG. Reagents were obtained from Dakopatts AS, Denmark.

Results were assessed without prior knowledge of tissue section treatment separately by two observers.

The complex staining patterns resulting from differences in fixative, fixation time, and antiserum dilution will be reported elsewhere, and the results presented deal only with the effects of clearing agent.

Results

The results are summarised in the Table. The numbers of positive cells and the intensity of the staining reaction of non-trypsinised formol calcium, formol saline, and Bouin's fixed tissues were improved if chloroform or Inhibisol, instead of xylene, were used in tissue processing (Figure). Similarly, the intensity of plasma cell staining in neutral formalin, B-5, and Helly's fixed tissues was improved without any obvious increase in the number of positive cells. The immunoreactivity of tissues fixed in Zenker's and Heidenhain's susa was not affected by clearing agent. Background staining was generally similar for a given fixative, irrespective of clearing agent, except for B-5 fixed tissue which had decreased background with chloroform or Inhibisol. Immunoreactivity of trypsinised sections was unaffected by clearing agent although staining of formalin-fixed tissues was improved by the digestion step, as previously reported.^{13,14} The effect of clearing agent, but not fixative, was independent of fixation time (4 or 22 hours) or the dilution of primary antiserum (1:200 or 1:1000), and similar effects attributable to clearing agent were found by both PAP and direct immunofluorescence techniques for the other immunoglobulin classes, K and λ light chains, and muramidase.

Discussion

These results indicate that xylene processing is deleterious to the immunoreactivity of tissue antigens and that the choice of clearing agent may be an important factor determining the ability to stain non-trypsinised sections of formalin-fixed, paraffin-embedded tissue. Recently, formol sublimate has been shown to be superior to routine fixatives¹⁻⁴ in the preservation of tissue antigens after 'routine' processing. In this study, xylene impaired the reactivity of plasma cells and increased specific background staining of acetate-buffered formol sublimate (B-5) fixed tissues, indicating that chloroform or Inhibisol are the preferred clearing agents for this fixative.

Since the original description by Brozman and Brozmanova in 1966,¹⁵ many workers have recently advocated the use of trypsin to reveal antigens in formalin-fixed, paraffin-embedded tissue.^{6,13,14} It is interesting to note that the impairment of tissue immunoreactivity produced by xylene is nullified by

trypsin digestion and may, in part, explain the revival of this technique.

I wish to thank Mr MK Basu and Dr HF Sewell for help and encouragement and Mrs Jackie Buller, Miss Sue Finney, and Mr J Duncombe for section cutting.

References

- Bosman FT, Lindeman J, Kuiper G, van der Wal A, Kreunig J. The influence of fixation on the immunoperoxidase staining of plasma cells in paraffin sections of intestinal biopsy specimens. *Histochemistry* 1977;**53**: 57-62.
- Heyderman E. Immunoperoxidase techniques in histopathology: applications, methods and controls. *J Clin Pathol* 1979;**32**:971-8.
- Banks PM. Diagnostic application of an immunoperoxidase method in hematopathology. *J Histochem Cytochem* 1979;**27**:1192-4.
- Piris J, Thomas ND. A quantitative study of the influence of fixation on immunoperoxidase staining of rectal mucosal plasma cells. *J Clin Pathol* 1980;**33**:361-4.
- Burns J, Hambridge M, Taylor CR. Intracellular immunoglobulins. A comparative study on three standard tissue processing methods using horseradish peroxidase and fluorochrome conjugates. *J Clin Pathol* 1974;**27**:548-57.
- Qualman SJ, Keren DF. Immunofluorescence of deparaffinised, trypsin-treated renal tissue. Preservation of antigens as an adjunct to diagnosis of disease. *Lab Invest* 1979;**41**:483-9.
- Taylor CR, Burns J. The demonstration of plasma cells and other immunoglobulin containing cells in formalin-fixed paraffin embedded tissues using peroxidase-labelled antibody. *J Clin Pathol* 1974;**27**:14-20.
- Curran RC, Jones EL. Immunoglobulin-containing cells in human tonsils as demonstrated by immunohistochemistry. *Clin Exp Immunol* 1977;**28**:103-15.
- Zeitoun P, Lehy T. Utilization of paraffin embedded material for electron microscopy; a study of an A_2 -cell type microadenoma of the endocrine pancreas. *Lab Invest* 1970;**23**:52-7.
- Culling CFA. *Handbook of Histopathological and Histochemical Techniques*. 3rd ed. Butterworths, 1974.
- Lillie RD. *Histopathologic Technic and Practical Histochemistry*. 3rd ed. McGraw-Hill, 1965.
- Maxwell MH. Safer substitutes for xylene and propylene oxide in histology, haematology and electron microscopy. *Med Lab Sci* 1978;**35**:401-3.
- Curran RC, Gregory J. Demonstration of immunoglobulin in cryostat and paraffin sections of human tonsil by immunofluorescence and immunoperoxidase techniques. Effects of processing on immunohistochemical performance of tissues and on the use of proteolytic enzymes to unmask antigens in sections. *J Clin Pathol* 1978;**31**:974-83.
- Mephram BL, Frater W, Mitchel BS. The use of proteolytic enzymes to improve immunoglobulin staining by the PAP technique. *Histochem J* 1979;**11**:345-57.
- Brozman M, Brozmanova E. Immunohistochemical methods to localise hormones in the human adeno-hypophysis. *Commun Czechoslov Soc Histochem Cytochem* 1966;**1**:25-30.

Requests for reprints to: Dr JB Matthews, Immunology Laboratory, Department of Oral Pathology, The Dental School, St Chad's Queensway, Birmingham B4 6NN, UK.