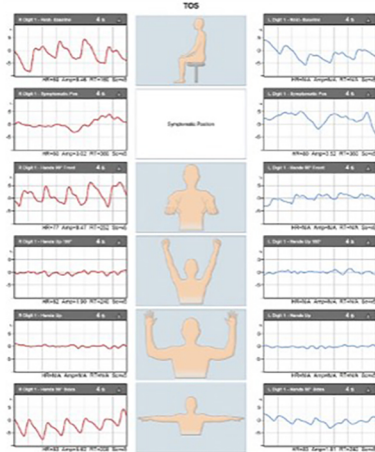

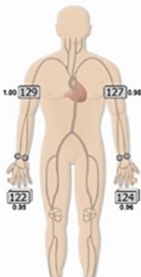

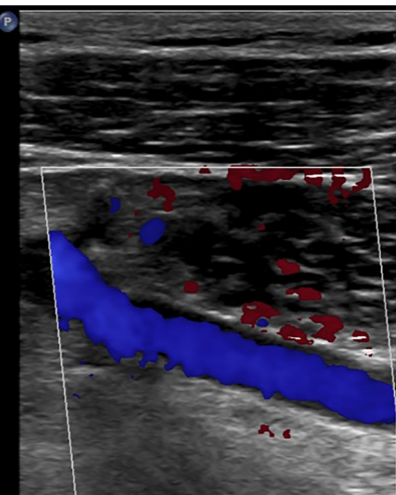
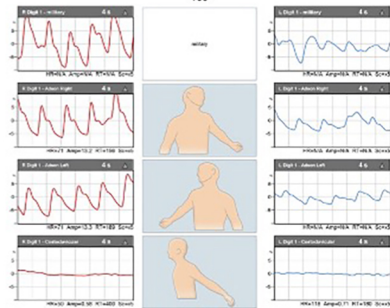


Madassah Upper Arterial



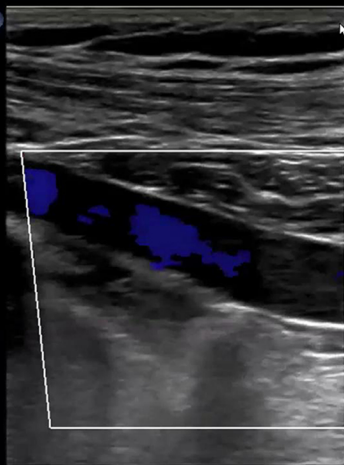
TOS



Vasc Venous
L12-3
12Hz

2D
51%
Dyn R 56
P Low
HGen

CF
49%
1500Hz
WF 75Hz
4.0MHz



TISO.2 MI 1.2



5.0cm bpm

Left Subclavian V TOS TEST