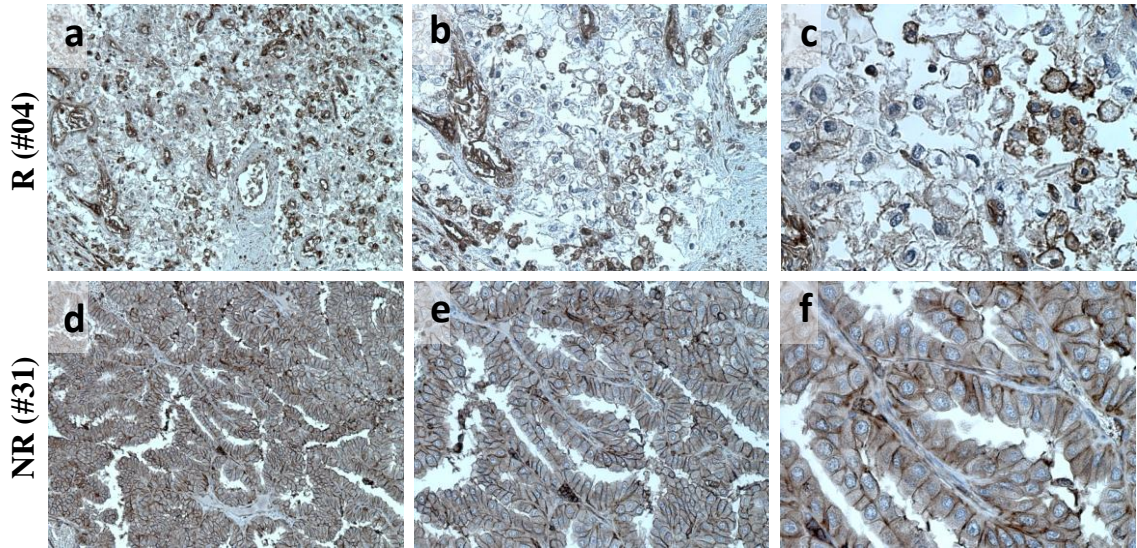
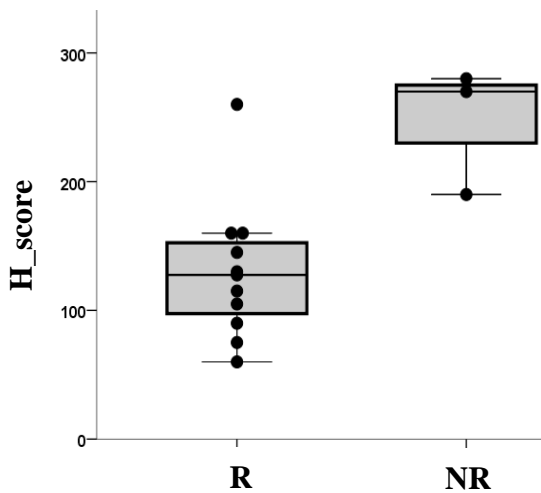
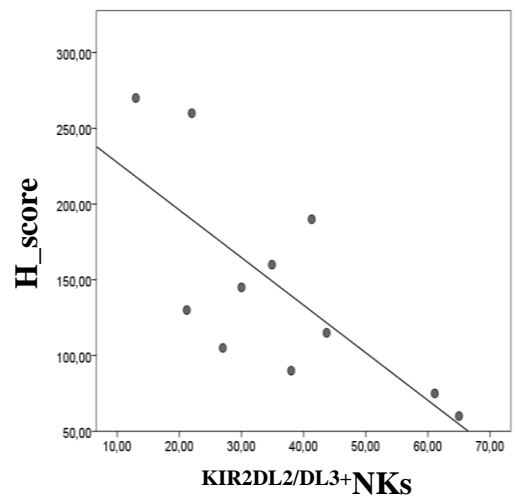


A**B****C**

Supplementary Figure S11. HLA class I in primary RCC from REV patients. HLA class I (-A, -B, -C) by IHC in FFPE from RCC primary tumors (n=14) (antibody 15240-1-AP at 1:1000 dilution). H-Score: staining intensity [0 (negative), 1 (weak) 2 (moderate), or 3 (strong)] \times staining percentage. **(A)** (a-c) Representative R patient (#04). HLA class I *heterogeneous staining* with reduced membrane and cytoplasmic staining x100 (a) x200 (b) and x400 (c) magnification. **(d-f)** Representative NR patient (#31) HLA class I frankly positive staining with uniform, intense membrane staining as well as cytoplasm staining x100 (d) x200 (e) and x400 (f) magnification. **(B)** Box and Whisker plot showed lower HLA class I (-A, -B, -C) H-score in (n=11) R compared to (n=3) NR, Mann-Whitney test, p =0.011. **(C)** Kendall's rank for HLA class I H-score and basal peripheral $KIR2DL2/DL3^+$ NKs (Kendall's Tau coefficient=-0,527 p=0,024; n=11).