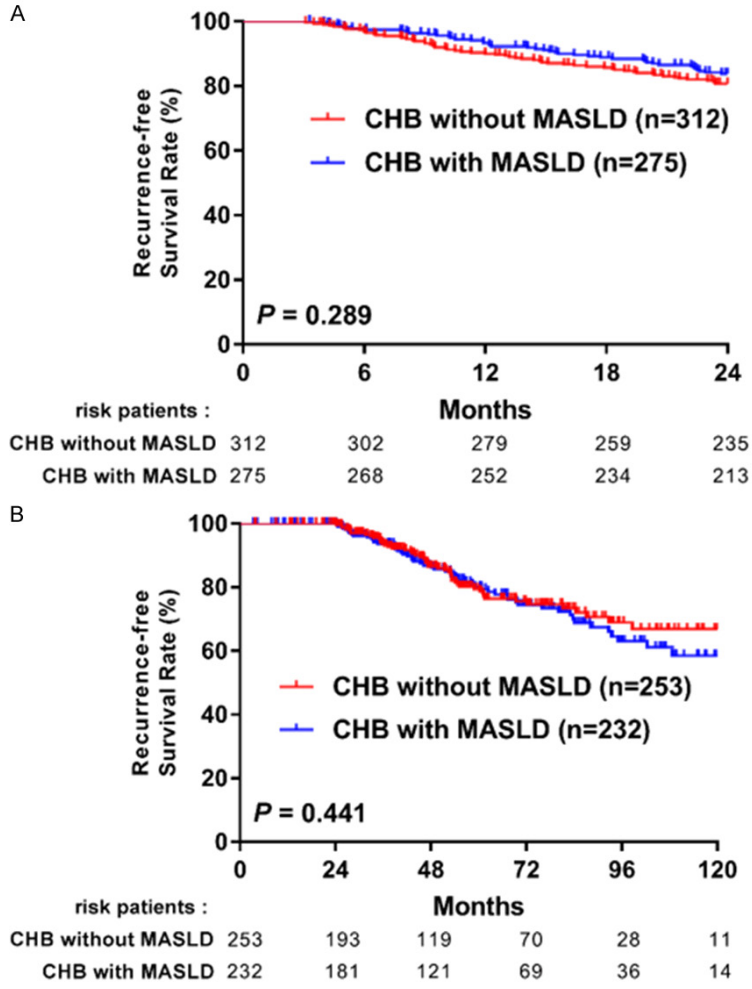


The impact of MASLD on HCC after resection



**Figure S1.** Early RFS (A) and late RFS (B) after curative resection in patients with HBV-related HCC with or without MASLD.