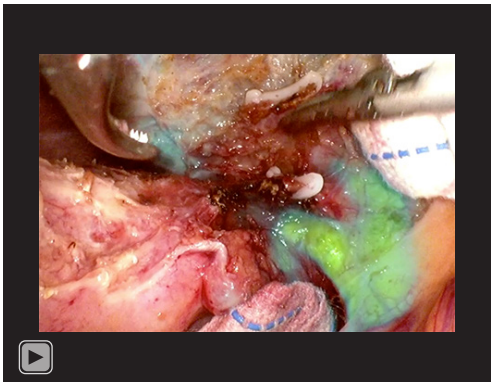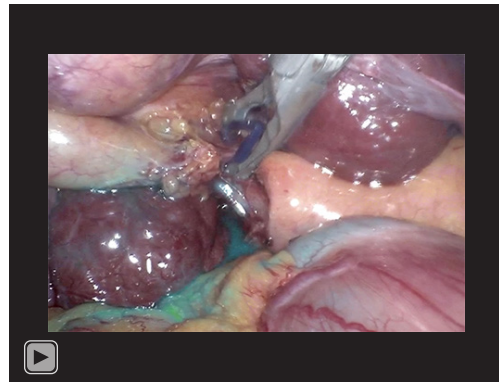




Video S1 Fluorescent cholangiography of extrahepatic biliary system following intravenous ICG injection, 90 s, 73 MB. The patient was a 55-year-old man with a gallbladder polyp. He was injected with 10 mg of ICG via the peripheral vein 10 h prior to surgery. Before LC, his total serum bilirubin was 11.3 $\mu\text{mol/L}$. The operative time was 61 min, and the blood loss was 15 mL. His postoperative course was uneventful.



Video S2 Fluorescent cholangiography of extrahepatic biliary system following intragallbladder ICG injection, 51 s, 40.6 MB. The patient was a 62-year-old male with a solitary gallbladder stone combined with liver cirrhosis. Intraoperatively, 4 mL of saline containing 10 mg of ICG was injected through the gallbladder. Before cholecystectomy, his serum total bilirubin was 21.0 $\mu\text{mol/L}$. The operative time was 72 min, and the blood loss was 20 mL. Postoperative recovery was uneventful.