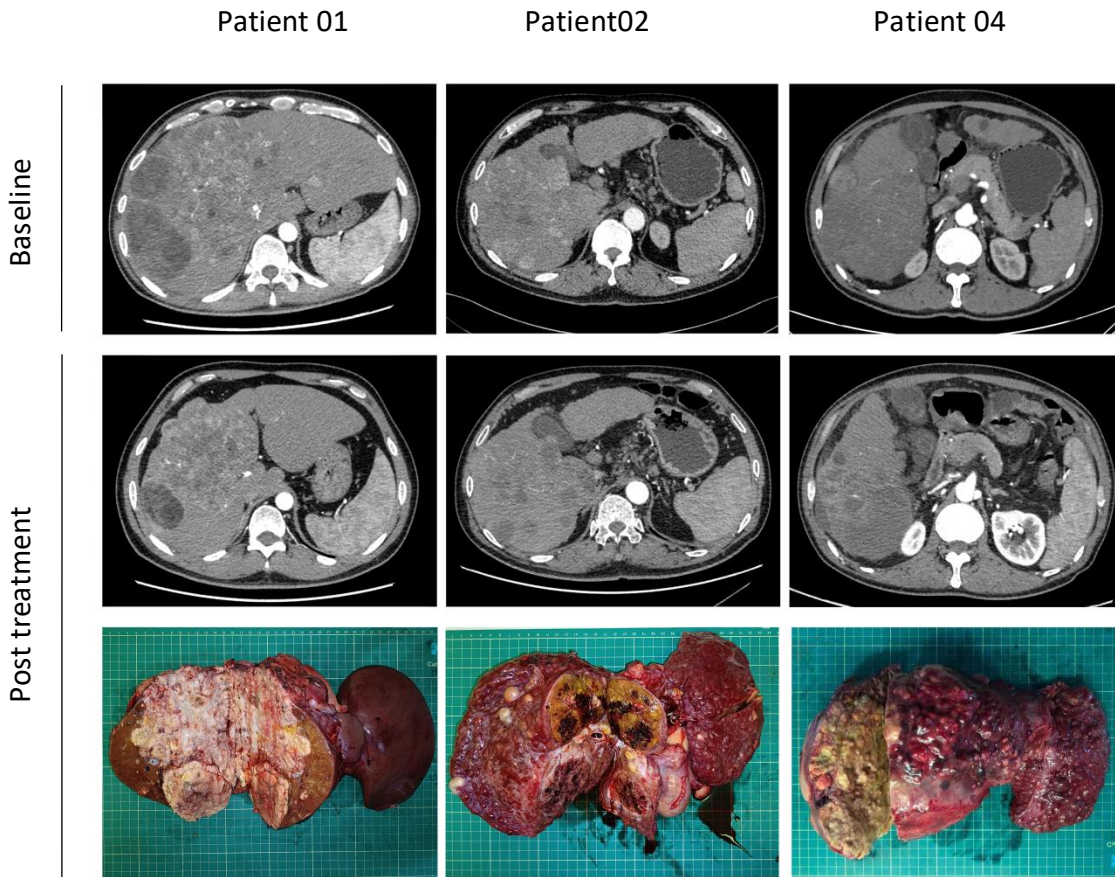


**Supplementary Figure 1:** Representative images and pathological specimens of patients with observed necrosis.



## Supplementary Figure 2: Changes of biomarkers, cytokines, and lymphocyte subsets in peripheral blood for patients with different tumor necrosis rates

