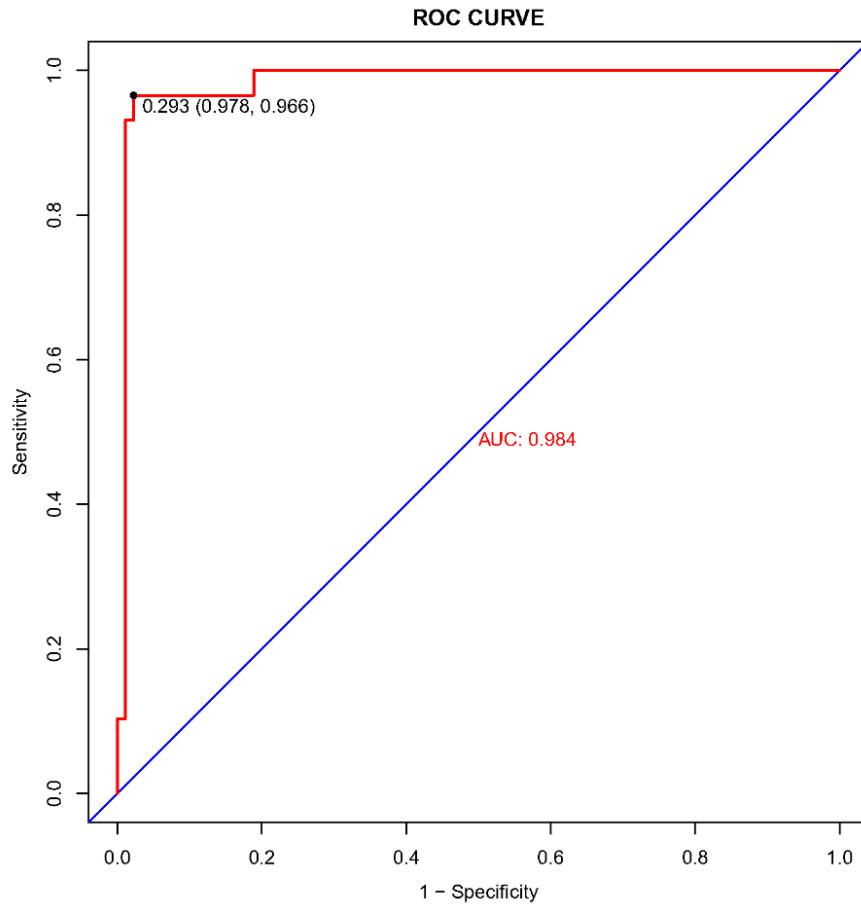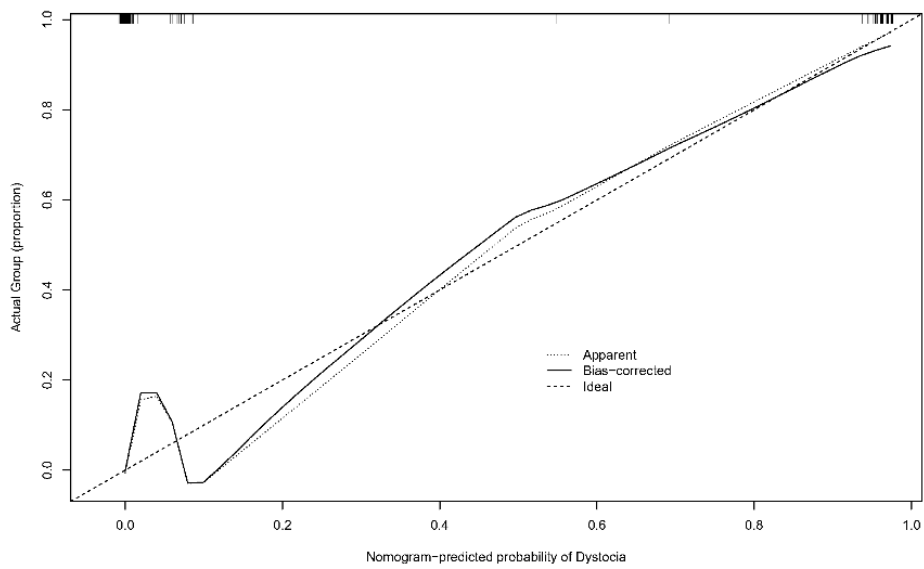


Supplementary Figure 1: Receiver operating characteristic curve for diagnosing testicular yolk sac tumor



Supplementary Figure 2: Calibration plot for predicting the probability of testicular yolk sac tumor