

## The development of pneumatisation in the postcranial skeleton of the domestic fowl

D. A. HOGG

*Department of Veterinary Anatomy, University of Nairobi,  
P.O. Box 30197, Nairobi, Kenya*

(Accepted 8 December 1983)

### INTRODUCTION

The development of pneumatisation within the skeleton of birds is generally acknowledged to take place after hatching, at least as far as the postcranial skeleton is concerned. For domestic species, there is an almost complete lack of details of the timing of the process, to which textbooks of veterinary avian anatomy tend to make only the briefest reference, for example Bradley (1960) describes it as a late development. The work of Bremer (1940) is one of the very few scientific reports on the subject and is concerned principally with bone changes occurring during the development of pneumatisation and the factors which may affect this process. However, pneumatisation of the humerus is described as commencing during the third week after hatching.

It has been claimed that considerable variation in the timing of the process can occur due to a variety of factors but there are few reports substantiating such claims. Pratt & McCance (1960) described pneumatisation of the humerus of the fowl as occurring earlier in undernourished birds.

This study was undertaken to investigate the timing of development of skeletal pneumatisation in a group of similar birds, reared under standardised conditions, and to make limited comparisons with birds of a different breed. All bones of the postcranial skeleton which had been found to be pneumatised in a previous study of adult birds (Hogg, 1984), together with the sternal ribs, were examined. The skull, where pneumatisation commences in embryo, is to be the subject of a subsequent investigation dealing with both the embryonic and posthatching periods.

Nomenclature is in accordance with *Nomina Anatomica Avium* (Baumel *et al.* 1979).

### MATERIALS AND METHODS

Golden Comet pullets, sampled in pairs at hatching and at 7 day intervals until 112 days, then at 14 day intervals until 182 days, were killed by injection of pentobarbitone sodium. The entire vertebral column was dissected free, stripped of flesh, frozen and sectioned with a fine bandsaw, allowing the vertebrae to be counted and examined individually. In the younger birds all vertebrae were unfused and could, therefore, be readily identified. As fusion commenced, individual vertebrae remained recognisable by the presence of intervening ridges within the vertebral canal and by the emerging spinal nerves. Due to difficulty in establishing the identity of the individual vertebrae in the future synsacrum as lumbar, sacral or coccygeal, these were referred to simply as synsacral and numbered in series. The sternum was




Fig. 1. Occurrence of pneumatisation in cervical vertebrae in pairs of Golden Comet pullets of known ages.

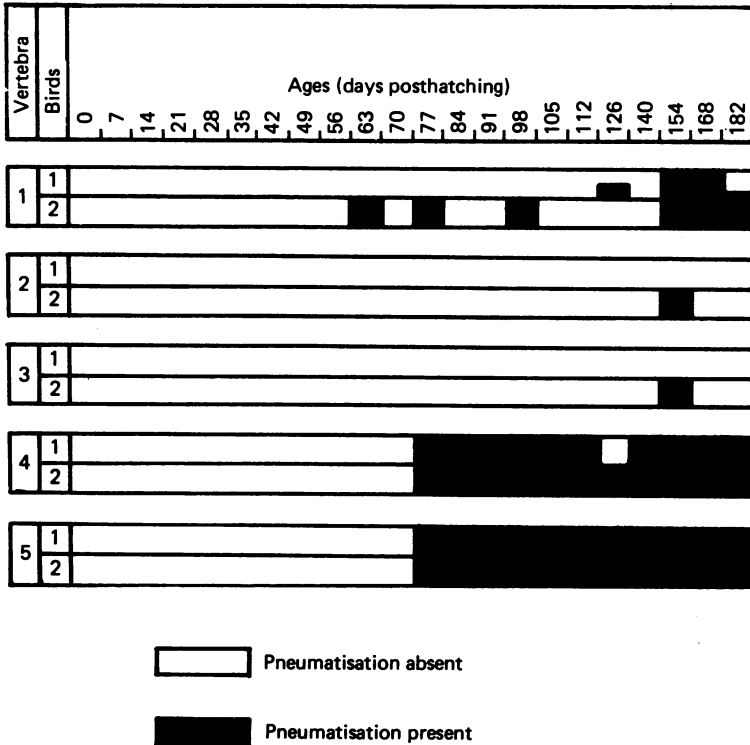


Fig. 2. Occurrence of pneumatisation in thoracic vertebrae in pairs of Golden Comet pullets of known ages.

sectioned longitudinally through the body and keel, and then the processes were sectioned. Vertebral and sternal ribs were sectioned transversely with forceps and the ossa coxarum, coracoids and humeri were sectioned longitudinally. All sectioned surfaces were examined with the aid of a Zeiss operating microscope at magnifications up to  $\times 40$  for evidence of pneumatisation.

A flock of White Leghorn birds was sampled in pairs, male and female, at hatching and then at 7 day intervals until 119 days, with the final male bird examined at 126 days posthatching. The left coracoids and humeri of these birds were sectioned longitudinally and similarly examined.

RESULTS

*Vertebral column*

*Cervical region*

All birds examined had sixteen vertebrae. The pattern of development of pneumatisation is shown in Figure 1.

No pneumatisation was found until 35 days posthatching when it had occurred in several vertebrae in both birds examined. The last vertebra to show the onset of pneumatisation was number 14. The usual pattern of adult pneumatisation described by Hogg (1984), involving vertebrae numbers 3–16, was present in most birds from 63 days posthatching onwards.




Fig. 3. Occurrence of pneumatization in synsacral vertebrae in pairs of Golden Comet pullets of known ages.

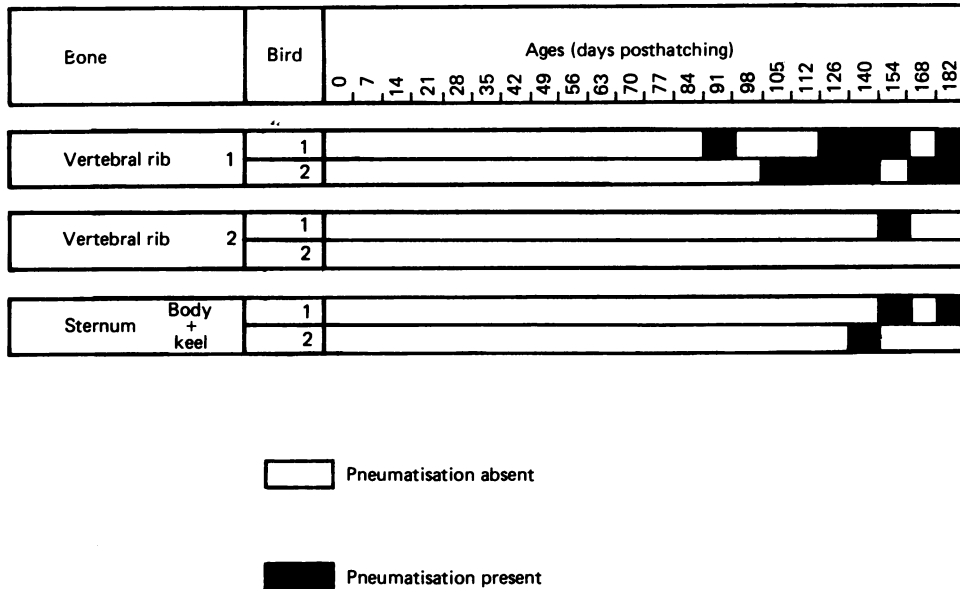


Fig. 4. Occurrence of pneumatisation in vertebral ribs 1 and 2 and in the sternum in pairs of Golden Comet pullets of known ages.

Partial pneumatisation of individual vertebrae was virtually only encountered up to 49 days posthatching.

*Thoracic region*

All birds examined had five vertebrae. The pattern of development of pneumatisation is shown in Figure 2.

No pneumatisation was observed until 63 days posthatching when it occurred in the first thoracic vertebra of one bird. It was next found at 77 days, after which it was virtually constantly present in thoracic vertebrae 4 and 5 but continued to be variable in thoracic 1. Evidence of pneumatisation in thoracic vertebrae 2 and 3 was found only in one bird at 154 days posthatching.

In most instances when pneumatisation occurred it involved the vertebra fully.

*Synsacral region*

All birds examined had fifteen vertebrae. The pattern of development of pneumatisation is shown in Figure 3.

Pneumatization was first found in the cranial members of the series at 77 days posthatching and was fairly constant thereafter. Caudal to synsacral vertebra 8 it was only encountered at 182 days and was not identified at all in synsacrals 11 and 12.

*Ribs and sternum*

Pneumatization was found only in vertebral ribs 1 and 2 and in the body and keel of the sternum as shown in Figure 4.

*Os coxae*

No pneumatisation was found.

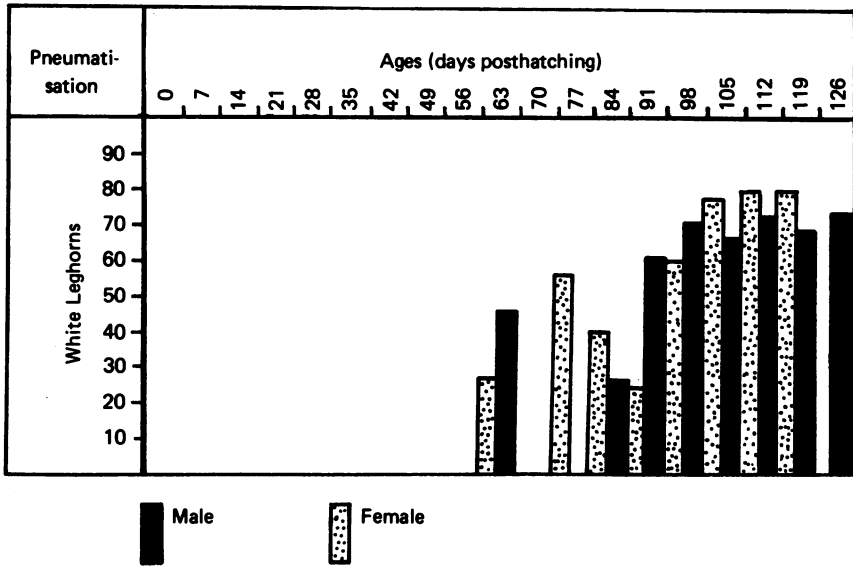


Fig. 5. Occurrence and extent of pneumatisation in the left coracoid of birds of known ages.

#### *Coracoid*

In the Golden Comet birds there was no pneumatisation at all. The pattern of development in the White Leghorns is shown in Figure 5.

Pneumatisation was first noted at 63 days posthatching and was present in all birds aged 84 days and over. In all birds aged 91 days and over the process involved 60–80% of the length of the bone.

The difference in rate of development in male and female birds was examined by a paired *t* test and was found to be not statistically significant ( $P > 0.10$ ).

#### *Humerus*

The pattern of development of pneumatisation in the Golden Comets and White Leghorns is shown in Figure 6.

In the Golden Comet birds, pneumatisation was first found at 35 days posthatching and was present in all but three birds examined thereafter. The extent gradually increased, though subject to variation, and when present involved 80% or more of the length of the bone in all birds after 112 days posthatching.

In the White Leghorn birds pneumatisation was first encountered at 28 days and was present in all specimens examined thereafter. The extent increased rapidly and, with one exception, involved over 80% of the length of the bone in all birds aged 84 days or over. Up to 112 days, the extent in the female appeared to exceed that in the male birds of the pair. This difference was investigated by a paired *t* test and was found to be highly statistically significant ( $P < 0.01$ ).

The rate of development in Golden Comet pullets appeared to be rather slower than in White Leghorn pullets. This difference was also found to be highly significant ( $P < 0.001$ ) using a paired *t* test.

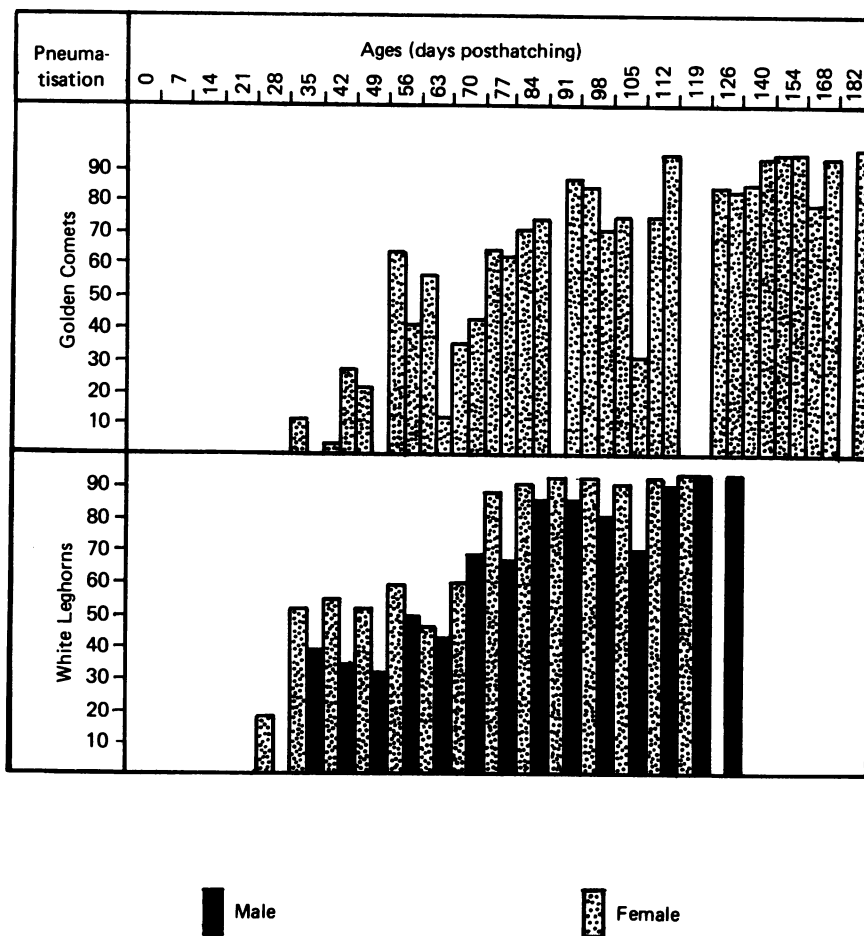


Fig. 6. Occurrence and extent of pneumatisation in the left humerus of birds of known ages.

DISCUSSION

The cervical air sac pneumatises the vertebral column from the third cervical to the third thoracic vertebrae (Campana, 1875; King & Kelly, 1956; King, 1957). The sac consists of a main chamber with one pair of extraspinal and one pair of intraspinal extensions which extend cranially to the junction between the second and third cervical and caudally to the first thoracic vertebrae (King, 1975).

After the time of onset of pneumatisation, some birds lack pneumatisation in the most cranial and the most caudal cervical vertebrae although it is present in the middle region. This may possibly be due to the air sacs being incompletely developed at this time. Thoracic vertebrae 2 and 3 were pneumatised in one bird only at 154 days posthatching. As the cervical air sac extends caudally only as far as the first thoracic vertebra, the likely route of pneumatisation to thoracic vertebrae 2 and 3 would seem to be through the bones after fusion of the bodies occurs, from 126–140 days posthatching (Hogg, 1982). This route would also help to explain the lower incidence of pneumatisation in these bones than in the more cranial ones in adults, as noted by King & Kelly (1956) and Hogg (1984).

The abdominal sac pneumatise the synsacrum, as well as thoracic vertebra 5, the free fourth thoracic vertebra and the os coxae (King, 1975). In the present study, pneumatisation is first encountered at 77 days posthatching when it involves thoracic 4 to synsacral 5. It spreads more caudally later, from 126 days posthatching onwards, perhaps again following the process of fusion between synsacral vertebrae. This commences between the bodies of synsacral vertebrae 1–8 from 49 days posthatching onwards and spreads caudally rather later, from 105 days onwards (Hogg, 1982). The lack of evidence of pneumatisation in the os coxae in the birds examined in this study might be explained if the process had not yet spread into this skeletal region by the end of the period studied.

After the onset of pneumatisation in the coracoid in the White Leghorn birds, it is present in virtually all specimens examined, whereas in adult Golden Comet birds the coracoid is pneumatised only in 7 out of 48 cases (Hogg, 1984). This lower incidence in adult Golden Comets may help to explain the remarkable lack of any evidence of pneumatisation in the Golden Comet pullets in the present series.

In the humerus, the incidence of pneumatisation is again fairly constant in White Leghorns after the time of onset, though it remains absent in a few of the older Golden Comets. The more rapid rate of development in White Leghorns than in Golden Comets is also rather surprising in view of the general similarity of these two types of laying birds. Possible differences in other breeds or in broiler types would seem to be worth studying.

Bremer (1940), studying pneumatisation of the humerus in the fowl, suggests that oestrogens of yolk sac origin act directly or indirectly on the parathyroid glands producing a condition in the bone similar to osteitis fibrosa cystica in man. Such an effect of oestrogen might help to explain the more rapid development of pneumatisation in the humerus of female than male White Leghorn birds seen in the present investigation. However, Bremer (1940) could not confirm any delay in the onset of pneumatisation following the administration of androgens. The whole process of development of pneumatisation in birds, and also in mammals, is a field requiring much further investigation.

#### SUMMARY

The development of pneumatisation in the postcranial skeleton has been investigated in a flock of Golden Comet pullets from hatching to 182 days posthatching. The timing of development of pneumatisation in the vertebral column, vertebral ribs, sternum and humerus has been demonstrated. No pneumatisation was encountered in the sternal ribs, os coxae or coracoid.

Development of pneumatisation in the coracoid and humerus was also studied in a flock of White Leghorn pullets and cockerels from hatching to 126 days posthatching. In this group, regular pneumatisation of the humerus occurred after the time of onset and the coracoid was frequently pneumatised unlike the Golden Comets. The rate of development of pneumatisation in the humerus was more rapid in White Leghorn pullets than in cockerels and also more rapid than in Golden Comet pullets.

#### REFERENCES

- BAUMEL, J. J., KING, A. S., LUCAS, A. M., BREAZILE, J. E. & EVANS, H. E. (ed.) (1979). *Nomina Anatomica Avium*. London: Academic Press.
- BRADLEY, O. C. (1960). *The Structure of the Fowl*, 4th ed. (ed. T. Grahame). Edinburgh and London: Oliver & Boyd.
- BREMER, J. L. (1940). The pneumatization of the humerus in the common fowl and the associated activity of theelin. *Anatomical Record* 77, 197–211.



- CAMPANA, A. (1875). *Anatomie de l'Appareil Pneumatique-pulmonaire, etc. chez le Poulet*. Paris: Masson.
- HOGG, D. A. (1982). Fusions occurring in the postcranial skeleton of the domestic fowl. *Journal of Anatomy* **135**, 501–512.
- HOGG, D. A. (1984). The distribution of pneumatiation in the skeleton of the adult domestic fowl. *Journal of Anatomy* **138**, 617–629.
- KING, A. S. & KELLY, D. F. (1956). The aerated bones of *Gallus domesticus*: The fifth thoracic vertebra and sternal ribs. *British Veterinary Journal* **112**, 279–283.
- KING, A. S. (1957). The aerated bones of *Gallus domesticus*. *Acta anatomica* **31**, 220–230.
- KING, A. S. (1975). Aves: respiratory system. In Sisson and Grossman's *Anatomy of the Domestic Animals*, 5th ed., vol. II (ed. R. Getty), pp. 1883–1918. London, Philadelphia, Toronto: W. B. Saunders.
- PRATT, C. W. M. & MCCANCE, R. A. (1960). Severe undernutrition in growing and adult animals. 2. Changes in the long bones of growing cockerels held at fixed weights by undernutrition. *British Journal of Nutrition* **14**, 75–82.