

## Studies on the distribution of binucleate cells in the placenta of the sheep with a monoclonal antibody SBU-3

C. S. LEE, K. GOGOLIN-EWENS, T. R. WHITE  
AND M. R. BRANDON

*Department of Veterinary Preclinical Sciences, University of Melbourne,  
Parkville, Victoria, 3052, Australia*

(Accepted 28 September 1984)

### INTRODUCTION

The binucleate cells in the trophoblast of the sheep have been shown to appear as early as Day 16 of pregnancy (Boshier, 1969). Light microscopical studies led early workers (Assheton, 1906; Wimsatt, 1951; Amoroso, 1952) to suggest that the syncytial layer in the placentome is formed by migration and fusion of the fetal binucleate cells from the trophoblast. This theory has recently been supported by electron microscopical (Wooding *et al.* 1980) and autoradiographic (Wooding, Flint, Heap & Hobbs, 1981) studies. However other workers (Bjorkman, 1965; Boshier & Holloway, 1977; Steven *et al.* 1978) have suggested that the syncytium is formed by fusion of the original uterine epithelial cells.

By using immunofluorescence and immunocytochemical techniques several workers (Martal, Djiane & Dubois 1977; Reddy & Watkins, 1978; Watkins & Reddy, 1980; Wooding, 1981) have demonstrated that the peptide hormone, ovine placental lactogen, is localised in the binucleate cells in the fetal chorionic epithelium and in the syncytial layer of the placentome. Watkins & Reddy (1980) indicated that two classes of binucleate cells may exist in the placenta, one associated with the production of ovine placental lactogen and the other with the synthesis of another class of biologically active protein or steroid.

Our laboratory has recently made a monoclonal antibody SBU-3 (K. Gogolin-Ewens, C. S. Lee, A. M. Moseby & M. R. Brandon, unpublished) which recognises a population of binucleate cells in the trophoblast and also the syncytial layer in the placentome of the sheep. This paper describes the distribution in the placentome of the sheep of this unique class of cells identified by the monoclonal antibody SBU-3.

### MATERIALS AND METHODS

Pregnant uteri of sheep at various stages of gestation were obtained from the abattoir. A total of 34 uteri was collected. The stages of pregnancy were assessed by measuring crown-rump length of the fetuses (Barcroft, 1952; Bryden, Evans & Binns, 1972). They were estimated to be at 21 (N = 5), 30 (7), 34 (3), 40 (3), 50 (4), 80 (3), 100 (3), 120 (3) and 145 (3) days of gestation.

For immunohistochemical studies, tissues of placentomes and interplacentomal areas were fixed and processed according to the method of Sainte-Marie (1962). Some tissues were also fixed in Bouin's fluid, and some by perfusion of 2% glutaraldehyde in phosphate-buffered saline pH 7.2, via the fetal chorionic or maternal

uterine arteries. All tissues were then processed, embedded in paraffin and cut at a thickness of 5 to 7  $\mu\text{m}$ .

The monoclonal antibody designated SBU-3 was prepared according to the method of Galfre *et al.* (1977). Briefly, Balb/C mice were injected intraperitoneally three times at weekly intervals with 0.2 ml trophoblast microvilli prepared from pregnant sheep uteri according to Smith & Brush (1978). Three days prior to fusion a single intravenous injection of 0.1 ml of the microvillous preparation in phosphate-buffered saline was given.  $10^8$  spleen cells from the hyperimmunised mice were fused with  $10^7$  NS-1-AG4.1 mouse myeloma cells with polyethylene glycol 4000 (Merck). Hybridomas were maintained in HAT/RPMI-1640 (Flow Laboratories) supplemented with 10% fetal calf serum. Initial screening of hybridoma supernatants was performed using radioimmunoassay against fresh or 1.2% glutaraldehyde-fixed trophoblast microvilli preparations and lymphocytes. SBU-3 was subcloned five times to ensure the presence of only a single antibody specificity.

Histological sections cut at 5 to 7  $\mu\text{m}$  were stained routinely with haematoxylin and eosin, and reacted by the periodic acid-Schiff technique. Following close examination, further sections were prepared for immunohistological studies using the indirect immunoperoxidase technique. The tissue sections were thoroughly washed in phosphate-buffered saline at 4 °C, and then covered by a drop of SBU-3 supernatant and incubated for 45 minutes in a humid chamber at room temperature. The sections were again thoroughly washed with phosphate-buffered saline and allowed to react with a horseradish peroxidase-conjugated rabbit-antimouse antibody (Dako) absorbed with 10% normal sheep serum in the same manner as described above. After thorough washing, the sections were incubated with 0.5% (w/v) diaminobenzidine (Sigma) in tris-buffered saline containing 0.06% hydrogen peroxide. The reaction was allowed to continue for 10 minutes at room temperature. The slides were washed in phosphate-buffered saline, dehydrated, cleared in xylene and mounted in DPX. Some sections were counterstained with haematoxylin. As control a monoclonal antibody raised against sheep red blood cells was substituted for SBU-3.

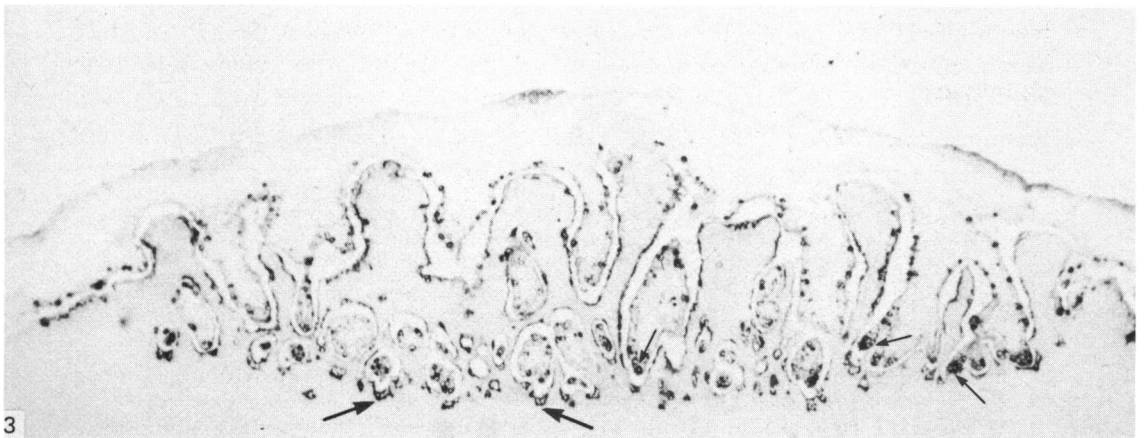
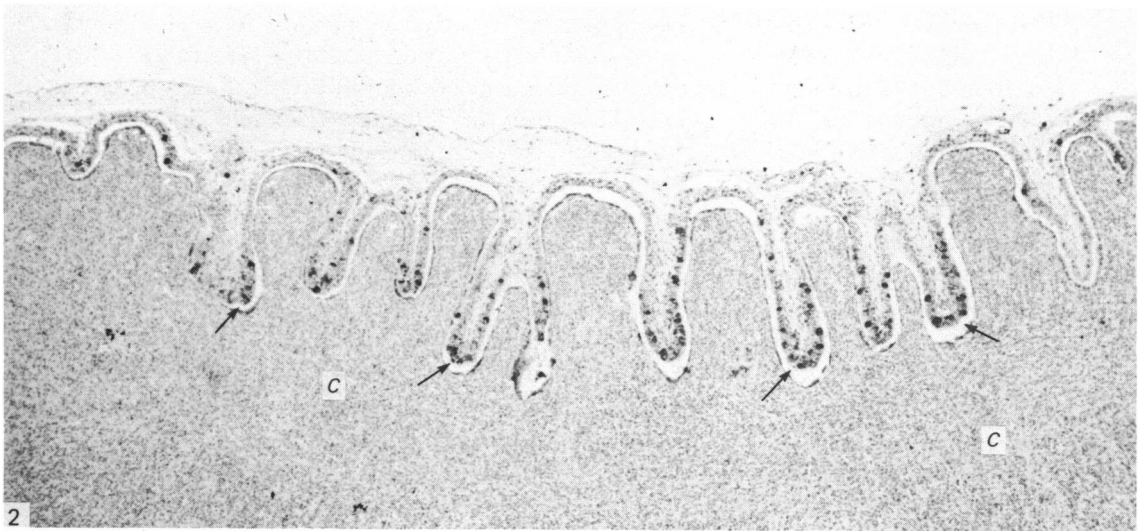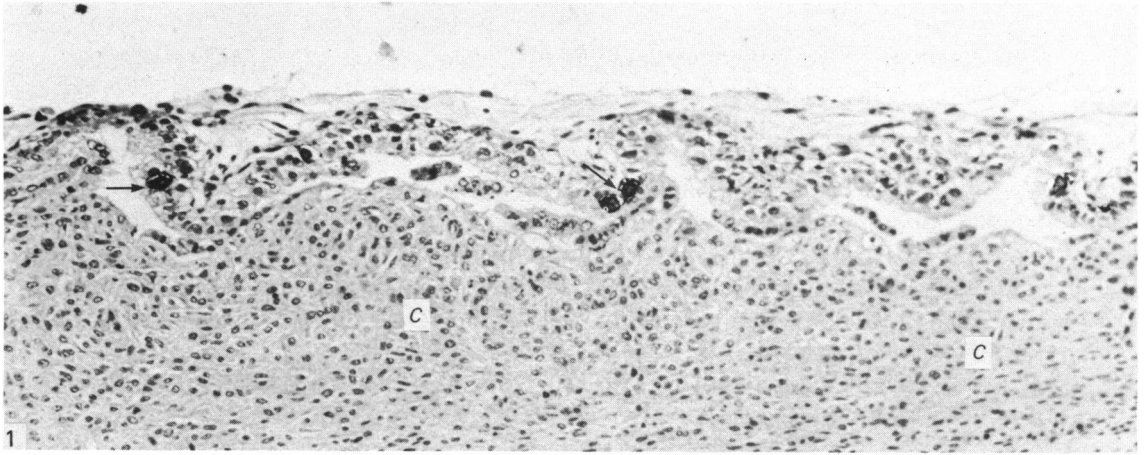
Tissue sections of the liver, pituitary, adrenal, pancreas, cerebrum, cerebellum, ovary, corpus luteum and sagittal sections of fetuses with crown-rump lengths of 3 cm were also tested with SBU-3. To investigate whether SBU-3-positive cells were also periodic acid-Schiff-positive some sections were first stained with periodic acid-Schiff and then counterstained using the indirect immunoperoxidase technique. In addition, some tissues fixed in 80% ethanol were sectioned and stained for alkaline phosphatase according to the method of Culling (1957).

---

Fig. 1. Very early sign of trophoblastic invasion of the caruncle (C). Note the SBU-3-positive cells (arrows) in the trophoblast. Day 21 of gestation. Indirect immunoperoxidase method, counterstained with haematoxylin.  $\times 180$ .

Fig. 2. Chorionic villi in the form of finger-like projections invading the caruncle (C). Note the numerous SBU-3-positive cells (arrows) in the trophoblast of the chorionic villi. Day 30 of gestation. Indirect immunoperoxidase method, counterstained with haematoxylin.  $\times 45$ .

Fig. 3. Placentome relatively more advanced in development than that shown in Figure 2. Note that there are far more SBU-3-positive cells in the trophoblast. The tip of the chorionic villi is seen with clusters of SBU-3-positive cells (small arrows). The syncytial layer is also SBU-3-positive and the giant cells (large arrows) at the basal region of the caruncular crypts are protruding into the underlying stroma. Day 30 of gestation. Indirect immunoperoxidase method.  $\times 45$ .



## RESULTS

*Distribution of SBU-3-positive cells in the placentomes and interplacentomal areas*

Studies revealed that SBU-3-positive cells were localised mainly in the placentomes and their concentration increased dramatically with the development of the placentomes (Figs. 1–4).

At 21 days of gestation only some tissues showed early signs of interdigitation between the trophoblast and the caruncle. In most tissue sections adhesion between the trophoblast and the caruncular epithelium did not survive the fixation procedures. However SBU-3-positive cells were occasionally observed but only in the trophoblast, which showed early signs of invasion of the caruncle (Fig. 1). Higher magnification revealed that most of these cells were interspersed between the uninucleated cells of the trophoblast and were spherical in shape. Most of them were binucleate cells and the positive brownish reaction product was sometimes seen located at the basal region of the cell. With serial sections most of the other positive apparently uninucleate cells which were also spherical were shown to be binucleate. Thus for convenience and clarity the term 'binucleate cell' will include this cell population also in the rest of the text. No SBU-3-positive cell was seen in the interplacentomal areas, nor in tissues where there was no sign of interdigitation between the trophoblast and the caruncle. There was no recognition of any other extracellular substances by SBU-3 at this early stage of pregnancy.

At 30–34 days of gestation, the placentomes presented various stages of development. In some, chorionic villi were projecting further into the caruncle (Fig. 2). Far more SBU-3-positive cells (Figs. 5, 6) were seen in the trophoblast of the chorionic villi than at 21 days. The caruncular crypt was lined by flattened to cuboidal epithelial cells among which were interspersed some SBU-3-positive binucleate or SBU-3-positive giant cells (Figs. 5, 6). The SBU-3-positive giant cells were usually located at or close to the basal region of the crypt (Fig. 6). The reaction product was usually localised in the cytoplasm of the cell facing the stroma (Fig. 6). Overall the *caruncular epithelium* had generally transformed into a layer in which cell boundaries became difficult to define and from now on is referred to as *syncytial layer*. The binucleate cells in the trophoblast of interplacentomal areas were only occasionally recognised by SBU-3 (Fig. 7).

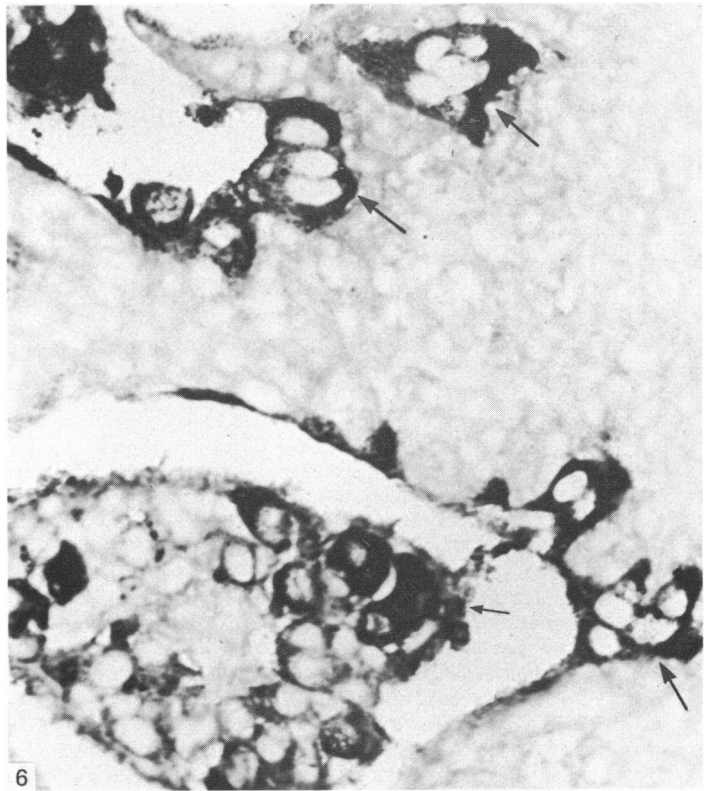
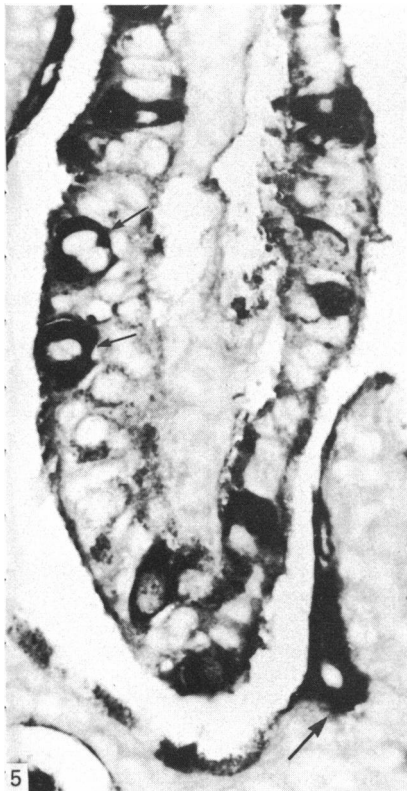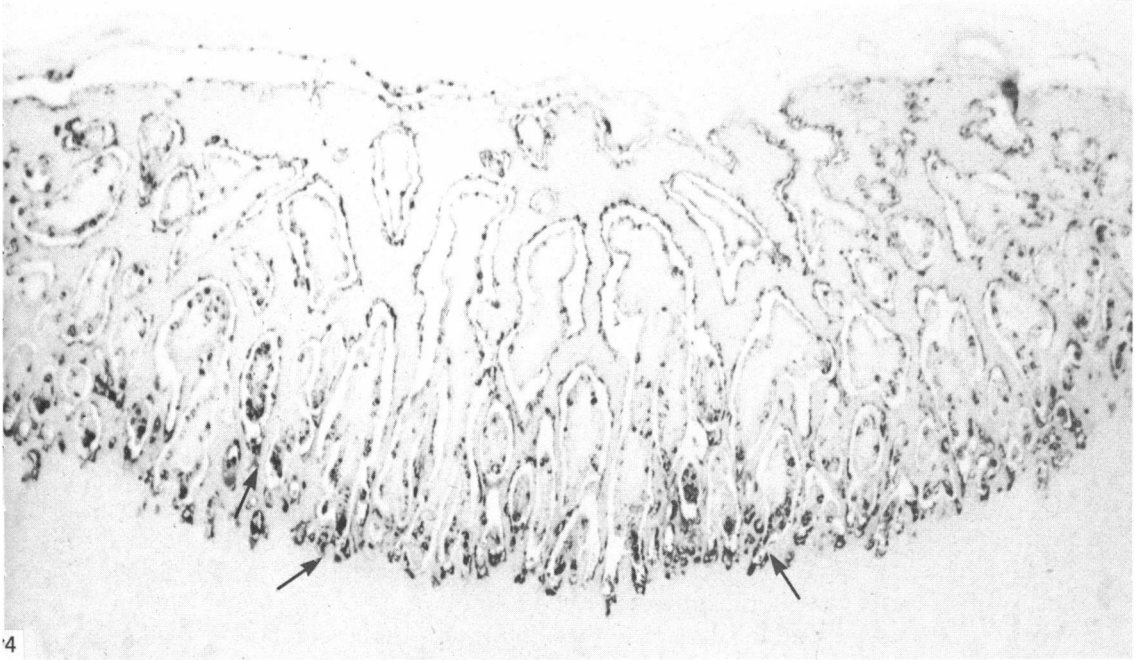
In more developed placentomes, many more SBU-3-positive cells were seen in the trophoblast lining the complex system of chorionic villi (Figs. 3, 4). Most of them were interspersed between uninucleate cells whose brush borders reacted positively with SBU-3 (Fig. 8). Some of the SBU-3-positive cells were seen with cytoplasmic processes extending toward the syncytial layer (Fig. 8), and some were located

---

Fig. 4. Relatively well established placentome. As in Figure 3, a large number of SBU-3-positive cells are localised at the tips of the chorionic villi and the basal region of the caruncular crypts (arrows). Day 34 of gestation. Indirect immunoperoxidase method.  $\times 45$ .

Fig. 5. SBU-3-positive cells in the trophoblast of a chorionic villus. Note that some of the cells are binucleated (small arrows). Serial sections confirmed that the other SBU-3-positive cells are also binucleated. The syncytial layer (large arrow) is also positively stained. Day 30 of gestation. Indirect immunoperoxidase method.  $\times 450$ .

Fig. 6. Showing a cluster of SBU-3-positive binucleate cells at the tip of the chorionic villus (small arrow). Note that the SBU-3-positive giant cells (large arrows) localised at the basal region of the caruncular crypts are protruding into the underlying stroma. Day 34 of gestation. Indirect immunoperoxidase method.  $\times 450$ .



between the syncytial layer and the trophoblast (Fig. 8). A striking feature was that the SBU-3-positive cells were the predominant cell type in the trophoblast at the tip of the chorionic villi (Figs. 3–6, 9). Some of these cells were seen with an intensely stained reaction product in their basal cytoplasm while, in the region immediately above the nuclei, a SBU-3-positive rounded structure, presumably a well developed Golgi complex (Fig. 9) was observed. The cytoplasm of some binucleate cells was only partially stained and the occasional binucleate cell contained no SBU-3-positive product. Dividing cells were frequently seen in the trophoblast (Fig. 8), but their cytoplasm showed no affinity for SBU-3.

Taken as a whole the syncytial layer was intensely stained. In some giant cells, the SBU-3-positive reaction product within the cytoplasm appeared to be diffuse, whereas in others it appeared to be granular. Occasionally in the basal regions of the caruncular crypts the SBU-3-positive giant cells were not flattened, but were seen with cytoplasmic processes extending basally into the stroma (Fig. 6).

From Days 40–100 all the placentomes observed had a complex system of chorionic villi interdigitating with the caruncular crypts. The pattern of distribution of SBU-3-positive cells in the trophoblast and the syncytial layer of the placentome was identical to that in the relatively well established placentomes at 34 days. By 120–145 days, the syncytial layer became less intensely stained but strongly SBU-3-positive binucleate cells were still seen scattered in the trophoblast.

None of the tissues examined, namely the adult liver, pituitary and adrenal glands, pancreas, cerebrum, cerebellum, ovary, corpus luteum and sagittal sections of fetuses with crown–rump lengths of 3 cm reacted with the monoclonal antibody SBU-3.

#### *Distribution of periodic acid–Schiff-positive cells in the placentomes and interplacentomal areas*

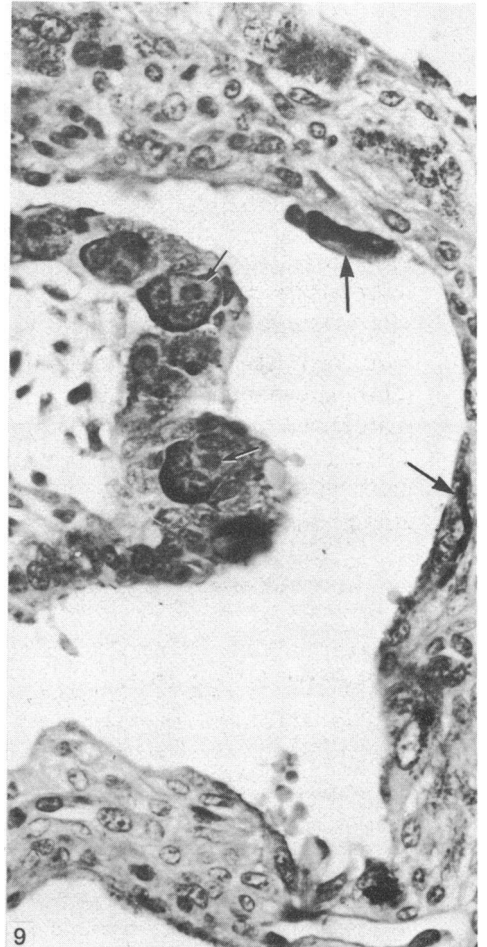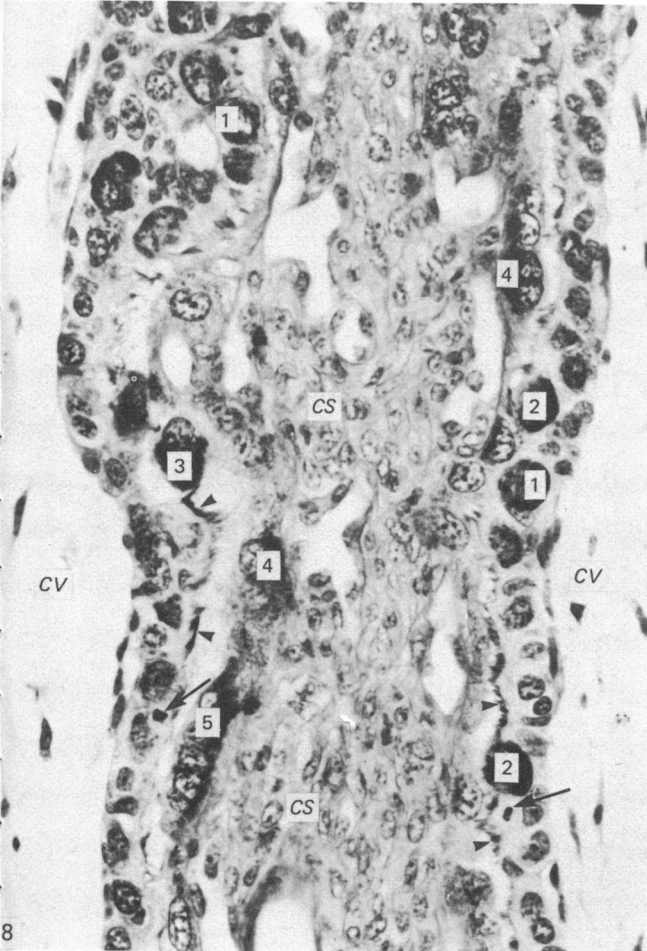
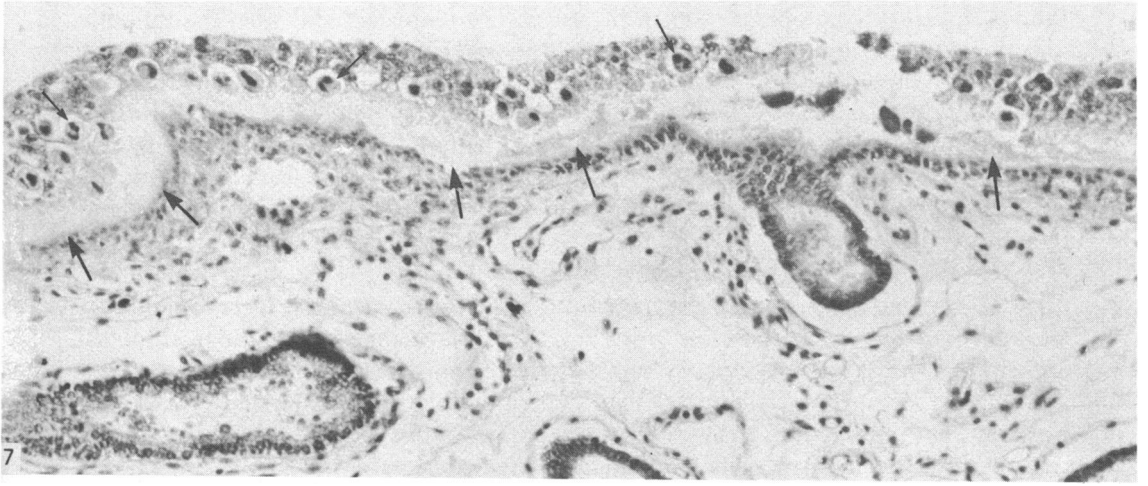
At 21 days, cells with periodic acid–Schiff-positive, diastase-resistant properties (designated as Schiff-positive cells) were observed in the trophoblast in the interplacentomal areas, as well as in those areas lying over the caruncular epithelium. The Schiff-positive cells had a similar appearance to SBU-3 positive cells. A positive periodic acid–Schiff reaction, resistant to diastase, was present in the narrow amorphous layer between the trophoblast and the uterine epithelium.

---

Fig. 7. Interplacentomal area with an endometrial gland opening on to the surface. Note that the trophoblastic binucleate cells (small arrows) are not stained, nor is the layer of substance (large arrows) between the trophoblast and the uterine epithelium. Day 30 of gestation. Indirect immunoperoxidase method, counterstained with haematoxylin.  $\times 180$ .

Fig. 8. A caruncular septum (CS) sandwiched by chorionic villi (CV). There are several SBU-3-positive binucleate cells: some of them (1) are located within the trophoblast, two cells (2) with cytoplasm extending towards the caruncular epithelium, one cell (3) is located between the trophoblast and the syncytial layer and two cells (4) are located in the syncytial layer. A giant cell is also intensely stained (5). Note that the brush borders (arrowheads) of the trophoblast are SBU-3-positive. Mitotic figures (arrows) are also seen in the trophoblast. Day 34 of gestation. Indirect immunoperoxidase method, counterstained with haematoxylin.  $\times 450$ .

Fig. 9. The tip of a chorionic villus, with several SBU-3-positive binucleate cells whose basal regions and Golgi complex (small arrows) are stained. The giant cells (large arrows) in the caruncular crypt are also stained. Indirect immunoperoxidase method, counterstained, with haematoxylin.  $\times 450$ .



As pregnancy advanced there was an increase in the number of binucleate cells in the placentomal trophoblast. A large proportion of these cells was weakly stained or unstained with periodic acid-Schiff, while a minority was intensely stained and others had their cytoplasm partially stained (Fig. 11). The trophoblast at the tip of the chorionic villi was usually seen with a conglomerate of binucleate cells, the cytoplasm of which varied in staining intensity. Most of them were lightly stained, whereas some that were stained intensely had a well developed Golgi complex which stained weakly with periodic acid-Schiff (Fig. 11). The syncytial layer adjacent to this region usually did not stain as strongly as the binucleate cells in the trophoblast (Fig. 13). On the whole, the syncytial layer was very weakly stained. By contrast, most of the binucleate cells in the trophoblast located in the interplacentomal areas were strongly Schiff-positive (Fig. 10). The amorphous layer between the trophoblast and the uterine epithelium, which became more pronounced later in gestation, was strongly Schiff-positive (Fig. 10). This general pattern of distribution of Schiff-positive cells and Schiff-positive amorphous substances in the placentomes and interplacentomal areas persisted throughout pregnancy.

#### *Distribution of doubly stained (Schiff- and SBU-3-positive) cells*

Doubly stained binucleate cells were demonstrated in placentomal tissue from pregnant ewes as early as 21 days of gestation but were more pronounced in placental tissues at 30 and 34 days of gestation. Clusters of double stained cells were usually located in the trophoblast at the tip of the chorionic villi (Fig. 12). Some of these cells showed a Schiff-positive product at the basal region (Fig. 11), while the Golgi complex was SBU-3-positive (Fig. 12). In some, the basal regions were positive to both (mixture of red and brown) but each had a large SBU-3 positive Golgi complex (Fig. 12), whereas in others the basal and the Golgi regions stained with periodic acid-Schiff positively. No cell was seen with a combination of a Schiff-positive Golgi complex and a SBU-3-positive basal cytoplasm. The syncytial layer was extensively stained by SBU-3 and some of the giant cells were also doubly stained (Figs. 13, 14). The periodic acid-Schiff reaction appeared to be much stronger in the binucleate cells located in the trophoblast than in the giant cells in the syncytial layer. However,

Fig. 10. Interplacentomal area with a strong periodic acid-Schiff-positive, diastase-resistant, amorphous layer (large arrows) between the trophoblast and the uterine epithelium. Note that the binucleate cells (small arrows) in the trophoblast are also Schiff-positive. Day 30 of gestation. Periodic acid-Schiff, counterstained with haematoxylin.  $\times 180$ .

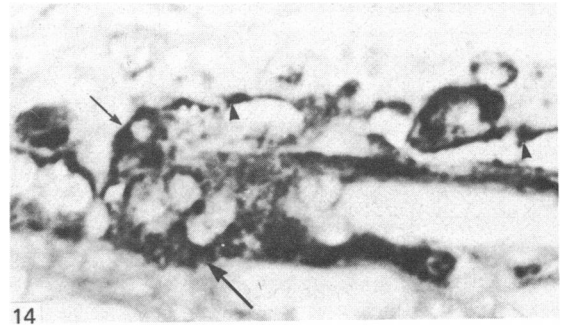
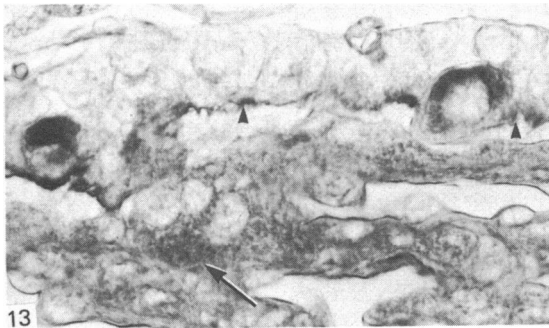
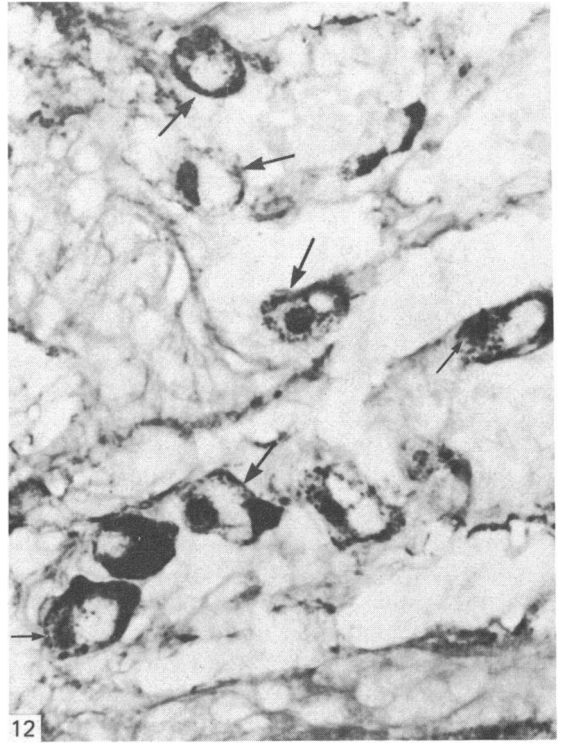
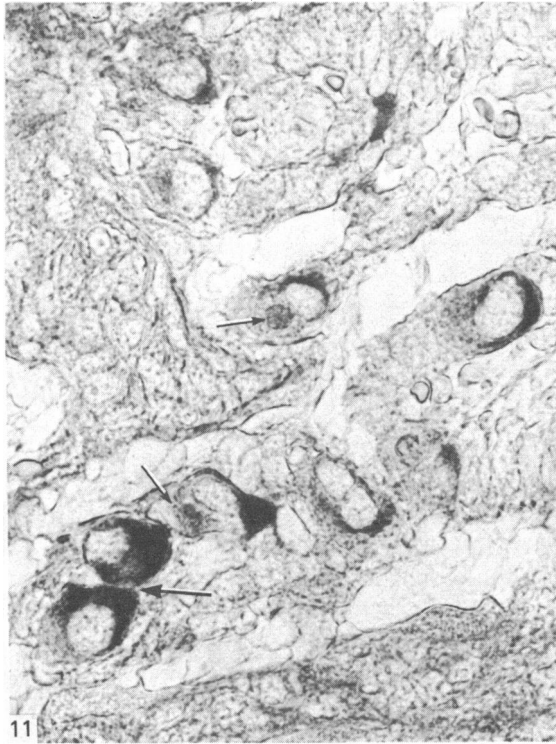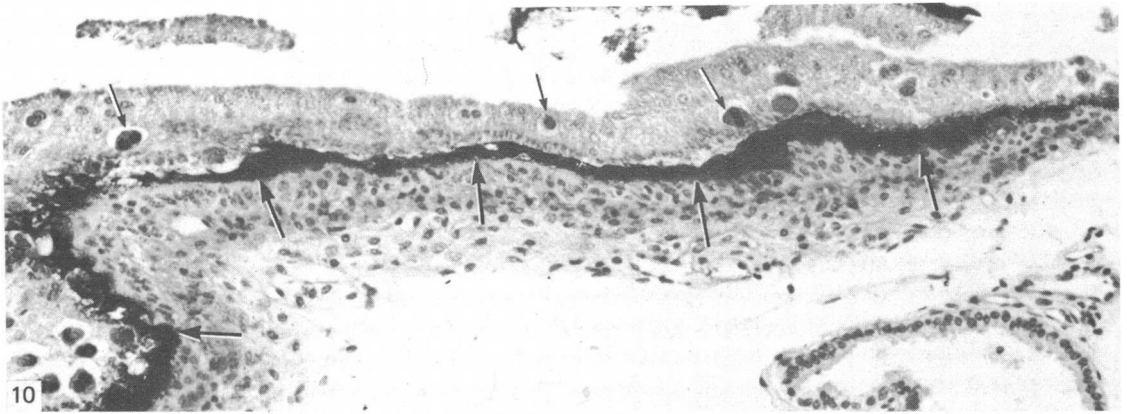
Fig. 11. Section reacted with periodic acid-Schiff. Note that the cytoplasm of some binucleate cells in the chorionic tip is stained intensely (large arrow) and in some the Golgi complex (small arrows) is stained weakly. Day 34 of gestation.  $\times 550$ .

Fig. 12. The same section as in Figure 11 but counterstained with the indirect immunoperoxidase method. Note that the Golgi (small arrows) of the cells which are not visible in Figure 11 are now intensely stained with SBU-3. The Golgi and the cytoplasm of the other cells (large arrows) which do not stain intensely with periodic acid-Schiff are now strongly SBU-3-positive.  $\times 550$ .

Fig. 13. Sections reacted with periodic acid-Schiff. Note that two binucleate cells in the trophoblast are Schiff-positive whereas the giant cell (arrow) in the syncytial layer is very weakly stained in places. Some trophoblastic brush borders (arrowheads) are stained positive. Day 34 of gestation.  $\times 550$ .

Fig. 14. The same section as in Figure 13, but counterstained with the indirect immunoperoxidase method. Note that the binucleate cell (small arrow) and the giant cell (large arrow), weakly stained with periodic acid-Schiff in Figure 13, are now intensely stained with SBU-3. Trophoblastic brush borders weakly Schiff-positive are now intensely stained (arrowheads).  $\times 576$ .





there appeared to be far more SBU-3-positive than Schiff-positive cells in the placentome. The binucleate cells and the amorphous layer between the trophoblast and the uterine epithelium in the interplacentomal areas remained Schiff-positive.

#### DISCUSSION

The present study indicates that the material recognised by the monoclonal antibody SBU-3 is produced by binucleate cells of the trophoblast. These binucleate cells are observed in the earliest material available, at Day 21 of pregnancy, and at this time the reaction product is confined entirely to cells present at the initial sites of attachment to the maternal caruncles. As no other fetal or maternal tissues or extracellular substances were recognised by SBU-3 at this stage of pregnancy it is unlikely that the SBU-3-positive product represents engulfed material. In view of the strict localisation of reaction product to binucleate cells only at the sites of attachment of the trophoblast to the caruncles and its absence in other regions of the trophoblast, it is reasonable to suggest that caruncular tissue may have induced the synthesis of this material.

In recent years, the existence of at least two classes of binucleate cells in the sheep placentome has been reported by some workers. Based on electron microscopical studies, Boshier & Holloway (1977) indicated that one type of binucleate cell is responsible for the synthesis of glycoprotein secretory material and the other for glycogen storage. Using immunofluorescence and immunoperoxidase techniques, Watkins & Reddy (1980) reported that one class of binucleate cell is associated with the production of ovine placental lactogen and the other with the synthesis of another class of biologically active protein or steroid. Recently Wooding (1981) demonstrated ovine placental lactogen immunoreactivity to be localised exclusively in the binucleate cell granules and Golgi complex region in the fetal chorionic epithelium, in granules of similar size and shape scattered throughout the contiguous syncytial layer of the placentomes. It was further indicated that the binucleate cell and syncytial granules which contained ovine placental lactogen activity may well contain other equally important constituents, because the nature of the material responsible for the strong selective phosphotungstic acid staining of the granules is as yet unknown (Wooding, 1980). The results from this series of studies (Wooding 1980; Wooding *et al.* 1980; Wooding 1981) indicated that there is only one population of binucleate cells. However the present study has revealed that in relatively well established placentomes, the great majority of binucleate cells are SBU-3-positive, while the remainder are only periodic acid-Schiff-positive with a few also doubly stained (i.e. SBU-3- and Schiff-positive). The doubly stained cells most likely represent those at different transitional stages. Early stages of differentiation of Schiff-positive to SBU-3-positive cells are most likely displayed by those binucleate cells which exhibit a Schiff-positive basal cytoplasmic region and a SBU-3-positive Golgi complex. Binucleate cells with a combination of a Schiff- and SBU-3-positive basal region and a SBU-3-positive Golgi complex are most likely the next phase of maturation. Alternatively, as the cells are binucleated they may be producing two different products concurrently. It can be concluded that at least two populations of binucleate cells exist but it is not possible to equate these cell populations with those reported by other workers.

Two main theories concerning the origin of the syncytial layer exist. Assheton (1906) was the first to suggest that the syncytium is formed by migration and fusion

of fetal binucleate cells from the chorionic layer. This was later supported by light microscopical studies (Wimsatt, 1951; Amoroso, 1952), and most recently by electron microscopy (Wooding *et al.* 1980) and autoradiography (Wooding *et al.* 1981). Other groups of workers (Bjorkman, 1965; Boshier & Holloway, 1977; Steven *et al.* 1978) have suggested that the syncytium is formed by fusion of the original uterine epithelial cells. However the present observations are more consistent with the theory advanced by Assheton (1906), since (1) SBU-3-positive binucleate cells are first present in the placentomal trophoblast, (2) a significant number of SBU-3-positive binucleate cells is found throughout pregnancy to be located apparently at the interface of the trophoblast and the syncytial layer, (3) SBU-3-positive syncytium appears after the appearance of SBU-3-positive binucleate cells, (4) the specificity of the monoclonal antibody reaction suggests that the same product is found in both binucleate cells and syncytia, (5) double staining is seen in the cytoplasm of both the trophoblastic binucleate cells and the syncytium and (6) mitotic figures are frequently seen in the trophoblast but not in the syncytial layers. As suggested by Wooding (1980), if the syncytium originates by fusion of the maternal uterine epithelial cells at implantation, then the subsequent enormous increase in area would require a large number of nuclear divisions to maintain the observed nuclear distribution in the syncytium. Thus the evidence of frequent migration of binucleate cells to the caruncular epithelium and the fact that they stain positively for SBU-3 are further indications that the one is derived from the other by fusion. Moreover, recent work has indicated that all known syncytia form by fusion and not by mitotic division (Chambers, 1978).

Though the SBU-3-positive substance has not been fully characterised biochemically, it is believed that it is not ovine placental lactogen, a substance with which it does not share any biochemical characteristics. For example the molecular weight of ovine placental lactogen is 22000 daltons (Chan, Robertson & Friesen, 1976) whereas that of the SBU-3-positive substance is approximately 60000 daltons, using reduced SDS-polyacrylamide gel electrophoresis (Gogolin-Ewens, Lee, Moseby & Brandon, unpublished). Nor is the SBU-3-positive antigen identical with alkaline phosphatase since comparison of sections stained with the monoclonal antibody with those stained specifically for alkaline phosphatase indicates different staining patterns. For example, the endometrial glands and the uterine epithelium stain strongly for alkaline phosphatase but are negative for SBU-3.

Since the appearance of the protein recognised by SBU-3 in the binucleate cells is coincident with implantation, it is possible the substance may play a role in implantation. Experimental work is in progress to investigate the possibility that the SBU-3-positive material could be involved in preventing maternal rejection of the fetus during gestation.

#### SUMMARY

The distribution of cells recognised by the monoclonal antibody SBU-3 raised against trophoblast microvilli during development of the sheep placenta was investigated using the indirect immunoperoxidase technique. At 21 days of gestation, the placental antigen recognised by the monoclonal antibody SBU-3 was observed in the binucleate cells in the trophoblast located in close apposition to the caruncular epithelium. From 30–100 days there was a dramatic increase in the number of SBU-3-positive cells in the placentomal trophoblast and the syncytial layer in the placentome. An insignificant number of SBU-3-positive cells was observed in the

interplacentomal trophoblast. By 120–145 days, the syncytial layer became less intensely stained, but strongly SBU-3-positive binucleate cells were still present in the placentomal trophoblast.

It is concluded that the antigen recognised by the monoclonal antibody SBU-3 is a secretory product of the binucleate cells of the trophoblast, whose function is at present unknown. The findings in this study are consistent with the theory that the syncytium is formed by fusion of migrating fetal binucleate cells.

This work was initially supported by the Lalor Foundation and is now supported by the Australian Research Grants Scheme. The excellent technical assistance of Messrs P. Smith and R. Bothof is gratefully acknowledged.

#### REFERENCES

- AMOROSO, E. C. (1952). Placentation. In *Marshall's Physiology of Reproduction*, 3rd ed., vol. 2, (ed. A. S. Parkes), pp. 127–311. London: Longmans Green.
- ASSHETON, R. (1906). The morphology of the ungulate placenta, particularly the development of that organ in the sheep, and notes upon the placenta in the elephant and hyrax. *Philosophical Transactions of the Royal Society B* **198**, 143–244.
- BARCROFT, J. (1952). Foetal respiration and circulation. In *Marshall's Physiology of Reproduction*, 3rd ed., vol. 2, (ed. A. S. Parkes), pp. 399–441. London: Longmans Green.
- BJORKMAN, N. (1965). Fine structure of the ovine placentome. *Journal of Anatomy* **99**, 283–297.
- BOSHIER, D. P. (1969). A histological and histochemical examination of implantation and early placentome formation in the sheep. *Journal of Reproduction and Fertility* **19**, 51–61.
- BOSHIER, D. P. & HOLLOWAY, H. (1977). The sheep trophoblast and placental function, an ultrastructural study. *Journal of Anatomy* **124**, 287–298.
- BRYDEN, M. M., EVANS, H. E. & BINNS, W. (1972). Embryology of the sheep. I. Extraembryonic membranes and the development of body form. *Journal of Morphology* **138**, 169–186.
- CULLING, C. F. A. (1957). *Handbook of Histopathological Techniques*. London: Butterworth & Co. Ltd.
- CHAMBERS, T. J. (1978). Multinucleate giant cells. *Journal of Pathology* **126**, 125–148.
- CHAN, J. S. D., ROBERTSON, H. A. & FRIESEN, H. G. (1976). The purification and characterization of ovine placental lactogen. *Endocrinology* **98**, 65–76.
- GALFRE, G., HOWE, S., MILSTEIN, C., BUTCHER, C. W. & HOWARD, J. C. (1977). Antibodies to major histocompatibility antigens produced by hybrid cell lines. *Nature* **266**, 550–552.
- MARTAL, J., DJIANE, J. & DUBOIS, M. P. (1977). Immunofluorescent localisation of ovine placental lactogen. *Cell and Tissue Research* **184**, 427–433.
- REDDY, S. & WATKINS, W. B. (1978). Immunofluorescent localization of ovine placental lactogen. *Journal of Reproduction and Fertility* **52**, 173–174.
- SAINTE-MARIE, G. (1962). A paraffin embedding technique for studies employing immunofluorescence. *Journal of Histochemistry and Cytochemistry* **10**, 250–256.
- SMITH, N. C. & BRUSH, M. G. (1978). Preparation and characterization of human syncytiotrophoblast plasma membrane. *Medical Biology* **56**, 272–276.
- STEVEN, D. H., BASS, F., JANSEN, C. J. M., KRANE, E. J., MALLON, K., SAMUAL, C. A., THOMAS, A. L. & NATHANIELSZ, P. W. (1978). Ultrastructural changes in the placenta of the ewe after fetal pituitary stalk section. *Quarterly Journal of Experimental Physiology* **63**, 221–231.
- WATKINS, W. B. & REDDY, S. (1980). Ovine placental lactogen in the cotyledonary and intercotyledonary placenta of the ewe. *Journal of Reproduction and Fertility* **58**, 411–414.
- WIMSATT, W. A. (1951). Observations on the morphogenesis, cytochemistry and significance of the binucleate giant cells of the placenta of ruminants. *American Journal of Anatomy* **89**, 233–253.
- WOODING, F. B. P. (1980). Electron microscopic localization of binucleate cells in the sheep placenta using phosphotungstic acid. *Biology of Reproduction* **22**, 357–365.
- WOODING, F. B. P. (1981). Localization of ovine placental lactogen in sheep placentomes by electron microscope immunocytochemistry. *Journal of Reproduction and Fertility* **62**, 15–19.
- WOODING, F. B. P., CHAMBERS, S. G., PERRY, J. S., GEORGE, M. & HEAP, R. B. (1980). Migration of binucleate cells in the sheep placenta during normal pregnancy. *Anatomy and Embryology* **158**, 361–370.
- WOODING, F. B. P., FLINT, A. P. F., HEAP, R. B. & HOBBS, T. (1981). Autoradiographic evidence for migration and fusion of cells in the sheep placenta: resolution of a problem in placental classification. *Cell Biology International Reports* **5**, 821–827.