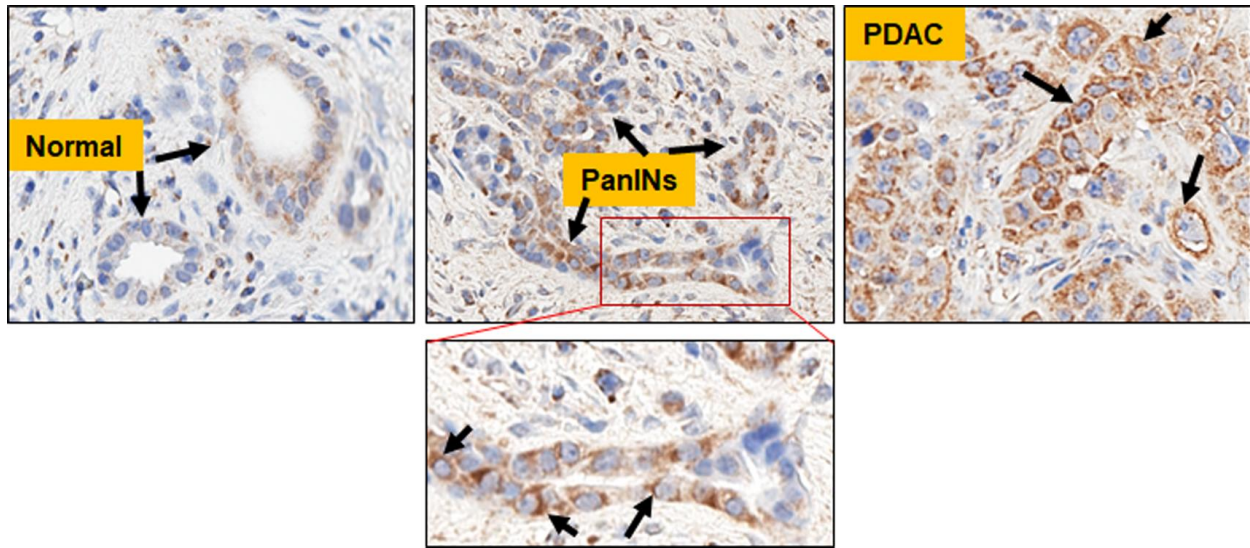


### Supplementary figure 1



### Supplementary figure 1. Localization of TOMM22 expression in disease progression.

TOMM22 expression in matched normal, pancreatic intraepithelial neoplasia (PanIN) lesion and pancreatic adenocarcinoma (PDAC) tissue from a patient. Black arrows in the inset of PanIN lesion and PDAC tumor confirm cytoplasmic localization of TOMM22. Image magnification X 400.