

## The functional morphology of the accessory interosseous muscle in the gibbon hand: determination of locomotor and manipulatory compromises

RANDALL L. SUSMAN, WILLIAM L. JUNGERS  
AND JACK T. STERN, JR

*Department of Anatomical Sciences, Health Sciences Center,  
State University of New York at Stony Brook,  
Long Island, New York 11794*

(Accepted 23 January 1981)

### INTRODUCTION

The hylobatid apes, gibbon and siamang, are notable among mammals for their brachiating habits and morphological adaptations to arboreal life. The positional behaviour of the gibbon includes not only brachiation but also a significant amount of arboreal bipedalism, climbing and suspensory postural activity (Carpenter, 1964; Chivers, 1974; Ellefson, 1974; Fleagle, 1976). Not unexpectedly, the appendages of gibbons and siamang display a number of unique morphological specializations for these postures and locomotion including limb and trunk proportions (Schultz, 1937), a specialized thumb (Forster, 1933; Jouffroy & Lessertisseur, 1960), a highly modified wrist (Lewis, 1969, 1972, 1974; Etter, 1974; Jenkins & Fleagle, 1976), and long curved fingers (Mollison, 1910; Midlo, 1934; Schultz, 1956; Etter, 1974). A myological specialization peculiar to hylobatid apes is the elaboration of the *Mm. flexores breves*, as first reported by Huxley (1871), who noted what he considered to be an additional intrinsic muscle of the gibbon index finger which he named the 'abductor tertii internodii secundi digiti'. Various subsequent descriptions of the muscle indicate some confusion over its insertion and differences of opinion about its action, both being reflected in nomenclatural suggestions. While Keith (1894; p. 299) called this muscle the extensor tertii internodii indicis, Forster (1916) termed it the interosseus volaris radialis longus, and Fitzwilliams (1910) called it *M. accessorius interosseus*. We will employ the latter name.

While earlier workers implied that the function of *M. accessorius interosseus* is abduction and/or extension of the index finger, including both of its interphalangeal joints, some others have suggested that the distalward migration of its insertion, to the extensor assembly at or distal to the first interphalangeal joint (Fig. 1), indicates a change in it from an *extensor* to a *flexor* of this joint (Fitzwilliams, 1910; Tuttle, 1969, 1972). Fitzwilliams (1910; p. 211) stated that in gibbons, "The use to which this hook-like (upper) extremity is put calls for great strengthening of the muscles which produce flexion of the fingers. Flexion is needed not only at the metacarpophalangeal joints, but also at the proximal interphalangeal articulations, so as to complete the hook-like attitude." Tuttle (1969, 1972) also suggested that while the pennate portion of the first dorsal interosseous muscle acts as a flexor of the metacarpophalangeal joint, the 'musculus accessorius' may act as a flexor of the proximal interphalangeal joint.

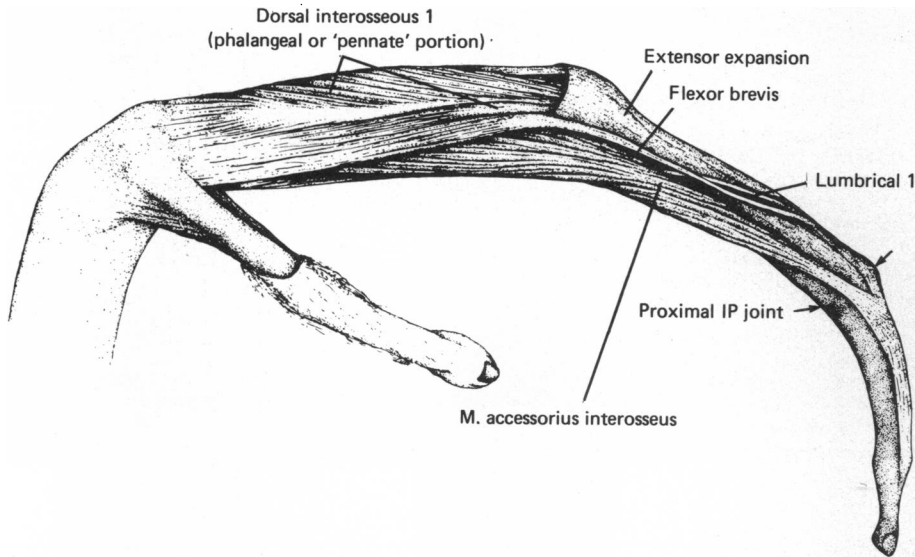


Fig. 1. Radial view of the index finger of *Symphalangus syndactylus* (left hand). The *M. accessorius interosseus* is a distally displaced portion of the *M. flexor brevis*. Its insertion has migrated distally to insert into the extensor expansion distal to the proximal interphalangeal (IP) joint. What remains of the flexor brevis is relatively small compared to the *M. accessorius interosseus*, and its insertion resembles that of other primates. The first dorsal interosseous muscle proper inserts into the base of proximal phalanx II. The arrows indicate the position of the proximal interphalangeal (IP) joint.

Upon dissection it appeared to us that the distal migration of the belly of *M. accessorius interosseus* and of its insertion into the extensor assembly was indeed complex and unique in hylobatids. However, the large number of potential actions of such a muscle renders explanation of the function of *M. accessorius interosseus* highly speculative and for this reason we decided to investigate the pattern of its usage by telemetered electromyography (EMG).

#### MATERIALS AND METHODS

The experimental method used to study muscle activity was telemetered EMG (Stern, Wells, Vangor & Fleagle, 1977), the advantage of this being that the subject animal is not fettered to the recording apparatus by wires or cables. Rather, the modulated 4-channel (4-muscle) EMG signal is sent by a miniature transmitter to an FM receiver. To verify electrode placement into the desired portion of the focal muscle, a 200–500  $\mu$ A stimulating current of brief duration was passed through the 50  $\mu$ m bipolar wire electrodes in each of the four muscles (Susman & Stern, 1979). Proper placement was verified by the movements elicited or by the palpable tension that was produced. Six experiments on the *M. accessorius interosseus* were conducted, each of which included a combination of extrinsic and intrinsic hand muscles (Table 1).

The subjects were a male and a female adult white-handed gibbon (*Hylobates lar*) which exhibited the normal range of gibbon locomotor and manipulatory behaviour (Carpenter, 1964; Ellefson, 1974; Chivers, 1974; Lorenz, 1974; Fleagle, 1976). They were housed in a large enclosure containing a vertical tree trunk (3.7 m  $\times$  8.5 cm),

Table 1. *Experimental subjects and muscles tested*

Experiment 1 ♀	Experiment 2 ♂	Experiment 3 ♀
Musculus accessorius interosseus 1	Musculus accessorius interosseus 1	Musculus accessorius interosseus 1
Dorsal interosseus (pennate portion) 1	Dorsal interosseus (pennate portion) 1	Dorsal interosseus (pennate portion) 1
Dorsal interosseus (pennate portion) 2	Flexor digitorum profundus II	Flexor digitorum profundus (II and V)
Flexor digitorum profundus - III (II)*	Extensor digitorum communis II	Flexor digitorum superficialis II
Lumbrical 1		
Experiment 4 ♂	Experiment 5 ♂	Experiment 6 ♂
Musculus accessorius interosseus	Musculus accessorius interosseus	Musculus accessorius interosseus
Lumbrical 1	Dorsal interosseus (pennate portion)	Dorsal interosseus (pennate portion)
Flexor digitorum profundus II	Flexor digitorum superficialis II	Flexor digitorum profundus II (I, III-V)†
Extensor digitorum communis II-V	Extensor digitorum communis II > III > IV > V†	Flexor digitorum superficialis II

\* Stimulation elicited a response primarily in digit III but also in ray II.

† Stimulation provided a graded contraction most evident in ray II; least evident in ray V.

‡ Stimulation mostly effected ray II but the thumb and other fingers also responded. The implication of the thumb reflects the presence of a tendinous shunt that joins the second fasciculus of flexor digitorum profundus with the 'flexor pollicis longus' in gibbons (Tuttle, 1969).

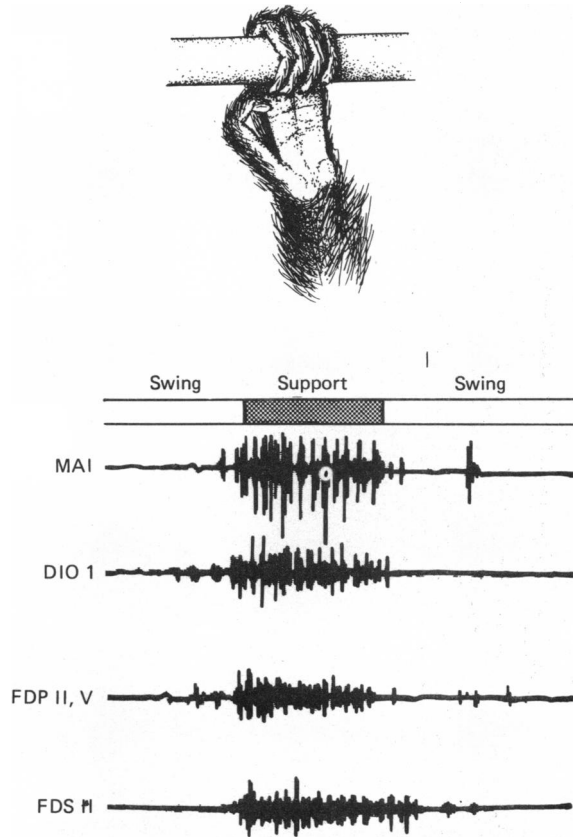


Fig. 2. Electromyographic recordings of accessory interosseus muscle (MAI), first dorsal interosseus (pennate, phalangeal position) (DIO 1), flexor digitorum profundus (FDP II, V), and flexor digitorum superficialis (FDS II), during brachiation along the overhead ladder. Onset of muscle activity is evident just prior to and during grasp. The activity observed in *M. accessorius interosseus* serves to help flex the metacarpophalangeal joint of the index finger during whole-hand grasp (Figs. 2-4 taken from experiment 3, see Table 1).

a vertical wooden pole (2.7 m in length, 2.8 cm in diameter), a horizontal overhead ladder (7.3 m in length with dowel rungs 2.8 cm in diameter and spaced 40 cm apart), and a smooth concrete floor covered with wood shavings. The animals also frequently used the cage wire (5.7 cm mesh) for support.

## RESULTS

### *Morphology of M. accessorius interosseus*

Anatomical observations on the *M. accessorius interosseus* were made in two specimens of the gibbon (*H. lar*) and two specimens of the siamang (*Symphalangus syndactylus*). In each of the specimens, a true distally migrated and hypertrophied *M. accessorius interosseus* was found only on the radial side of the index finger. Its origin was located more distally on the palmar surface of the second metacarpal bone than was the origin of the radial *M. flexor brevis* of other Hominoidea. It ended in a tendon which inserted into the extensor expansion at, or just distal to, the proximal

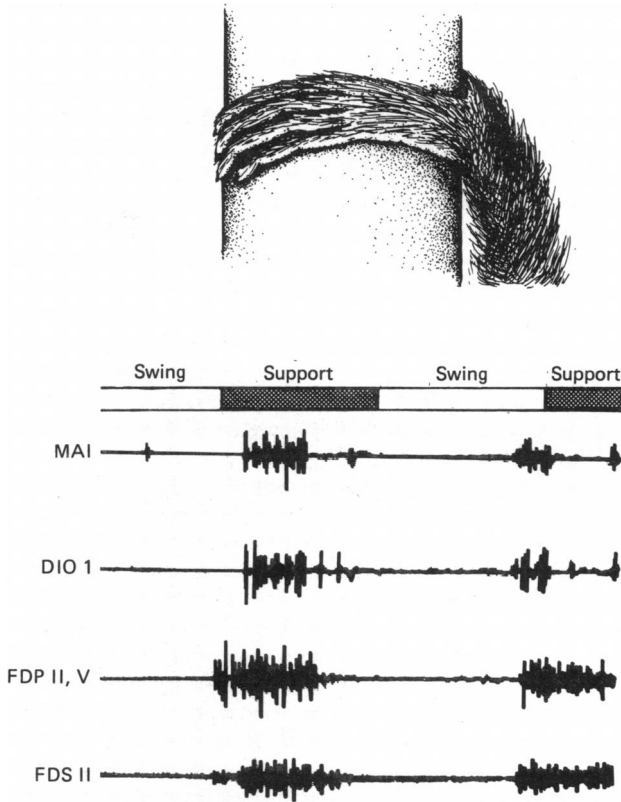


Fig. 3. Electromyographic recordings of the same muscles as in Fig. 2 during climbing of the vertical trunk. Note the moderate activity in *M. accessorius interosseus* as a result of the slight flexion of the metacarpophalangeal joints.

interphalangeal joint and passed sufficiently close to the axis of rotation to obscure its potential role in flexion of that joint. When the finger was fully extended, the tendon possessed a poor mechanical advantage for flexion at the proximal interphalangeal joint. Its moment was somewhat increased, however, when the index finger went into flexion. There was no doubt that the insertion of the *M. accessorius interosseus* in gibbons and siamang was such that it was no longer in a position to act as an extensor of the proximal interphalangeal joint.

#### *EMG during locomotion and postures*

The largest EMG potentials recorded in *M. accessorius interosseus* during locomotion occurred during brachiation along the overhead ladder. Upon grasping the ladder rung during brachiation, the fingers were usually flexed at all joints, and slight to moderate activity was noted in the muscle in both subjects (Fig. 2). By contrast, in swinging beneath the wire mesh cage top, the normal hand posture involved interphalangeal flexion with metacarpophalangeal joint extension, and there was at most only slight activity in the muscle. In suspensory postures, whether hanging from the ladder rung or cage top, the muscle was most often silent, but in a few cases (involving the female subject) slight activity was recorded in it. During all suspensory postures the interphalangeal joints were flexed, but the metacarpophalangeal joints were often extended.

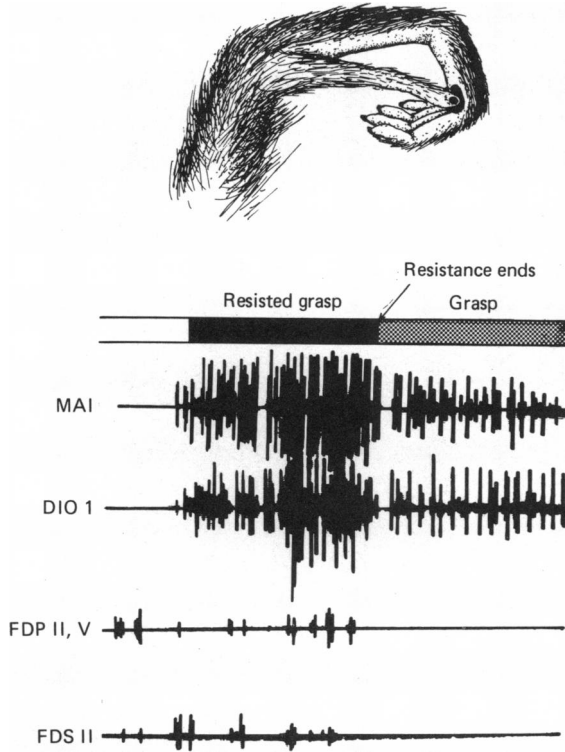


Fig. 4. Electromyographic recordings of the same muscles as in Figs. 2 and 3 during the 'pinch' grasp and hold of a raisin between thumb and index fingers. The level of activity in *M. accessorius interosseus* during the resisted portion of the grasp is the maximum observed in the experiment. Note the decrease in the level of activity in this muscle and in part of the first dorsal interosseous muscle as the hold on the raisin is released. Note also the relative quietude of the extrinsic finger flexors during manipulation.

In climbing the vertical trunk, *M. accessorius interosseus* exhibited nil to slight potentials during the support phase (Fig. 3). Similar low levels were elicited in climbing the thinner vertical pole. Stationary clinging to both vertical supports, usually involving all four cheiridia, elicited activity from the muscle in the female subject on only one occasion, and in this case only low level activity was recorded.

*EMG during manipulation*

The subjects were offered raisins (10 mm diameter average) either (unresisted) from a flat, opened hand or (resisted) while tightly held. When the item was grasped, the thumb was usually adducted and flexed against the radial side of the index finger. Small food items such as raisins were often positioned into the crease of the first interphalangeal joint and held there with pressure from the tip of the pollex. Variation in placement of the food item was significant, and this variation was greater in the left than in the right hands of both subjects. Larger objects, such as fresh peaches (60 mm diameter average), were held by the whole hand, but, unlike, that which occurs in humans, the thumb opposed only the side of the index finger. In both resisted and unresisted grasping, the activity elicited in *M. accessorius interosseus* (Fig. 4) exceeded that observed in locomotor activities.

Once a purchase was gained on the food item (raisin) or it was 'plucked' from

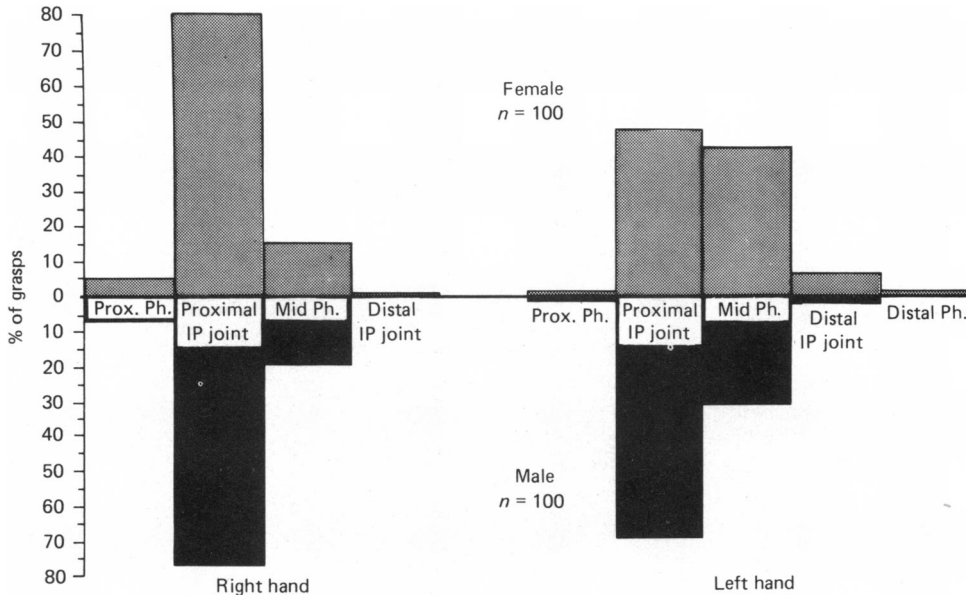


Fig. 5. Columns indicate the relative frequency with which raisins are grasped between the thumb and different points along the radial side of the index finger. Stippled columns (above) represent grasp by the female subject and dark columns (below) indicate episodes recorded for the male subject. The preferred position for grasping small objects is between the thumb and side of the index finger *at the level of the proximal interphalangeal joint* (both subjects). It is interesting to note the greater variation in placement when the left hand is used (both subjects).

the investigator's grasp, the level of activity of *M. accessorius interosseus* diminished (Fig. 5). Often during unresisted holding of the object, prior to placing it in the mouth, the muscle was silent.

#### DISCUSSION

There is little doubt that the *M. accessorius interosseus* is derived from the flexor brevis muscle on the radial side of the index finger\* (Kohlbrügge, 1890; Fitzwilliams, 1910; Forster, 1916). In the hylobatid apes the *M. accessorius interosseus* splits off from the flexor brevis muscle proper, the latter retaining the configuration normal for other primates but greatly reduced in size (Fig. 1). In the gibbon and siamang, the *M. accessorius interosseus* was far greater in size than what remains of the flexor brevis muscle on the radial side of the index finger. The statements by Huxley (1871) and Fitzwilliams (1910) that the accessory interosseous muscle inserted on the pulp of the index finger could not be verified. The finding of Kohlbrügge (1890) that gibbons and siamang differ in the insertion of *M. accessorius interosseus* was not confirmed by our dissections. Kohlbrügge observed that the insertion reached the distal phalanx of ray II in gibbons but reached only as far as the end of the middle phalanx II in siamang (Kohlbrügge, 1890; pp. 258–9).

The results of our EMG study reveal that the *M. accessorius interosseus* of ray II in the lesser apes functions chiefly as an *abductor* of the index finger during the pinch grasp of small objects while it also serves in a secondary role (similar to that of its homologue and counterpart in other apes and humans) to help *flex* the metacarpophalangeal joint during whole hand grasping. This resembles the flexores

\* We refrain from referring to these muscles by number because of the controversy over homologies and the naming of the first flexor brevis.

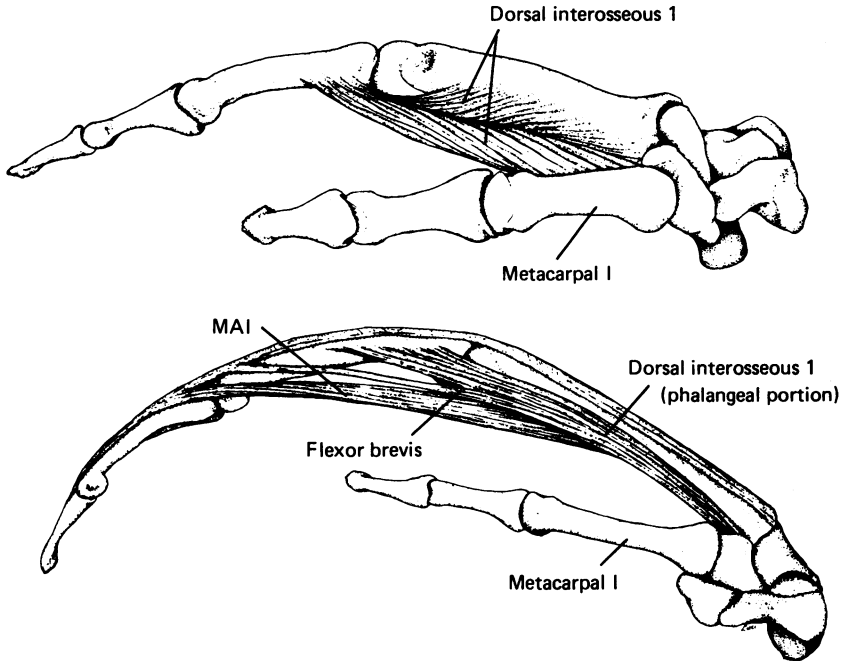


Fig. 6. Radial view of the right hands of a human (above) and a gibbon, *Hylobates lar* (below) to demonstrate the lack of a first metacarpal origin of dorsal interosseous 1 in the latter species. In humans and other primates, the first dorsal interosseous retains an extensive origin from the shaft of metacarpal I. This feature has been lost in gibbons and siamang.

breves and pennate portions of the dorsal interosseous muscles in chimpanzees (Susman & Stern, 1979). The question remains, however, why the hylobatid apes require a *M. accessorius interosseus* for thumb-index pinch grasping while other primates, and especially humans (which display the most prominent thumb-index activity), do not.

Inspection of the form and observation of the use of the hand in captive and free ranging gibbon and siamang provide a possible answer, in the existence of the deep cleft, or separation of the first and second rays, which is unique to lesser apes. This cleft has its morphological basis in the absence of a pollical origin of the first dorsal interosseous muscle (pennate portion) and in the reduction and obliquity of the transverse head of the *M. adductor pollicis*. This enables gibbons and siamang to grasp powerfully vertical supports of larger diameter than would otherwise be possible (Napier & Napier, 1967; Van Horn, 1972). This advantage is highly significant for animals whose locomotor repertoire consists of frequent vertical climbing in the wild (Carpenter, 1964; Chivers, 1974; Lorenz, 1974; Ellefson, 1974), and especially when foraging for food (Fleagle, 1976). However, this enhanced capability in power grasping has concomitantly reduced a significant portion of the first interosseous muscle (Fig. 6), the only muscle that provides resistance to the thumb in pinch grasping.

Field observations (Carpenter, 1964; Chivers, 1974) and those we have made in the laboratory (see also Lorenz, 1974) show that gibbons normally grasp small objects between the pulp of the thumb and the radial side of the index finger (Fig. 4). The plucking and grasping of foods such as leaves, fruit and insects are very impor-



tant aspects of feeding behaviour in free ranging gibbons and siamang (Carpenter, 1964; Ellefson, 1974; Chivers, 1974, 1977), and it is only reasonable to expect that concomitant morphological adaptations might obtain to maintain skill in such activities when other selective forces operate in a different direction. Our EMG data indicate that the *M. accessorius interosseus* assumes much of the role of abduction that would normally fall to that moiety of the first dorsal interosseous muscle which arises from the first metacarpal bone; although it is actually homologous with (and derived from) the flexor brevis muscle, it compensates for the inadequacy of the first dorsal interosseous muscle. In addition, the mid-phalangeal insertion of the *M. accessorius interosseus* transfers its action away from that of an extensor of the first interphalangeal joint to a perhaps more or less neutral role at that joint. The shift away from proximal interphalangeal joint extension, which is an action of the flexor brevis in other primates (Boivin, Wadsworth, Landsmeer & Long, 1969; Susman & Stern, 1979), would facilitate the acute flexed-finger grasping posture of gibbon and siamang.

This study demonstrates that while the demands for suspensory postures and locomotion have had a profound effect on gibbon anatomy, bias from a single set of behaviours must be avoided in attempts to find functional explanations for that anatomy. In the case of the evolution of the *M. accessorius interosseus*, a complex interplay between selective agents occurred. While there would arise no need for such a muscle if hylobatids had not undergone morphological adaptation to vertical climbing, the more immediate selective forces are those determined by object manipulation.

#### SUMMARY

The evidence for two functional roles of *M. accessorius interosseus* can be adduced as follows: (1) abduction of the whole finger is clearly required to resist the force of the thumb against the index during pinch grasp (Fig. 4) and when greater resistance is applied to the food, activity increases in the muscle. (2) The muscle also flexes the metacarpophalangeal joint at the onset of grasp on the ladder rung. In hanging from the finger tips or from the cage top, with the metacarpophalangeal joints extended, the muscle goes silent.

From the functional point of view, the name given by Huxley (1871) to the *M. accessorius interosseus* ('abductor tertii internodii secundi digiti') is perhaps the most appropriate one. For reasons of economy, however, we favour continued use of the nomen *Musculus accessorius interosseus* (Fitzwilliams, 1910) or accessory interosseous muscle. The name coined by Keith (1894; p. 299) which implies that this muscle is an extensor of the distal interphalangeal joint, and any suggestions that the muscle functions primarily to flex the proximal interphalangeal joint are less appropriate or in error. The EMG data reveal that the *M. accessorius interosseus* is primarily an abductor of the index finger in gibbons, and we suggest that it is a unique feature of lesser apes that has evolved in compensation for a deep thumb-index cleft and the loss of the radial moiety of the first dorsal interosseous muscle. The primary role of this specialized muscle is in thumb-index *pinch* grasping.

We are grateful to William Konstant and William Korosh for the training of the subject animals, to Lucille Betti for the preparation of the illustrations, and to Joan Kelly for typing the manuscript. Dr Patricia Freeman of the Field Museum of Natural History and Dr Richard Thorington of the U.S. National Museum generously provided specimens for dissection. Dr John Fleagle and Dr Alfred Rosen-

berger offered helpful comments on the manuscript. Our work is supported by NSF grant BNS 7924070, and by N.I.H. grant RR00165 to Yerkes Regional Primate Research Center.

## REFERENCES

- BOIVIN, G., WADSWORTH, G. E., LANDSMEER, J. M. F. & LONG, C. (1969). Electromyographic kinesiology of the hand: muscles driving the long finger. *Archives of Physical Medicine and Rehabilitation* **50**, 17–26.
- CARPENTER, C. R. (1964). A field study in Siam of the behaviour and social relations of the gibbon. In *Naturalistic Behavior of Nonhuman Primates* (ed. C. R. Carpenter), pp. 145–271. Pennsylvania: Pennsylvania State University Press.
- CHIVERS, D. J. (1974). The siamang in Malaya. A field study of a primate in a tropical rain forest. *Contributions to Primatology* **4**, 1–334.
- CHIVERS, D. J. (1977). The feeding behaviour of siamang (*Symphalangus syndactylus*). In *Primate Ecology: Studies of Feeding and Ranging Behaviour in Lemurs, Monkeys and Apes* (ed. T. H. Clutton-Brock), pp. 355–382. London: Academic Press.
- ELLEFSON, J. O. (1974). A natural history of white-handed gibbons in the Malayan Peninsula. In *Gibbon and Siamang* (ed. D. M. Rumbaugh), Vol. 3, pp. 1–136. Basel: S. Karger.
- ETTER, H. E. F. (1974). Morphologisch- und metrisch-vergleichende Untersuchung am Handskelet rezenter Primaten, Teil III. *Gegenbaurs Morphologisches Jahrbuch* **120**, 299–322.
- FITZWILLIAMS, D. C. L. (1910). The short muscles of the hand of the agile gibbon (*Hylobates agilis*) with comments on the morphological position and function of the short muscles of the hand of man. *Proceedings of the Royal Society of Edinburgh* **30**, 202–218.
- FLEAGLE, J. G. (1976). Locomotion and posture of the Malayan siamang and implications for hominoid evolution. *Folia primatologica* **26**, 245–269.
- FORSTER, A. (1916). Die Mm. contrahentes und interossei manus in der Säugetierreihe und beim Menschen. *Archiv für Anatomie und Physiologie* 101–378.
- FORSTER, A. (1933). Contribution à l'évolution du pouce chez *Hylobates Leuciscus*. *Archives d'anatomie, d'histologie et d'embryologie* **16**, 215–230.
- HUXLEY, T. H. (1871). *The Anatomy of Vertebrated Animals*. London: J. & A. Churchill.
- JENKINS, F. A. & FLEAGLE, J. G. (1976). Knuckle-walking and the functional anatomy of the wrist in living apes. In *Primate Functional Morphology and Evolution* (ed. R. H. Tuttle), pp. 213–227. The Hague: Mouton.
- JOUFFROY, F. K. & LESSERTISSEUR, J. (1960). Les spécialisations anatomiques de la main chez les singes à progression suspendue. *Mammalia* **24**, 93–151.
- KEITH, A. (1894). *The Myology of the Catarrhini: A Study in Evolution*. Doctoral thesis, University of Aberdeen.
- KOHLBRÜGGE, J. H. F. (1890). *Muskeln und periphere Nerven des Genus Hylobates*. Leiden: E. J. Brill.
- LEWIS, O. J. (1969). The hominoid wrist joint. *American Journal of Physical Anthropology* **30**, 251–267.
- LEWIS, O. J. (1972). Osteological features characterizing the wrists of monkeys and apes, with a reconsideration of this region in *Dryopithecus (Proconsul) africanus*. *American Journal of Physical Anthropology* **36**, 45–58.
- LEWIS, O. J. (1974). The wrist articulations of the anthropoidea. In *Primate Locomotion* (ed. F. A. Jenkins), pp. 143–169. New York: Academic Press.
- LORENZ, R. (1974). On the thumb of the hylobatidae. In *Gibbon and Siamang* (ed. D. M. Rumbaugh), vol. 3, pp. 157–175. Basel: S. Karger.
- MIDLO, C. (1934). Form of hand and foot in primates. *American Journal of Physical Anthropology* **19**, 337–389.
- MOLLISON, T. (1910). Die Körperproportionen der Primaten. *Gegenbaurs Morphologisches Jahrbuch* **42**, 79–299.
- NAPIER, J. R. & NAPIER, P. H. (1967). *Handbook of Living Primates*. New York: Academic Press.
- SCHULTZ, A. H. (1937). Proportions, variability and asymmetries of the long bones of the limbs and the clavicles in man and apes. *Human Biology* **9**, 281–328.
- SCHULTZ, A. H. (1956). Postembryonic age changes. *Primatologia* **1**, 887–964.
- STERN, J. T. Jr., WELLS, J. P., VANGOR, A. K. & FLEAGLE, J. G. (1977). Electromyography of some muscles of the upper limb in *Ateles* and *Lagothrix*. *Yearbook of Physical Anthropology 1976* **20**, 498–507.
- SUSMAN, R. L. & STERN, J. T. Jr (1979). Telemetered electromyography of flexor digitorum profundus and flexor digitorum superficialis in *Pan troglodytes* and implications for interpretation of the O.H. 7 hand. *American Journal of Physical Anthropology* **50**, 565–574.
- TUTTLE, R. H. (1969). Quantitative and functional studies on the hands of the anthropoidea. I. The Hominoidea. *Journal of Morphology* **128**, 309–364.
- TUTTLE, R. H. (1972). Functional and evolutionary biology of hylobatid hands and feet. In *Gibbon and Siamang* (ed. D. M. Rumbaugh), vol. 1, pp. 136–206. Basel: S. Karger.
- VAN HORN, R. N. (1972). Structural adaptations to climbing in the gibbon hand. *American Anthropologist* **74**, 326–334.