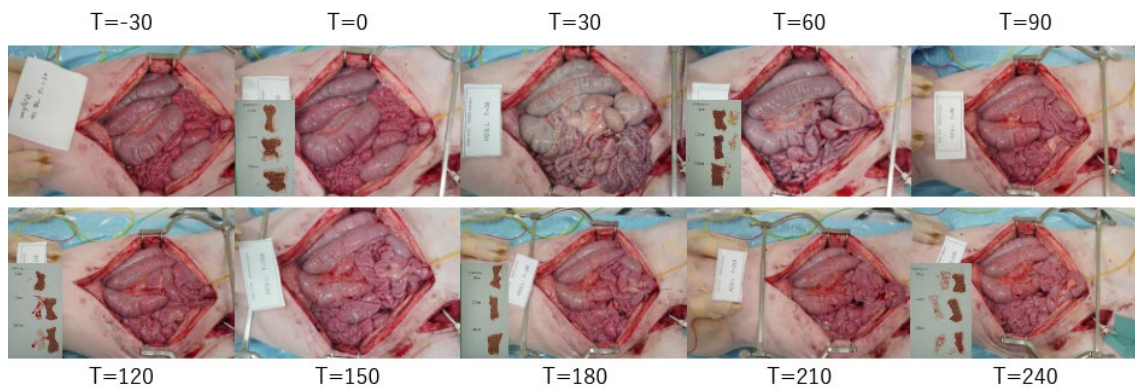


Supplement Figure 4



The gross abdomen findings became pale white during occlusion (T=30, T=60) and recovered after deflation (T=90 to T=240).